



ORIGINAL ARTICLE

Testicular tumours in children: Indications for testis-sparing surgery[☆]



Martha Isabel Romo Muñoz^{a,*}, Vanesa Núñez Cerezo^a, Mariela Dore Reyes^a,
Alejandra Vilanova Sánchez^a, Pilar González-Peramato^b, Pedro López Pereira^c,
María José Martínez Urrutia^c

^a Departamento de Cirugía Pediátrica, Hospital La Paz, Madrid, Spain

^b Departamento de Patología, Hospital La Paz, Madrid, Spain

^c Departamento de Cirugía Pediátrica, Servicio de Urología infantil, Hospital La Paz, Madrid, Spain

Received 1 February 2017; accepted 25 May 2017

Available online 3 April 2018

KEYWORDS

Testicular tumour;
Orchiectomy;
Tumorectomy

Abstract

Introduction and objectives: Although standard surgical treatment of a testicular tumour is orchiectomy, use can be made of testis-sparing surgery in selected cases, based on tumour markers, tumour size, and histopathological findings. Our objective is to become acquainted with the indications of testis-sparing surgery as a treatment for the incidental finding of a palpable and non-palpable testicular mass.

Material and methods: A retrospective study was conducted on 22 patients younger than 18 years diagnosed with a testicular tumour between 2000 and 2014. An assessment was made of the condition, the history, ultrasound, histopathology, tumour markers (BHCG, AFP), therapeutic approach, and outcome.

Results: Of the 22 patients (10 prepubertal age) studied, 82% had palpable mass, and 18% were incidental findings. Two had cryptorchidism. The BHCG was increased in 27% and AFP in 45% of cases. There were 18 tumorectomies and 4 orchiectomies performed. The histopathology found 72% germ cell, 14 orchiectomy, and 2 tumorectomies (2 teratomas), with 27% non-germ cell tumours in 4 orchiectomies and 2 tumorectomies (2 cells of Leydig). Six patients received post-surgical chemotherapy (mixed tumours). The median tumour size was 1 (0.4–1.5) cm in tumorectomies, and 2.5 (0.5–14) cm in orchiectomies. The mean follow-up was 5 (1–15) years. One patient died due to metastatic disease. There was no local recurrence in the follow up of the tumorectomies.

[☆] Please cite this article as: Romo Muñoz MI, Núñez Cerezo V, Dore Reyes M, Vilanova Sánchez A, González-Peramato P, López Pereira P, et al. Tumores testiculares en la edad pediátrica: indicaciones de la cirugía conservadora. An Pediatr (Barc). 2018;88:253–258.

* Corresponding author.

E-mail address: march3x@gmail.com (M.I. Romo Muñoz).

PALABRAS CLAVE

Tumor testicular;
Orquiectomía;
Tumorectomía

Conclusions: A change in the trend of our therapeutic approach is demonstrated. We propose that testis-sparing surgery is indicated in prepubertal patients who meet the benignity criteria of the testicular mass (small size and negative tumour markers).

© 2017 Asociación Española de Pediatría. Published by Elsevier España, S.L.U. All rights reserved.

Tumores testiculares en la edad pediátrica: indicaciones de la cirugía conservadora

Resumen

Introducción y objetivos: El tratamiento quirúrgico estándar del tumor testicular es la orquiectomía, sin embargo, se podría recurrir a la cirugía conservadora en casos seleccionados, basándonos en la edad del paciente, marcadores tumorales, tamaño tumoral y hallazgos histopatológicos. Nuestro objetivo es dar a conocer cuáles son las variables que tener en cuenta para indicar una cirugía conservadora como tratamiento de una masa testicular palpable y no palpable encontrada como hallazgo incidental.

Material y métodos: Estudio retrospectivo en 22 pacientes menores de 18 años, diagnosticados de tumor testicular entre 2000 y 2014. Revisamos el motivo de consulta, antecedentes, ecografía, estudio histopatológico, marcadores tumorales (BHCG, AFP), actitud terapéutica y evolución.

Resultados: De los 22 pacientes (10 prepuberales), el 82% presentaron masa palpable y el 18% fueron hallazgos incidentales. Dos presentaban criptorquidia. La BHCG estaba aumentada en el 27% y la AFP en el 45%. Se realizaron 18 orquiectomías y 4 tumorectomías. La histología fue en un 72% de células germinales, 14 orquiectomías y 2 tumorectomías (2 teratomas); y en un 27% de tumores de células no germinales, en 4 orquiectomías y 2 tumorectomías (2 tumores de células de Leyding). Seis pacientes recibieron quimioterapia postoperatoria (tumores mixtos). La mediana del tamaño de la tumoración fue de un cm (0,4-1,5) en las tumorectomías y de 2,5 cm (0,5-14) en las orquiectomías. El seguimiento fue de 5 años (1-15). Un paciente falleció por enfermedad metastásica. No hubo recidiva local en la evolución de las tumorectomías.

Conclusiones: Ponemos de manifiesto una tendencia al cambio en nuestra actitud terapéutica. Planteamos una cirugía conservadora mediante tumorectomía en los pacientes que cumplan con los criterios de benignidad de la masa testicular (pequeño tamaño y marcadores tumorales negativos).

© 2017 Asociación Española de Pediatría. Publicado por Elsevier España, S.L.U. Todos los derechos reservados.

Introduction

Testicular tumours account for 1–2% of all paediatric solid tumours, with 2 peaks in age of onset: the first one at ages 2–4 years, and the second at around age 15 years.¹ Its incidence in the general population is of 0.5–2 cases per 100,000 inhabitants, with an increase in the adult population in recent years.^{2,3}

Testicular tumours are divided into 6 groups (World Health Organization histological classification of tumours, 2016)⁴: (1) germ-cell tumours derived from germ cell neoplasia in situ (GCNIS) including seminoma, embryonal carcinoma, postpubertal-type yolk sac tumour, trophoblastic tumour and germ cell tumours of unknown type ('burnt-out' tumours); (2) germ cell tumours unrelated to GCNIS, including spermatocytic tumour, prepubertal-type teratoma, prepubertal-type yolk sac tumour and prepubertal-type mixed teratoma and yolk sac tumour; (3) sex-cord-stromal tumours (Leydig cell, Sertoli cell or granulosa cell tumours); (4) tumours containing both germ cell

and sex cord-stromal elements; (5) miscellaneous tumours of the testis and (6) haematolymphoid tumours. This new classification differentiates between 2 types of teratomas (Figs. 1 and 2) and yolk sack tumours: prepubertal type (unrelated to GCNIS) and postpubertal type (derived from GCNIS), with the prognosis being significantly better in the former. There is a clear predominance (90–95%) of germ cell tumours, and prepubertal-type teratomas and yolk sac tumours are the most frequent testicular tumours in children^{5–8} (Fig. 3). Prepubertal-type teratomas are usually cystic and have an organoid arrangement (Fig. 4). This type includes epidermoid cysts, dermoid cysts and well-differentiated neuroendocrine tumours.

Due to the routine use of ultrasound examination, there has been an increase in the detection of cases of nonpalpable testicular masses^{9,10} (Fig. 5).

Radical orchiectomy has been traditionally considered the gold standard of treatment for testicular masses at any age. However, given that these masses are frequently benign in children,^{1,10,11} the medical and surgical approach to their

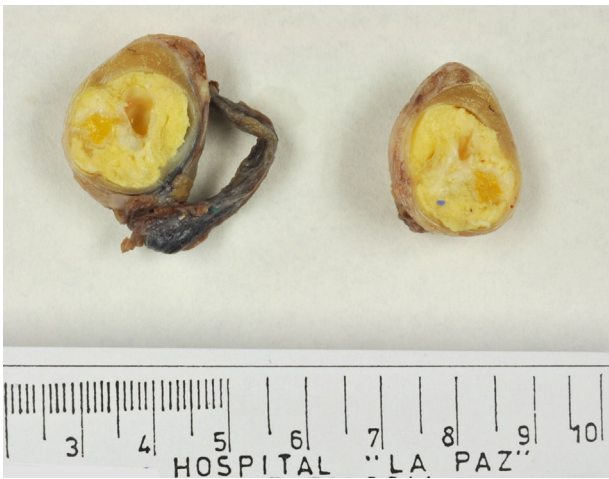

Figure 1 Gross photograph of a prepubertal-type teratoma in the testicle of a boy aged 6 years. The main features are its cystic appearance and yellow homogeneous mass.

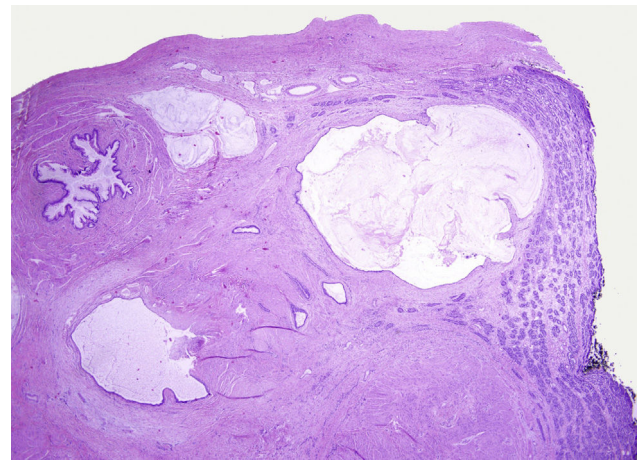


Figure 4 Micrograph of a prepubertal-type teratoma with organoid arrangement. Note the cysts sheathed by glandular mucosal lining and surrounded by smooth muscle. On the side, prepubertal testicular parenchyma without germ cell neoplasia in situ.

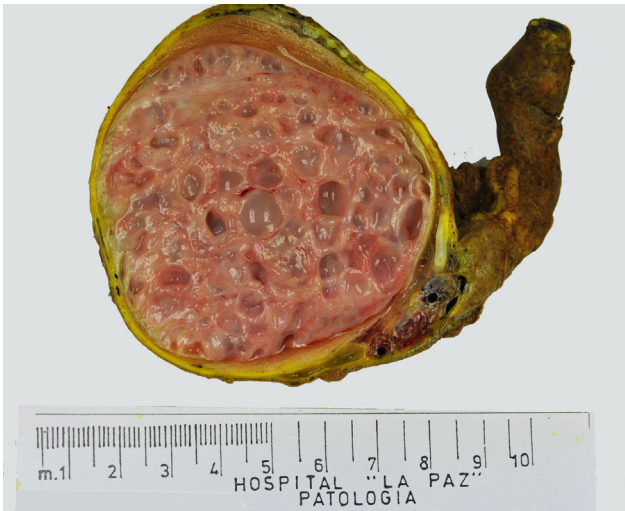

Figure 2 Gross photograph of a postpubertal-type teratoma in a patient aged 16 years. Numerous cysts replace most of the parenchyma.

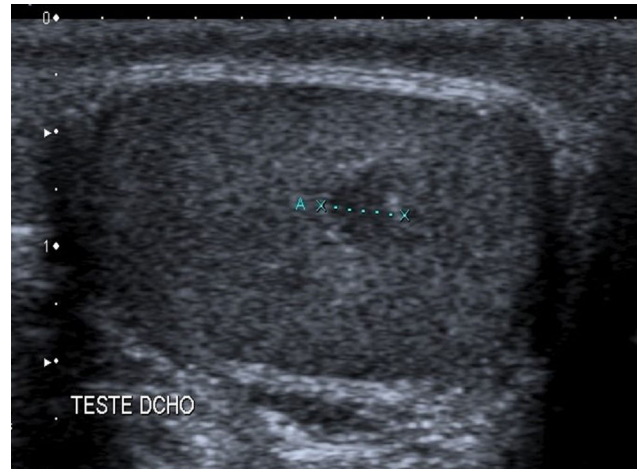


Figure 5 Chance finding on ultrasound of the right testis of a solid nodule 4.5 mm in diameter with hyperechoic edge and changes in echogenicity in the surrounding area.

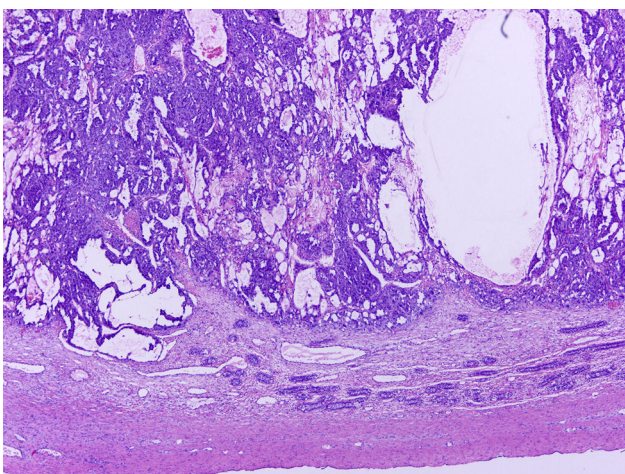


Figure 3 Micrograph of a prepubertal-type pure yolk sac tumour in a boy aged 1 year. Note the macrocystic and microcystic pattern of the yolk sac.

management has been re-evaluated in recent years. This involves a change in the initial treatment approach, with consideration of conservative surgery (tumourectomy)¹¹⁻¹³ based on tumour marker values (beta-hCG, AFP), tumour size and histological findings.¹⁴⁻¹⁹

The decision of performing a conservative tumourectomy must be made jointly by the physicians in charge of the patient (Table 1), and the intervention must be performed in a centre with experience.²

Our objective was to determine the variables that need to be taken into account in the indication of conservative surgery for treatment of palpable and nonpalpable testicular masses found incidentally.

Materials and methods

We conducted a retrospective study of cases of testicular tumours in 22 patients aged less than 18 years diagnosed

Table 1 Summary of clinical cases.

Case	Age (years)	Risk factors	Presentation	Tumour markers (beta-hCG/AFP)	Surgical approach	Tumour size (cm)	Histology
1	18		Enlargement	N/P	Orchiectomy	2.7	Mixed germ cell
2	15		Enlargement	P/P	Orchiectomy	14	Mixed germ cell
3	16		Enlargement	P/N	Orchiectomy	2.5	Mixed germ cell
4	0.16		Enlargement	x/P	Orchiectomy	1	Granulosa cell
5	2		Enlargement	N/P	Orchiectomy	2.5	Yolk sac
6	16		Enlargement	P/P	Orchiectomy	3.5	Mixed germ cell
7	12		Ultrasound finding	N/N	Tumourectomy	1	Leydig cell
8	0.83		Enlargement	N/N	Tumourectomy	1.5	Prepubertal-type teratoma
9	6		Enlargement	P/P	Orchiectomy	4.5	Mixed germ cell
10	14		Enlargement	x/N	Orchiectomy	1.5	Prepubertal-type teratoma
11	16		Enlargement	N/N	Orchiectomy	6.5	Prepubertal-type teratoma
12	6		Ultrasound finding	N/N	Orchiectomy	1.5	Prepubertal-type teratoma
13	11	Cryptorchidism	Ultrasound finding	N/N	Tumourectomy	0.4	Leydig cell
14	12		Enlargement	N/N	Orchiectomy	0.5	Non-Hodgkin lymphoma
15	0.91		Enlargement	N/P	Orchiectomy	1.5	Yolk sac
16	18		Enlargement	P/N	Orchiectomy	4	Mixed germ cell
17	16		Enlargement	N/P	Orchiectomy	2.4	Postpubertal-type teratoma + GCNIS
18	2		Enlargement	N/N	Orchiectomy	1.5	Prepubertal-type teratoma
19	13		Enlargement	N/N	Tumourectomy	1.5	Teratoma
20	10		Enlargement	P/P	Orchiectomy	9	Mixed germ cell
21	12	Cryptorchidism	Surgical pathology	x/x	Orchiectomy	5	Sertoli
22	0.25		Enlargement	x/P	Orchiectomy	3	Granulosa cell

GCNIS, germ cell neoplasia in situ; N, negative; P, positive; X, not measured.

and managed in our hospital between 2000 and 2014. We excluded cases in patients with gonadal dysgenesis, as they require a different treatment and followup. We analysed the age at diagnosis, clinical presentation, ultrasound findings, histopathological findings, tumour marker values (beta-hCG, AFP), therapeutic approach (orchiectomy vs tumourectomy) and followup, which was performed as needed in the urology and oncology clinics.

Results

The mean age of the 22 patients was 9.6 years (range, 2 months-18 years), 10 cases were diagnosed prepubertally. As for the clinical presentation, a palpable mass was the most frequent finding, in 18 (82%) of cases, 2 of which were diagnosed in the context of a routine paediatric checkup. In 4 cases (18%), the diagnosis resulted from an incidental

finding, 3 of ultrasound examinations ordered for evaluation of short stature, orchiodynia and contralateral cryptorchidism, and 1 in the examination of a surgical specimen from a patient that had undergone surgery for cryptorchidism with removal of an atrophied testis.

Two patients had a history of cryptorchidism, bilateral in 1, and contralateral to the tumour in the other.

During the diagnostic evaluation, the level of beta-hCG was measured in 18 patients (82%), and the level of AFP in 21 (95%), and they were found to be elevated in 27% and 45% of tested patients, respectively.

An ultrasound examination was performed in 90% of patients. The median size of the palpable masses was 3.5 cm (1.2–7) and the median size of nonpalpable masses was 1 cm (0.4–1.5).

A total of 18 orchiectomies and 4 tumourectomies were performed in our patients. The approach was through an inguinal incision in all. The indication for tumourectomy was based on tumour size (<2 cm) and negative results of tests for tumour markers.

The distribution by tumour histology was: 72% of germ cell tumours, treated with 14 orchiectomies (7 mixed germ cell tumours [6 with a choriocarcinoma or embryonal carcinoma component], 5 teratomas, 2 yolk sac tumours) and 2 tumourectomies (2 teratomas); and 27% of non-germ cell tumours, treated with 4 orchiectomies (2 granulosa cell tumours, 1 Sertoli cell tumour, 1 non-Hodgkin lymphoma) and 2 tumourectomies (2 Leydig cell tumours). The median tumour size was 1 cm (0.4–1.5) in the cases treated with tumourectomy and 2.5 cm (0.5–14) in the cases treated with orchiectomy.

Elevation of beta-hCG at diagnosis corresponded to choriocarcinomatous tumours, and elevation of AFP to tumours with a yolk sac component.

The followup of these patients consisted of visits in our clinic at 1 week, 1 month and 6 months post surgery, and yearly thereon. In every visit, patients underwent a testicular ultrasound examination to assess parenchymal morphology and a blood test with measurement of tumour markers to ascertain their decline. All patients were referred to the Department of Haematology and Oncology, whose staff determined how patients should be managed and the need for followup in the department's clinics based on the histopathological findings.

Six patients, all with mixed germ cell tumour histology, received postoperative chemotherapy consisting of 2 cycles of bleomycin/etoposide/cisplatin. During the followup, tumour marker levels became negative in all patients except one that died of metastatic disease. The duration of followup was 5 years (1–15); 4 patients remain in followup per protocol in the hospital that was the source of referral.

One patient died; he had a mixed germ cell tumour (with a choriocarcinoma component comprising 50%) and developed metastases in the lung and liver, bone marrow failure secondary to chemotherapy and septic shock. None of the other patients experienced local recurrence or metastasis during the followup. Only 1 patient underwent surgery for insertion of a testicular prosthesis.

Discussion

Testicular tumours are infrequent in the paediatric age group. The epidemiologic risk factors for the development of testicular tumours at any age describe in the literature are: history of cryptorchidism, Klinefelter syndrome, history of testicular cancer in first-degree relative, presence of contralateral tumour, and infertility.² In our sample, out of all these risk factors, we only found cryptorchidism in 2 patients.

In our study, the most frequent presentation was palpable mass (82%), which was consistent with the previous literature.^{5,10} The tumour was found by ultrasound examination in 13% of cases. The widespread use of sonography has led to an increase in the incidental detection of small testicular masses of less than 2 cm in diameter, defined as nonpalpable scrotal masses, and considered benign in 80% of cases,¹² which can consequently be treated with conservative surgery. In our sample, the postoperative histopathological examination confirmed the benign nature of these nonpalpable masses.

As for tumour markers, we found evidence that AFP is elevated (> 10 ng/mL) in 92–100% of patients with yolk sac tumours and that beta-hCG may be elevated in germ cell tumours (with mild elevation in embryonal carcinomas or seminomas containing syncytiotrophoblastic giant cells, and marked elevation in cases with a choriocarcinoma component).³ In our study, at the time of diagnosis, AFP was elevated in 45% of cases (every yolk sac tumour and tumours with a teratoma component) and beta-hCG in 27% (every tumour with a choriocarcinoma component or with syncytiotrophoblastic giant cells). The levels of tumour markers normalised during the followup except in 1 patient that died of advanced metastatic disease. For the purposes of diagnosis and followup, it is important to consider that patients aged less than 12 months may exhibit a physiological elevation of AFP, with levels of up to 100 ng/mL.⁸

The histology of testicular tumours varies depending on the cell line from which they originate. Germ cell tumours are the most frequent type, amounting to 95% of total cases in adults and 65% of cases in the paediatric age group.⁵ In our series, germ cell tumours constituted 75% of the sample.

Teratomas are usually benign in prepubertal patients, so they may be treated with tumourectomy in cases where ultrasound examination reveals viable normal testicular tissue and with normal levels of AFP, or, in infants aged less than 12 months, elevated AFP levels that do not exceed 100 ng/mL.⁸ Yolk sac tumours are the most frequent type of malignant tumour in children, and, like embryonal carcinomas, usually develop before age 2 years.^{5–8} They are treated with radical orchiectomy. Radical retroperitoneal lymph node dissection is performed routinely in adult patients, but in children this depends on staging, as most cases in prepubertal patients (85%) are stage I. At present, the lymph nodes are not routinely removed, except in patients with more advanced disease. Stromal tumours are rare in the prepubertal age group and may be associated with precocious puberty. The tumours that recur most frequently are Sertoli cell tumours, whose incidence peaks at age 6 months. Thirty percent of Sertoli cell tumours are associated to endocrine syndromes or abnormalities (Peutz-Jeghers syndrome, Carney complex, Cushing disease, pituitary adenomas). Tumour

resection is usually curative in children.² Malignant cases are rare and usually occur in older children, and therefore performance of radical orchiectomy with postoperative followup is recommended in patients aged 5 years and older.¹⁰ Leydig cell tumours develop between ages 5 and 10 years, are generally benign and tumour resection is usually curative. Juvenile granulosa cell tumours usually appear in the first year of life, most commonly in the first 6 months; it is the most frequent testicular tumour in newborns and has a good prognosis in this age group, unlike granulosa cell tumours that develop in postpubertal patients.¹⁰

Orchiectomy was the surgical approach used in 18 patients (82% of our sample). Six of them (5 of postpubertal age), all of who had mixed tumours with a choriocarcinoma or embryonal carcinoma component, received postoperative chemotherapy consisting of 2 cycles of bleomycin/etoposide/cisplatin.

A conservative surgical approach with tumourectomy has been performed in our hospital since 2009 and was the approach used in 18% of our sample. The decision to change the approach to the management of testicular masses was motivated by the possibility of sparing a large amount of testicular tissue thanks to the benign course of the disease in the prepubertal age group, the higher prevalence of favourable histology, and the low probability of recurrence.^{1,3,7-11}

We conducted a retrospective analysis of cases in a sample of our patients and found that 3 patients could have been treated with tumourectomy instead, as they met the criteria for management with this procedure (prepubertal, negative tumour markers, tumour size < 2 cm).

One of the patients died during the followup of advanced disease with distant metastasis. We found no other cases of recurrence in either the orchiectomy or the tumourectomy, which demonstrates the high cure rate in both patients with favourable histology and patients with unfavourable histology.^{2,12,14-19}

In conclusion, testicular masses in prepubertal patients are different from those in postpubertal patients, as they have a different epidemiology, histology and prognosis. Therefore, the approach to their management should not be the same: we can consider a conservative surgical approach with tumourectomy in patients that meet the benign testicular tumour criteria (small size and negative tumour markers).

Conflicts of interest

The authors have no conflicts of interest to declare

References

- Taskinen S, Fagerholm R, Aronniemi J, Rintala R, Taskinen M. Testicular tumors in children and adolescents. *J Pediatr Urol.* 2008;4:134-7.
- Albers P, Albrecht W, Algaba F, Bokemeyer C, Cohn-Cedermark G, Fizazi K, et al. EAU guidelines on testicular cancer. *Eur Urol.* 2011;60:304-19, 2011 update.
- Caballero Mora FJ, Muñoz Calvo MT, García Ros M, Rodríguez de Alarcón J, Fernández Pérez ML, Casco F, et al. Tumores testiculares y paratesticulares en la infancia y adolescencia. *An Pediatr (Barc).* 2013;78:6-13.
- WHO Classification of tumors of the urinary system and male genital organs Moch H, Humphrey A, Ulbright TM, Reuter VE. Tumors of the testis and paratesticular tissue. Lyon: International Agency for Research on Cancer; 2016.
- Bujons A, Sfulcini JC, Pascual M, Feu OA, Garat JM, Villavicencio H. Prepubertal testicular tumours and efficacy of testicular preserving surgery. *BJU Int.* 2011;107:1812-6.
- Chung JM, Lee SD. Overview of pediatric testicular tumors in Korea. *Korean J Urol.* 2014;55:789-96.
- Nistal M, Paniagua R, González-Peramato P, Reyes-Múgica M. Perspectives in pediatric pathology, chapter 25. Testicular and paratesticular tumors in the pediatric age group. *Pediatr Dev Pathol.* 2016;19:471-92.
- Hisamatsu E, Takagi S, Nakagawa Y, Sugita Y, Yoshino K, Ueoka K, et al. Prepubertal testicular tumors: a 20-year experience with 40 cases. *Int J Urol.* 2010;17:956-9.
- Epifanio M, Baldissera M, Esteban FG, Baldisserotto M. Mature testicular teratoma in children: multifaceted tumors on ultrasound. *Urology.* 2014;83:195-7.
- Wang X, Xu S, Tang D, Li M, Wu D, Huang Y. Prepubertal testicular and paratesticular tumors in China: a single-center experience over a 10-year period. *J Pediatr Surg.* 2012;47:1576-80.
- Metcalfe PD, Farivar-Mohseni H, Farhat W, McLorie G, Khoury A, Bagli DJ. Pediatric testicular tumors: contemporary incidence and efficacy of testicular preserving surgery. *J Urol.* 2003;170 Pt 1:2412-5.
- Borghesi M, Brunocilla E, Schiavina R, Gentile G, Dababneh H, Della Mora L, et al. Role of testis sparing surgery in the conservative management of small testicular masses: oncological and functional perspectives. *Actas Urol Esp.* 2014;39:57-62.
- Brunocilla E, Gentile G, Schiavina R, Borghesi M, Franceschelli A, Pultrone CV, et al. Testis-sparing surgery for the conservative management of small testicular masses: an update. *Anticancer Res.* 2013;33:5205-10.
- Mennie N, King SK, Marulaiah M, Ferguson P, Heloury Y, Kimber C. Leydig cell hyperplasia in children: case series and review. *J Pediatr Urol.* 2017. pii:S1477-5131(17)30055-4.
- Emre S, Ozcan R, Elicevik M, Emir H, Soylet Y, Buyukunal C. Testis sparing surgery for Leydig cell pathologies in children. *J Pediatr Urol.* 2017;51, e1-51.e4.
- Giannarini G, Mogorovich A, Menchini Fabris F, Morelli G, De Maria M, Manassero F, et al. Long-term follow-up after elective testis sparing surgery for Leydig cell tumors: a single center experience. *J Urol.* 2007;178:872-6.
- Huyghe E, Soulie M, Escorru G, Mieuisset R, Plante P, Thonneau P. Conservative management of small testicular tumours relative to carcinoma in situ prevalence. *J Urol.* 2005;173:820-3.
- Giannarini G, Mogorovich A, Bardelli I, Manassero F, Selli C. Testis-sparing surgery for benign and malignant tumors: a critical analysis of the literature. *Indian J Urol.* 2008;24:467-74.
- Shukla AR, Woodard C, Carr MC, Huff DS, Canning DA, Zderic SA, et al. Experience with testis sparing surgery for testicular teratoma. *J Urol.* 2004;171:161-3.