

**Table 2** Clinical presentation and associated organ injury.

	N	Percentage
Shock	14	100
Fever	14	100
Exanthema	9	64.3
Erythroderma	6	42.8
Posterior desquamation	7	50
Neurologic dysfunction	8	57.1
Gastrointestinal symptoms	3	21.4
Thrombocytopenia/coagulopathy	11	78.6
Liver disease	11	78.6
Acute kidney injury	10	71.4
Necrotising fasciitis/pyomyositis	3	21.4

It is crucial that this condition is detected early and the patient referred to a facility with intensive care services.<sup>1,5</sup> When TSS is suspected, the patient should be placed on life support, as would be done in cases of septic shock, with the addition of antitoxin treatment (antimicrobials such as clindamycin), surgical debridement, and administration of immunoglobulin to enhance plasma neutralising activity against toxins.<sup>6</sup>

## References

- Chen KYH, Cheung M, Burgner DP, Curtis N. Toxic shock syndrome in Australian children. *Arch Dis Child*. 2016;101:736–40.

- Costa Orvay JA, Caritg Bosch J, Morillo Palomo A, Noguera Julián T, Esteban Torne E, Palomeque Rico A. Síndrome de shock tóxico: experiencia en una UCIP. *An Pediatr (Barc)*. 2007;66:566–72.
- Dosil Gallardo S, Jordan Garcia I, Morteruel Arizcuren E, Rodríguez Nuñez A. Streptococcal toxic shock syndrome: an emerging pathology? *An Pediatr (Barc)*. 2009;7:310–1 [Article in Spanish].
- Adalat S, Dawson T, Hackett SJ, Clark JE. Toxic shock syndrome surveillance in UK children. *Arch Dis Child*. 2014;99:1078–82.
- Rodríguez-Nuñez A, Dosil-Gallardo S, Jordan I, ad hoc Streptococcal Toxic Shock Syndrome collaborative group of Spanish Society of Pediatric Intensive Care. Clinical characteristics of children with group A streptococcal toxic shock syndrome admitted to pediatric intensive care units. *Eur J Pediatr*. 2011;170:639–44.
- Carapetis JR, Jacoby P, Carville K, Ang SJ, Curtis N, Andrews R. Effectiveness of clindamycin and intravenous immunoglobulin, and risk of disease in contacts, in invasive group A streptococcal infections. *Clin Infect Dis*. 2014;59:358–65.

Laura Butragueño Laiseca<sup>a,\*</sup>, Marina García Morín<sup>a</sup>, Estíbaliz Barredo Valderrama<sup>a</sup>, Andrés J. Alcaraz Romero<sup>b</sup>

<sup>a</sup> Servicio de Pediatría, Hospital General Universitario Gregorio Marañón, Madrid, Spain

<sup>b</sup> Servicio de Cuidados Intensivos Pediátricos, Hospital General Universitario Gregorio Marañón, Madrid, Spain

\*Corresponding author.

E-mail address: [laura\\_bl@hotmail.com](mailto:laura_bl@hotmail.com)

(L. Butragueño Laiseca).

2341-2879/

© 2016 Asociación Española de Pediatría. Published by Elsevier España, S.L.U. All rights reserved.

## Clinical impact of translocation t(7;15) (p22;q26) on several family members<sup>☆</sup>



## Repercusión clínica de la traslocación t(7;15) (p22;q26) en varios miembros de una misma familia

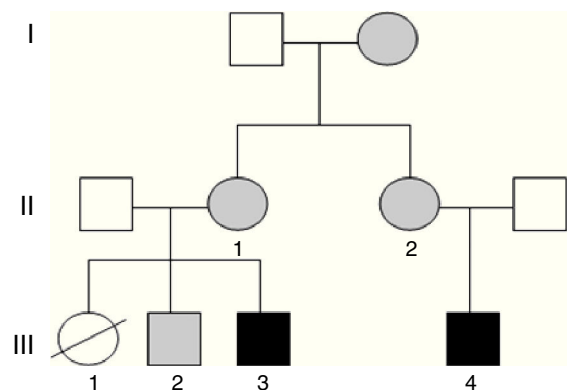
Dear Editor:

Global developmental delay (GDD) and intellectual disability (ID) are frequent diseases that have a considerable social impact and a varied aetiology. Cytogenetic testing by comparative genomic hybridisation (CGH) array analysis has increased the number of aetiological diagnoses in our paediatric neurology clinic by more than 20%.<sup>1</sup>

We present the clinical cases in a family with several members with ID in whom testing detected balanced and

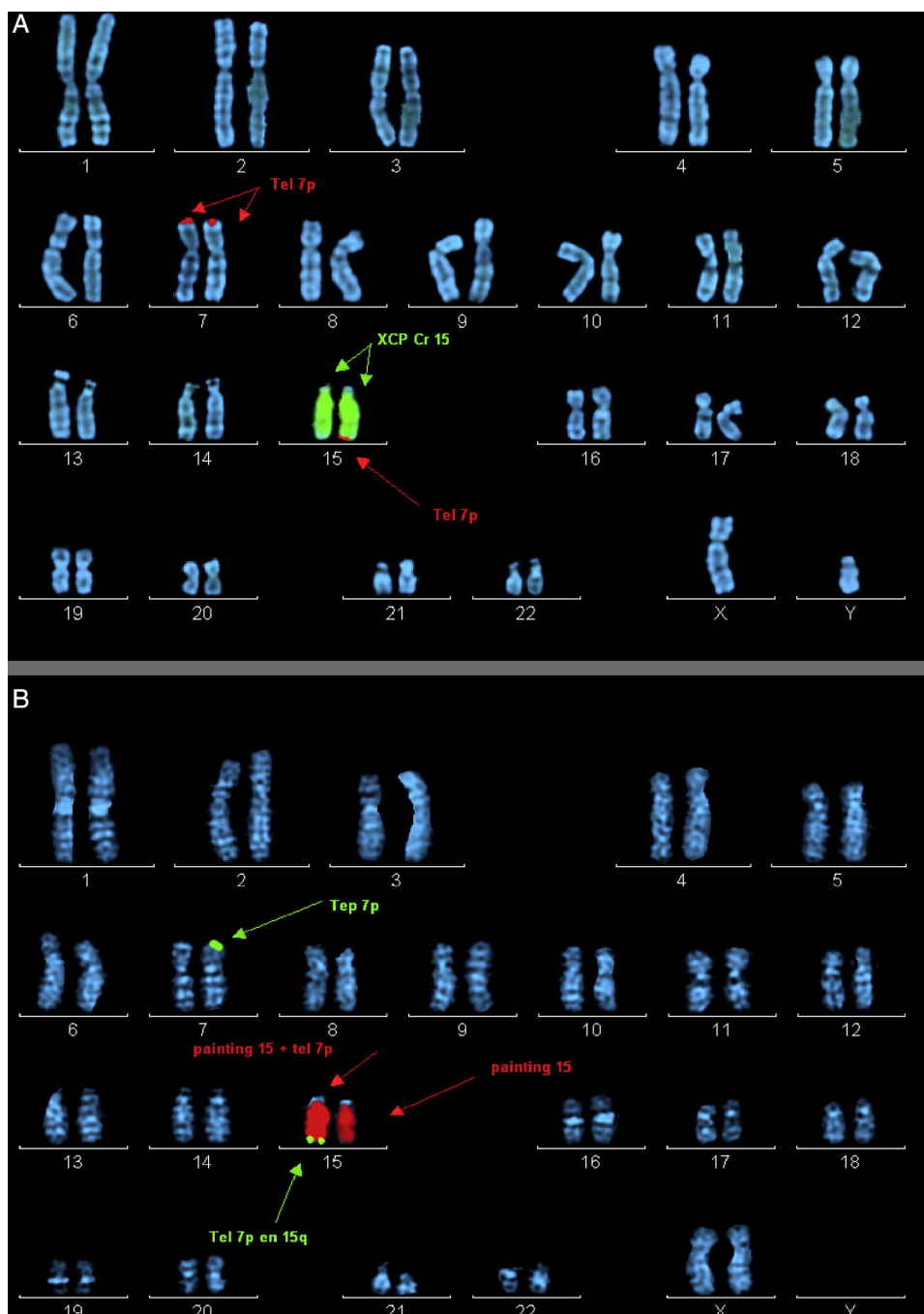
unbalanced chromosomal rearrangements secondary to a different chromosomal segregation process in each.

Case 1 (Fig. 1, individual III.4): boy aged 5 years, only child, with ID, oppositional behaviours, deficits in propositional language and no sphincter control. He had microcephaly from birth (head circumference,  $-4.21$  SD), with height and weight at the 75th percentile, a dysmorphic



**Figure 1** Pedigree chart of the individuals presented in this article. In black: individuals with unbalanced translocation and intellectual disability. In grey: individuals with balanced translocations (III.3 = case 2; III.4 = case 1).

<sup>☆</sup> Please cite this article as: Caballero Pérez V, López-Pisón FJ, Miramar Gallart MD, González Álvarez A, García Jiménez MC. Repercusión clínica de la traslocación t(7;15) (p22;q26) en varios miembros de una misma familia. *An Pediatr (Barc)*. 2017;87:113–115.



**Figure 2** Ordered metaphase chromosomes labelled by means of fluorescence in situ hybridisation (FISH). (A) Case 2 proband. Labelled with probe XCP Cr15 (marked with central arrows) and telomere probe 7p (marked by top and bottom arrows). (B) Mother of case 2. Labelled with probe XCP Cr15 (marked by central arrows) and telomere probe 7p (marked by top and bottom arrows).

phenotype, hexadactyly in both feet, and atrial septal defect that required surgery. Testing by CGH array detected a duplication at the 15q26.3 locus and a partial deletion of the 7p22 region.

Haploinsufficiency of the *MAD1L1*, *FTSJ2*, *NUDT1*, *SNX8*, *EIF3B* and *FAM20C* genes in chromosome 7, whose dosage was abnormal in the patient, has been associated to heart malformations and ID.<sup>2</sup>

Increased dosage of the distal region of chromosome 15 has been associated with 15q overgrowth syndrome

(tendency to macrosomia, polydactyly, ID and behavioural problems), described in more than 100 patients.<sup>3</sup> Classically it has been associated with the *IGF1R* gene. However, a recent study described a family in which the duplication was not found in this gene, as occurred in case 1, and proposed that it was located in the *LRKK1* gene instead (of which there were also 3 copies in case 1 in our series), giving rise to the described phenotype. This gene encodes a protein that is believed to be involved in the regulation of cell growth and proliferation.<sup>4</sup>

Case 2 (Fig. 1, individual III.3): boy aged 3 years, first cousin of case 1, whose older sister died at age 2 months after suffering from transposition of the great vessels, cleft lip and microcephaly (Fig. 1, individual III.1). The boy presented with GDD, macrocephaly, dysmorphic features, delayed fontanelle closure, joint hyperlaxity and clubfoot. Array analysis detected a deletion in region 15q26.3 and duplication of the 7p22.3p22.1 locus (Fig. 2).

As for partial trisomy of the 5.1 Mb distal segment of the short arm of chromosome 7, which alters the dosage of more than 40 *RefSeq* genes, there are more than 40 patients with similar duplications described in the literature. They are characterised by a specific facial dysmorphism (macrocephaly, delayed fontanelle closure, hypertelorism and low-set ears) in addition to ID, language disorders, hypotonia, low birth weight, cryptorchidism and heart malformations. A recent study has attributed macrocephaly to the duplication of *RNF216*, which was found in case 2 (III.3).<sup>5</sup>

On the other hand, the terminal deletion of the long arm of chromosome 15, of approximately 2.2 Mb, impacts more than 10 *RefSeq* genes. To present, 12 cases with distal deletions have been described in the literature, manifesting with pre- and postnatal growth retardation, heart malformations, developmental delays and dysmorphic features.<sup>6</sup>

The mothers of both subjects (who are sisters) had the karyotype 46, XX t(7;15) (p22;q26), and there was a healthy sibling of case 2 with karyotype 46, XY t(7;15) (p22;q26) and normal array results (Fig. 1, individual III.2). Subsequently, we found out that the maternal grandmother was also a carrier of the balanced translocation.

It is essential that all members of the family receive genetic counselling, given the high probability that the sister (III.1) of case 2 (III.3) and the cousin of case 1 (III.4) had inherited an unbalanced translocation. Heart disease, which was found in the patient, is associated both to deletions and duplications in the short arm of chromosome 7; however, duplications manifest with macrocephaly, which was present in her brother (case 2, III.3), so it is more likely that she had a deletion in chromosome 7 and a duplication in chromosome 15, as did her cousin (case 1, III.4); both of them had microcephaly, which is frequent in genetic neurodevelopmental disorders.

Individuals that carry more than one variant of the pathological number of copies have more severe phenotypes. Due to this fact and the variable expression of many of these chromosomal disorders, it is difficult to establish genotype–phenotype correlations in these patients.

On the other hand, we ought to highlight recent findings obtained through massive sequencing of the breakpoints of balanced as well as unbalanced translocations, with chromosome rearrangements at multiple breakpoints with inversions or insertions that cannot be detected by other techniques that break or fuse the genes located in these regions, and its relevance to clinical practice.<sup>7</sup>

Thus, multidisciplinary teams should be formed to better interpret the results of genetic tests, with clinicians and geneticists working in close collaboration. Doing this can not only achieve an aetiological diagnosis, which allows the optimisation of management and genetic counselling of families, but also prevent the performance of unnecessary tests.

## References

1. Caballero Pérez V, López Píson FJ, Miramar Gallart MD, González Álvarez A, García Jiménez MC, García Iñiguez JP, et al. Phenotype in patients with intellectual disability and pathological results in array CGH. *Neurologia*. 2016; <http://dx.doi.org/10.1016/j.nrl.2016.03.006>, pii:S0213-4853(16)30027-5 [in English, Spanish].
2. Richards EG, Zaveri HP, Wolf VL, Kang SH, Scott DA. Delineation of a less than 200 kb minimal deleted region for cardiac malformations on chromosome 7p22. *Am J Med Genet A*. 2011;155A:1729–34.
3. Tatton-Brown K, Pilz DT, Orstavik KH, Patton M, Barber JC, Collinson MN, et al. 15q overgrowth syndrome: a newly recognized phenotype associated with overgrowth, learning difficulties, characteristic facial appearance, renal anomalies and increased dosage of distal chromosome 15q. *Am J Med Genet A*. 2009;149A:147–54.
4. Leffler M, Puusepp S, Žilina O, Zhu Y, Kuuse K, Bain N, et al. Two familial microduplications of 15q26.3 causing overgrowth and variable intellectual disability with normal copy number of IGF1R. *Eur J Med Genet*. 2016;59:257–62.
5. Caselli R, Ballarati L, Vignoli A, Peron A, Recalcati MP, Catusi I, et al. 7p22.1 microduplication syndrome: clinical and molecular characterization of an adult case and review of the literature. *Eur J Med Genet*. 2015;58:578–83.
6. Pinson L, Perrin A, Plouzennec C, Parent P, Metz C, Collet M, et al. Detection of an unexpected subtelomeric 15q26.2 → qter deletion in a little girl: clinical and cytogenetic studies. *Am J Med Genet A*. 2005;138A:160–5.
7. Weckselblatt B, Hermetz KE, Rudd MK. Unbalanced translocations arise from diverse mutational mechanisms including chromothripsis. *Genome Res*. 2015;25:937–47.

Victoria Caballero Pérez<sup>a,\*</sup>, Francisco Javier López-Píson<sup>b</sup>,  
María Dolores Miramar Gallart<sup>c</sup>, Alejandro González  
Álvarez<sup>d</sup>, María Concepción García Jiménez<sup>b</sup>

<sup>a</sup> *Servicio de Pediatría, Hospital Obispo Polanco, Teruel, Spain*

<sup>b</sup> *Sección de Neuropediatría, Hospital Infantil Universitario Miguel Servet, Zaragoza, Spain*

<sup>c</sup> *Sección de Genética, Hospital Universitario Miguel Servet, Zaragoza, Spain*

<sup>d</sup> *Servicio de Farmacia, Hospital Obispo Polanco, Teruel, Spain*

\*Corresponding author.

E-mail address: [vcaballero@salud.aragon.es](mailto:vcaballero@salud.aragon.es)

(V. Caballero Pérez).

2341-2879/

© 2016 Asociación Española de Pediatría. Published by Elsevier España, S.L.U. All rights reserved.