

SCIENTIFIC LETTERS

Improved lung function in cystic fibrosis using mechanical insufflation–exsufflation

Mejora de la función pulmonar en fibrosis quística mediante insuflación-exuflación mecánica

Dear Editor:

Cystic fibrosis (CF) is a progressive multisystemic disease that impairs quality of life. Respiratory manifestations are the main source of morbidity and mortality, and chest physiotherapy (CPT) is one of the main approaches used to improve mucociliary clearance.¹ Mechanical insufflation–exsufflation (MIE) devices deliver a high enough pressure to produce a shearing force that dislodges and mobilises secretions outward. There is evidence that MIE can improve airway clearance in patients with neuromuscular diseases² and on its use for treating bronchiectasis in patients without CF,³ but further research is needed to support its use in children with CF.¹

In order to assess the impact of MIE on lung function in children with a diagnosis of CF, we designed a prospective study with a 24-month followup to compare the combined use of CPT—which is part of the routine approach to CF management—and MIE (treatment group, $n=9$) with the use of CPT alone (control group, $n=11$). Every participant met all the inclusion criteria and none of the exclusion criteria (Table 1). All procedures were performed after obtaining the informed consent of the parents. The intervention in the treatment group was performed every 21 days for 45 min. It consisted of three cycles of six to eight breaths with the patient in a reclined position (inspiratory time, 5 s; expiratory time, 5 s; pause time, 2 s; pressure, +30 to –35 cmH₂O; device, Philips CoughAssist®). To better clear bronchial obstruction, we applied pressure in the abdomen. We performed pulse oximetry before and after each session. Adhering to the guidelines of the Sociedad Española de Neumología y Cirugía Torácica (Spanish Society of Pulmonology and Thoracic Surgery [SEPAR]), we assessed lung function at baseline and at 6, 12, 18 and 24 months of treatment by means of spirometry, defining improvement as an increase of at least 5% in the forced vital capacity (FVC) and forced expiratory volume in the first second (FEV1); and worsening

as a decrease of 5% or more (Table 1). Two of the nine patients in the treatment group were eventually excluded, one due to fear of the device and the other due to lack of cooperation. Although the baseline lung function of patients in the treatment group was worse than that of patients in the control group, we observed an increasing trend in FEV1 (%) after the intervention that was sustained through the followup (Fig. 1), as well as a statistically significant increase in FVC (%). In fact, the improvement in FEV1 (%) was positively and significantly correlated with receiving CPT ($r=0.47$; $P<.05$) and with improvement in FVC (%) ($r=0.72$; $P<.05$). In the control group, we observed statistically significant decreases in FEV1 (%) and FVC (%). Table 1 shows the clinical characteristics of the patients. The results of the Kaplan–Meier analysis of variations in percent FEV1 between groups were consistent with the improvement observed in the patients that received the treatment, as it estimated a six-month difference between both groups in favour of the treatment group ($P<.05$). As for nutritional status, we found no significant differences in body mass index between the groups, a parameter that has been assessed in the paediatric population with CF in recent years.⁴

The clinical characteristics of our patients were consistent with those described in the literature,⁴ although the spirometric values in the treatment group were below those reported in previous studies,^{4,5} a circumstance that

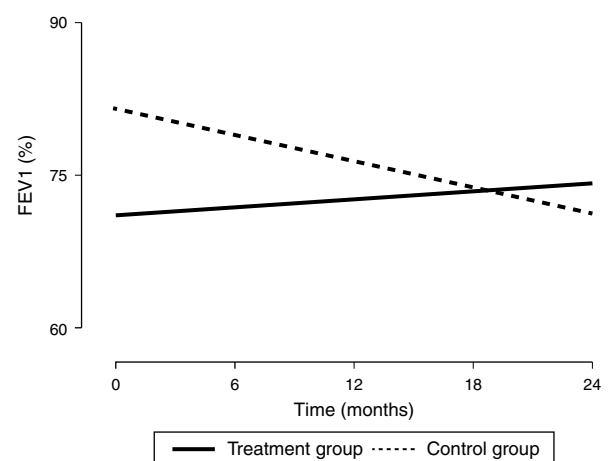


Figure 1 Changes in lung function (expressed as %FEV1) from baseline to the end of the intervention. FEV1, forced expiratory volume in the first second expressed as percentage. The values were expressed as the percentage of the theoretical value for individuals of the same age, weight and height based on the Spanish reference population.

☆ Please cite this article as: Fuentes LA, Caro P, Garcia-Ruiz AJ, Muñoz Gómez G, Martín-Montañez E. Mejora de la función pulmonar en fibrosis quística mediante insuflación-exuflación mecánica. An Pediatr (Barc). 2017;86:350–352.

Table 1 Clinical characteristics of the patients.

Patient number ^a	Age/sex	Genotype GenA/GenB	Pancreatic sufficiency (yes/no)	Main presenting feature	Baseline BMI	BMI at 24 months	Δ FEV1/ Δ FVC (%)	Disease progression
<i>Patients treated with MIE</i>								
1	6.7/F	F508	No	Pneumonia	15.6	17.6	-20.3/-10.2	Worsening
2	6.1/F	F508	No	Faltering weight	16.1	17.3	26.8/27.7	Improvement
3	6.6/M	F508/G542V	No	Meconium ileus	16.1	16.4	4.5/10.9	Stable
4	14.3/F	R334W/R347P	Yes	Persistent cough	18.8	19.5	5.4/5.9	Improvement
5	7.5/F	2183AA-G/Q850X	No	Faltering weight	16.3	17.6	18.9/20.2	Improvement
6	8.7/M	F508	No	Faltering weight	14.2	18.5	4.9/19.7	Improvement
7	11.5/F	2183AA-GF508	No	Persistent cough	16.1	19.6	11.7/9.9	Improvement
<i>Patients not treated with MIE</i>								
8	6.8/F	F508	No	Meconium ileus	14.6	16.6	-8.7/-6.2	Worsening
9	6.3/F	F508/I507	No	Persistent cough	15.4	16.8	-5.8/-8	Worsening
10	11.1/F	F508	No	Meconium ileus	15.8	19.11	-10.8/-9.2	Worsening
11	10.2/M	F508	No	Faltering weight	16.2	19.2	-27.7/-27.4	Worsening
12	10.8/M	F508	No	Meconium ileus	15.8	17.9	-22.8/-5	Worsening
13	7.2/M	F508	No	Faltering weight	15.9	17.7	-4.2/-6.9	Stable
14	9.4/F	F508/2184	Yes	Pancreatitis	14.7	17.9	-5.4/-4.1	Stable
15	11.7/M	W1282X-R334W	Yes	Persistent cough	16.1	19.6	-4.6/-0.8	Stable
16	9.1/M	W1282X-R334W	Yes	Persistent cough	16.4	18.8	-16.1/-16.7	Worsening
17	14.5/F	F508/3272-16AG	Yes	Persistent cough	17.9	20.4	-19.7/-26	Worsening
18	14.3/F	F508/I507	No	Faltering weight	18.2	18.9	-15.2/-11.1	Worsening

BMI, body mass index (in kg/m²); F, female; FEV1, forced expiratory volume in the first second, expressed as percentage (%); FVC, forced vital capacity, expressed as percentage (%); M, male; MIE, mechanical insufflation-exsufflation; Δ , change in lung function parameter. FEV1 and FVC values were expressed as percentages of the predicted theoretical value for age, weight and height based on the Spanish reference population.

^a The patients included in the table met the following inclusion criteria, and none of the exclusion criteria. Inclusion criteria: diagnosis of CF based on internationally accepted criteria; undergoing periodic check-ups in the CF unit; age between 6 and 14 years; ability to perform manoeuvres required for lung function testing; understanding the purpose of the study; signed informed consent. Exclusion criteria: patients at radiologic or clinical risk of pneumothorax or pneumomediastinum; patients with barotrauma in the month prior to entry in the study; past history of massive or life-threatening haemoptysis; transplant recipients or patients awaiting a transplant.

probably contributed to their decision to participate in the study. As Table 1 shows, while lung function did not improve in any of the patients in the control group after 24 months, in the treatment group it improved in five out of the seven patients, remained stable in one, and worsened only in one. The values of FEV1 (%) in the treatment group tended to improve with the intervention (Fig. 1), while the control group exhibited the natural course of CF, that is, a progressive decline in lung function.⁵ Based on these results, the proposed CPT intervention could slow down

disease progression. In our study, we did not observe any side effects associated with the use of the device, and the technique was safe and well tolerated. We only found that coughing produced irritation in the pharynx or headache in some instances, and these effects were not at play in the two patients that dropped out. In conclusion, this is the first paediatric case series describing the combined use of conventional CPT and MIE in patients with CF, and it demonstrated an improvement in lung function over a follow-up period of at least two years. Consequently, this may be a

good approach for preventing lung function impairment in this population, although multicentric studies need to be developed to reach solid evidence-based conclusions.

Acknowledgments

We thank the Asociación contra la Fibrosis Quística (Association against Cystic Fibrosis) of Malaga.

References

1. McIlwaine MP, Lee Son NM, Richmond ML. Physiotherapy and cystic fibrosis: what is the evidence base? *Curr Opin Pulm Med.* 2014;20:613–7.
2. Bento J, Goncalves M, Silva N, Pinto T, Marinho A, Winck JC. Indicaciones y cumplimiento con la insuflación-exuflación mecánica domiciliar en pacientes con enfermedades neuromusculares. *Arch Bronconeumol.* 2010;46:420–5.
3. González Bellido V, González Conde W, Bermejo Moreno I, Ruiz Tajadura R, García Pérez L. Ensayo clínico aleatorizado de técnicas de aclaramiento mucociliar en niños con bronquiectasias sin fibrosis quística. *Fisioterapia.* 2013;35:92–8.
4. Alexander S, Alshafi K, Anderson AK, Balfour-Lynn I, Bentley S, Buchdahl R, et al. Clinical guidelines for the care of children with cystic fibrosis. 6th ed. Royal Brompton Hospital Paediatric Cystic Fibrosis Team; 2014. Available from: <http://www.rbht.nhs.uk/childrencf> [accessed 25.03.16].
5. Konstan MW, Morgan WJ, Butler SM, Pasta DJ, Craib ML, Silva SJ, et al. Risk factors for rate of decline in forced expiratory volume in one second in children and adolescents with cystic fibrosis. *J Pediatr.* 2007;151:134–9.

Laura Azahara Fuentes^a, Pilar Caro^a,
Antonio Jose Garcia-Ruiz^a, Gregorio Muñoz Gómez^b,
Elisa Martín-Montañez^{a,*}

^a Departamento de Farmacología y Pediatría, Universidad de Málaga Instituto de Investigación Biomédica de Málaga (IBIMA), Málaga, Spain

^b Terapia Ocupacional, Universidad Alfonso X el Sabio, Madrid, Spain

* Corresponding author.

E-mail address: emartinm@uma.es (E. Martín-Montañez).

2341-2879

© 2016 Asociación Española de Pediatría. Published by Elsevier España, S.L.U. All rights reserved.

Unilateral amaurosis as an initial symptom of juvenile idiopathic arthritis[☆]



Amaurosis unilateral como síntoma inicial de artritis idiopática juvenil

Dear Editor:

Juvenile idiopathic arthritis (JIA) is the most prevalent chronic inflammatory joint disease in the paediatric age group, and it affects one in two thousand children aged less than 16 years. It is a diagnosis by exclusion that encompasses all cases of arthritis of unknown aetiology of more than six weeks duration and with onset prior to age 16 years. There are seven clinical subtypes, the most common of which is oligoarticular JIA.

The disease may have different extra-articular manifestations, of which JIA-associated uveitis (JIAU) is the most prevalent, affecting 12%–20%¹ of patients.

On account of its singularity, we present the case of a girl aged 7 years with silent oligoarticular JIA and chronic anterior uveitis whose first symptom was unilateral amaurosis.

The patient sought care in our emergency department in August of 2015 for esotropia and redness in the right eye. The girl reported conjunctival hyperaemia, hyperlacrimation and photophobia in the right eye (RE) lasting six months, for which she had sought care in other health care facilities in the past and received a diagnosis of allergic conjunctivitis.

On ophthalmologic examination, she exhibited amaurosis in the RE, which did not perceive light, a fact that had not been noticed by either the patient or her family, with normal visual acuity in the left eye. Slit-lamp biomicroscopy revealed band keratosis, with multiple thick keratic precipitates in the middle and lower third of the cornea and grade 3+ cells and flare. She also had a white cataract with 360° synechiae (Fig. 1). The intraocular pressure was 3 mmHg (normal range, 11–21 mmHg). Since a fundus examination was not possible due to the presence of the cataract, the patient underwent an ultrasound examination of the eye that revealed no abnormalities in the vitreous body or posterior chamber.

A diagnosis of cataract and acute uveitis was made and treatment with topical corticosteroids initiated, and the patient was referred to paediatric rheumatology for assessment. During the anamnesis, the patient did not report any joint pain or systemic symptoms or any relevant personal or family history. The physical examination revealed a mild synovial fluid leak in the right knee that was painless and did not impair mobility, which was confirmed by ultrasonography (Fig. 2). The results of the antinuclear antibody test (ANA) were negative, and the patient received a diagnosis of ANA-negative oligoarticular JIA.

The patient was given intra-articular steroid injections in the affected knee and methotrexate (15 mg/m²/week) via the subcutaneous route in addition to the ongoing topical ophthalmologic treatment. Seven months after achieving resolution of the ophthalmologic and articular symptoms, the patient underwent surgery to break the irido-crystalline synechiae and remove the cataract by phacoemulsification and aspiration due to the hardness of the lens core. Ten days after the surgery, the patient exhibited a visual acuity of 0.05 in the RE.

[☆] Please cite this article as: Rubio San Simón A, Ortueta Olarte-cochea A, Barral Mena E, Tejada Palacios P, de Inocencio Arocena J. Amaurosis unilateral como síntoma inicial de artritis idiopática juvenil. *An Pediatr (Barc).* 2017;86:352–353.