



IMAGES IN PAEDIATRICS

Thoracic mass as a manifestation of bifid rib

Masa torácica como manifestación de costilla bífida



René Gómez-Lainsa^a, Carlos Leganés Villanueva^{b,c,*}, Nuria Brun Lozano^{b,c},
María Ángeles López-Vílchez^{a,c}

^a Servicio de Pediatría, Hospital Parc Salut Mar, Barcelona, Spain

^b Departamento de Cirugía Pediátrica, Servicio de Pediatría, Hospital Parc Salut Mar, Barcelona, Spain

^c Universitat Pompeu Fabra, Barcelona, Spain

Available online 6 January 2025

A boy aged 7 years was referred to the pediatric surgery clinic for assessment of a mass in the rib with onset a few months prior and no associated symptoms. The examination revealed a hard, firm mass measuring 2 × 2 cm in the left hemithorax at the level of the body of the fourth rib.

The chest radiograph performed at the outpatient level on account of a previous episode of respiratory illness revealed the presence of a mass compatible with bifid rib (Fig. 1). A computed tomography scan of the thorax (Fig. 2) confirmed the diagnosis and the absence of adjacent abnormalities. The approach to management was conservative with annual followup in the pediatric surgery clinic.

The prevalence of rib anomalies in the general population is of 2%, and bifid rib accounts of 28% of these anomalies.¹ It is usually unilateral, right-sided, more prevalent in male individuals and not associated with vertebral anomalies.^{1,2} They are usually asymptomatic and found by chance. In our case, it manifested as a thoracic mass. However, in some cases it is associated with respiratory or neurologic symptoms or other deformities of the rib cage, and it can also

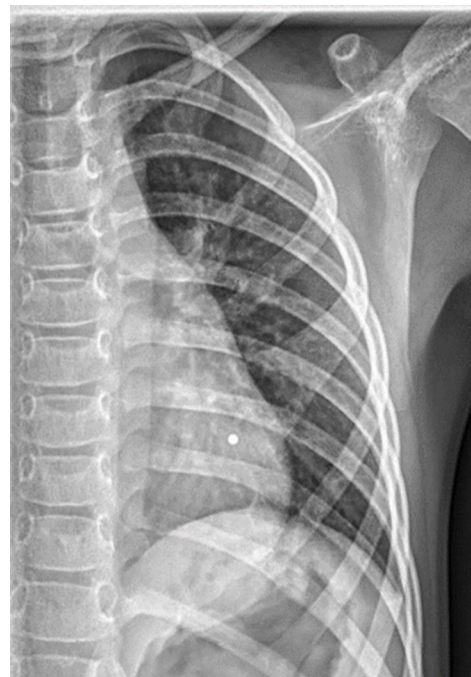


Figure 1 Anteroposterior chest radiograph. Bifurcation of the fourth rib in the left ribcage.

DOI of original article:

<https://doi.org/10.1016/j.anpedi.2024.503698>

* Corresponding author.

E-mail address: claganes@psmar.cat (C. Leganés Villanueva).

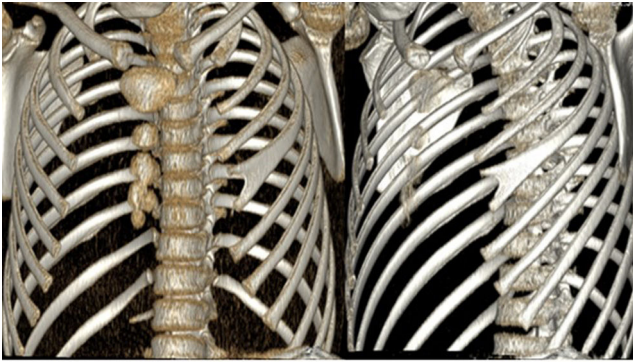


Figure 2 Computed tomography scan of the thorax: 3D reconstruction showing a bifid rib at the level of the body of the left fourth rib.

be associated with syndromic disorders such as Gorlin-Goltz syndrome.^{2,3}

The detection of this anomaly at an early age allows initiation of followup and the identification of cases possibly associated with other diseases.

Declaration of competing interest

The authors have no conflicts of interest to declare.

References

1. Wattanasirichaigoon D, Prasad C, Schneider G, Evans JA, Korf BR. Rib defects in patterns of multiple malformations: a retrospective review and phenotypic analysis of 47 cases. *Am J Med Genet A*. 2003;122A:63–9.
2. Andrea A, Tardieu G, Fisahn C, Iwanaga J, Oskouian RJ, Shane R. Bifid ribs: a comprehensive review. *Anatomy*. 2016;10: 221–7.
3. Kimonis VE, Mehta SG, DiGiovanna JJ, Bale SJ, Pastakia B. Radiological features in 82 patients with nevoid basal cell carcinoma (NBCC or Gorlin) syndrome. *Genet Med*. 2004;6: 495–502.