



## IMAGES IN PAEDIATRICS

## Uncommon cause of unilateral paralysis of the hypoglossal nerve

### Causa infrecuente de parálisis unilateral del nervio hipogloso

Sandra Maeso-Méndez\*, Eider Jauregui Benito, Miriam Gendive Martín, Concepción Salado Marín



Planta de Hospitalización, Servicio de Pediatría, Hospital Universitario Araba, Sede Txagorritxu, Vitoria-Gasteiz, Álava, Spain

Received 19 November 2022; accepted 13 February 2023

Available online 22 July 2023

We present the case of a boy aged 3 years with abrupt onset of lateral deviation of the tongue to the right on protrusion and difficulty chewing, without swallowing difficulties. There was no known preceding trauma. The physical examination revealed isolated paralysis of the right hypoglossal nerve (Fig. 1).

Neuroimaging scans showed bone abnormalities at the level of the craniovertebral junction and the cervical and dorsal spine (Fig. 2), suggestive of Klippel-Feil syndrome, which would explain the clinical presentation. This congenital syndrome is characterised by fusion of cervical and dorsal vertebrae and it may be associated with other malformations and neurologic abnormalities.

The patient remains clinically stable.

Hypoglossal nerve paralysis is rare in the paediatric population, and it is characterised by ipsilateral deviation of the tongue on protrusion and changes in the oral phase of swallowing.

The aetiological diagnosis is complicated and requires knowledge of the nerve's course. It arises from the brainstem, travels in relation to the atlanto-occipital joint and exits the skull through a canal in the anterior occipital condyle. It passes by the internal carotid artery and enters

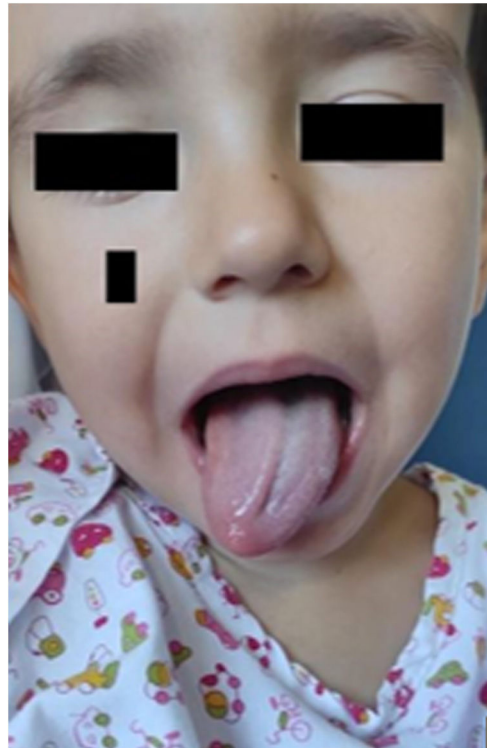
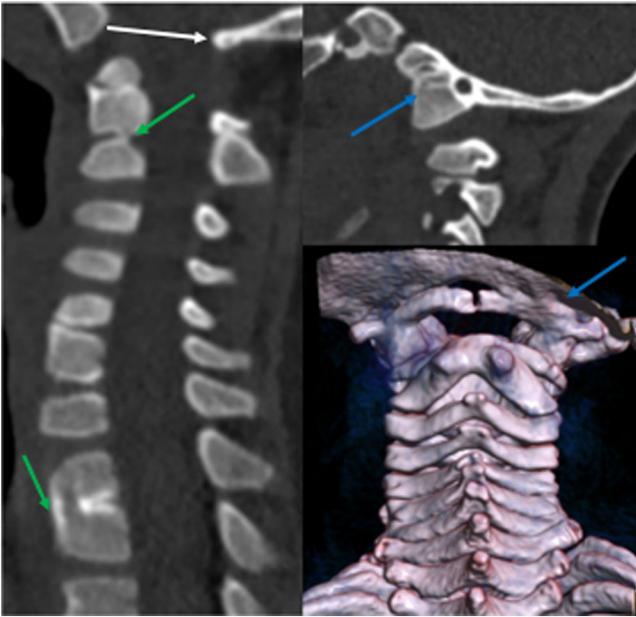


Figure 1 Deviation of the tongue to the right on protrusion.

DOI of original article: <https://doi.org/10.1016/j.anpedi.2023.02.006>

\* Corresponding author.

E-mail address: [sandra.maesomendez@osakidetza.eus](mailto:sandra.maesomendez@osakidetza.eus) (S. Maeso-Méndez).



**Figure 2** Computed tomography of the skull and cervical spine: stenosis of the foramen magnum (white arrow), right-sided atlanto-occipital assimilation (blue arrows) and partial fusing of several vertebrae (green arrows).

the floor of the mouth to innervate the muscles of the tongue.<sup>1</sup>

Hypoglossal nerve paralysis is caused by tumours or has an iatrogenic or idiopathic aetiology in most cases,<sup>1,2</sup> and it is rarely caused by trauma,<sup>3</sup> vascular lesions or congenital anomalies such as Arnold-Chiari malformation.<sup>1</sup>

## References

1. Vicente-Pascual M, Gallego-Sánchez Y, Vázquez-Justes D, Andreu-Mencia L. Etiología de la parálisis del nervio hipogloso. Revisión sistemática. *Rev ORL*. 2021;12(1):46–53.
2. Ibarra V, Jaureguiberry A, Moretta G, Lazzarini G, Ceruzzi R, Reich E. Parálisis idiopática y unilateral del nervio hipogloso. *Medicina*. 2015;75:173–4.
3. Mano T, Tatsumi S, Fujimura S, Hotta N, Kido A. Isolated bilateral hypoglossal nerve paralysis following an atlanto-occipital dislocation: a case report. *Front Neurol*. 2022;13:965717.