

SCIENTIFIC LETTERS

VE1 immunohistochemistry to determine BRAF^{V600E} mutation in Langerhans-cell histiocytosis



Inmunohistoquímica ve1 para determinar la mutación de braf en la histiocitosis de células de langerhans

Dear Editor:

Langerhans cell histiocytosis (LCH) is a disease with heterogeneous manifestations whose immune or neoplastic origin has not been clearly established. Somatic changes in the BRAF proto-oncogene (BRAF^{V600E} variant) are found in more than 50% of LCH lesions. Our aim was to validate the use of immunohistochemistry with the VE1 monoclonal antibody as a simpler and faster approach than molecular techniques for the diagnosis of BRAF^{V600E}-positive LCH.

Between 1976 and 2015, 91 patients underwent evaluation, with a mean age at diagnosis of 4 years (range, 0.08–17). Twenty-five percent had single-system forms of disease (SS-LCH), most frequently involving skin or bone, and 70% multisystemic forms of disease (MS-LCH). The median duration was 4 years, with an overall survival of 94% (95% CI, 91–97). We obtained biobank samples for 13 patients applying the following criteria: (1) Diagnosis of LCH based on the morphological analysis of the haematoxylin-eosin stain and immunohistochemical staining for proteins S100 and CD1a; (2) availability of histological sections in paraffin, and (3) exclusion of bone tissue samples to avoid distortion due to immunohistochemical expression secondary to the decalcification with nitric acid required for the processing of these samples. We did not find significant differences in the clinical characteristics of this subset of patients compared to the total group of patients under consideration, so we considered the sample representative. The presence of BRAF^{V600E} was assessed by

quantitative polymerase chain reaction (PCR) (BRAF V600 Mutation Test; Roche®) and with a BRAF^{V600E} immunohistochemistry test (VE1 antibody, VENTANA® Medical Systems). The BRAF^{V600E} immunoreactivity was classified with a semi-quantitative scale as negative (–), weak (+), moderate (++) or strong (+++). Samples with strong staining were considered positive.^{1,2}

Among the 13 samples under study, BRAF^{V600E} was detected in 6 (46%). The concordance between the diagnosis made by molecular techniques and by immunohistochemistry was 100%, with detection of BRAF^{V600E} by PCR in every sample with strong immunoreactivity (+++) (Table 1).

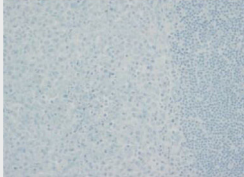

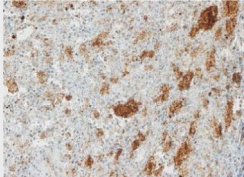
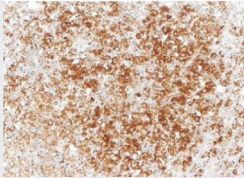
The results suggest that the BRAF^{V600E} variant plays an important role in approximately half the patients with LCH. These genetic changes support the conceptualization of BRAF^{V600E}-positive LCH as a neoplastic disease, given the evidence of clonality in the lesions.^{3,4} Other authors consider that in the absence of this variant, the basis of LCH could be a process of immune dysregulation causing inflammation.⁵

The importance of the detection of BRAF^{V600E} in LCH resides in its potential as a therapeutic target, opening up new possibilities for treatment in refractory patients.⁶ Furthermore, we propose the use of VE1 immunohistochemistry as an alternative to molecular methods for detection of the BRAF^{V600E} variant, as it is both reliable and easy to perform and interpret.

Funding

This study was partly funded by the Fundación CRIS contra el cáncer (<https://criscancer.org/es/>). The Fundación CRIS contra el cáncer was not involved in the design or implementation of the study or the publication of the manuscript.

Table 1 Clinical characteristics and BRAF^{V600E} results obtained through immunohistochemistry with the VE1 antibody (VENTANA® Medical Systems) and real-time PCR (cobas® test, Roche).

	Age at diagnosis	Disease form	Tissue	VE1 IHC	BRAF V600E PCR	Total sample: IHC/PCR
1	2 years	MS-LCH	Lymph node	Negative	Unmutated	2 negative (15.4%)/Zero mutated (0%) 
2	1 month	SS-LCH	Lung	Negative	Unmutated	4 weak (30.8%)/Zero mutated (0%) 
3	2 months	SS-LCH	Skin	+	Unmutated	
4	1 year	MS-LCH	Skin	+	Unmutated	
5	7 months	MS-LCH	Lymph node	+	Unmutated	1 moderate (7.2%)/Zero mutated (0%) 
6	4 years	SS-LCH	Muscle	+	Unmutated	
7	8 years	SS-LCH	Soft tissues	++	Unmutated	
8	4 years	SS-LCH	Soft tissues	+++	Mutated	6 strong (46.2%)/6 mutated (46.2%) 
9	13 years	SS-LCH	Orbit	+++	Mutated	
10	1 year	SS-LCH	Skin	+++	Mutated	
11	10 months	MS-LCH	Ear	+++	Mutated	
12	1 month	MS-LCH	Gum	+++	Mutated	
13	1 month	MS-LCH	Skin	+++	Mutated	

The images correspond to a representative case in the subsets of patients with negative, weak, moderate or strong immunohistochemical staining.

IHQ: immunohistochemistry; MS-LCH, multisystem Langerhans cell histiocytosis; PCR, polymerase chain reaction; SS-LCH, single-system Langerhans cell histiocytosis.

References

- Sun J, Zhang J, Lu J, Gao J, Lu T, Ren X, et al. Immunohistochemistry is highly sensitive and specific for detecting the BRAF V600E mutation in papillary thyroid carcinoma. *Int J Clin Exp Pathol.* 2015;8:15072–8.
- Manfredi L, Meyer N, Tournier E, Grand D, Uro-Coste E, Rochaix P, et al. Highly concordant results between immunohistochemistry and molecular testing of mutated V600E BRAF in primary and metastatic melanoma. *Acta Derm Venereol.* 2016;96:630–4.
- Mehes G, Irsai G, Bedekovics J, Beke L, Fazakas F, Rozsa T, et al. Activating BRAF V600E mutation in aggressive pediatric Langerhans cell histiocytosis: demonstration by allele-specific PCR/direct sequencing and immunohistochemistry. *Am J Surg Pathol.* 2014;38:1644–8.
- Brown NA, Furtado LV, Betz BL, Kiel MJ, Weigelin HC, Lim MS, et al. High prevalence of somatic MAP2K1 mutations in BRAF V600E-negative Langerhans cell histiocytosis. *Blood.* 2014;124:1655–8.
- Héritier S, Emile JF, Hélias-Rodzewicz Z, Donadieu J. Progress towards molecular-based management of childhood Langerhans cell histiocytosis. *Arch Pediatr.* 2019;26:301–7.
- Héritier S, Emile JF, Barkaoui MA, Thomas C, Fraitag S, Boudjemaa S, et al. BRAF mutation correlates with high-risk langerhans cell histiocytosis and increased resistance to first-line therapy. *J Clin Oncol.* 2016;34:3023–30.

Esther Casado-López^{a,b}, Jimena Rey-García^{b,c},
 Víctor Galán-Gómez^e, José Juan Pozo-Kreillinger^{b,d},
 Antonio Pérez-Martínez^{b,e,*}

^a Servicio de Oftalmología, Hospital Universitario Puerta de Hierro-Majadahonda, Majadahonda, Madrid, Spain

^b Facultad de Medicina, Universidad Autónoma de Madrid, Madrid, Spain

^c Servicio de Medicina Interna, Hospital Universitario Ramón y Cajal, IRyCIS, Madrid, Spain

^d Servicio de Anatomía Patológica, Hospital Universitario La Paz, Madrid, Spain

^e Servicio de Hemato-Oncología Pediátrica, Hospital Universitario La Paz, Madrid, Spain

* Corresponding author.

E-mail address: aperezmartinez@salud.madrid.org (A. Pérez-Martínez).

<https://doi.org/10.1016/j.anpede.2022.04.014>

2341-2879/ © 2022 Asociación Española de Pediatría. Published by Elsevier España, S.L.U. This is an open access article under the CC BY-NC-ND license (<http://creativecommons.org/licenses/by-nc-nd/4.0/>).

Coxsackievirus-induced myocarditis



Miocarditis agudas por virus coxsackie

Dear Editor:

Acute myocarditis is a life-threatening myocardial inflammatory disease mainly caused by viral infections. Virus-induced myocarditis can refer to virus-mediated or virus-triggered (immune-mediated) disease; coxsackieviruses may cause virus-mediated myocarditis, as viral replication can cause direct cardiomyocyte injury.¹

There are critical knowledge gaps regarding the diagnosis, prognosis and treatment of myocarditis. The aim of this report is to describe the clinical presentation of coxsackievirus-induced myocarditis and its outcomes.

Coxsackievirus is one of the most common causative agents of myocarditis in children. In a period of 14 years (April 2007 to September 2021), there were 5 cases of coxsackievirus-induced myocarditis confirmed by polymerase chain reaction (PCR) testing of blood samples out of 55 cases of viral myocarditis, making coxsackievirus the second leading causative agent in the sample following parvovirus B19.

The cases occurred in 4 newborns (median age 16.5 days, range 8–24) and 1 infant aged 10-months. [Table 1](#) presents the demographic and clinical characteristics of the sample.

Certain *Enterovirus* serotypes are associated with particular clinical phenotypes and age groups.² In the subset of cases of *Enterovirus* infection in our sample, coxsackievirus was the only detected virus, as it is the predominant type causing myocarditis.³ Four fifths of the patients with coxsackievirus were newborns, and other viruses were found in older children. As previously described, *Enterovirus* myocarditis and sepsis affect significantly younger children compared to other presentations.² A systematic review of severe neonatal enterovirus infections found that 54.7% of the cases of myocarditis occurred in newborns aged less than 7 days.³ Coxsackievirus–adenovirus-receptor (CAR) is a key element of coxsackievirus-induced myocarditis that also plays a role in cardiac morphogenesis. Its expres-

sion peaks in the perinatal period, after which levels decrease with age, thereby decreasing the risk of fatal myocarditis.⁴

The infection may be transmitted vertically, before or after delivery, or horizontally.³ All cases in our sample involved horizontal transmission, with a history of upper respiratory tract infection preceding heart dysfunction by a median of 4 days (range, 1–7), although the tracheal aspirate PCR test was only positive in 1 patient. While it has been reported that PCR cycle threshold values are considerably lower in faecal samples compared to blood,² routine faecal PCR testing in neonates with myocarditis may identify the etiological agent efficiently.

All newborns presented with severe disease in the form of cardiogenic shock, which was consistent with previous studies^{2,3} and could be explained by their functionally immature immune system³ and upregulated expression of CAR in the perinatal period.⁴ The infant presented with heart failure. None of the patients had arrhythmia. All patients required admission to the intensive care unit and inotropic support, and all but one (80%) mechanical ventilation. On the other hand, adults usually develop mild symptoms, with only 8.6% presenting with fulminant myocarditis in a retrospective registry.¹

Electrocardiographic abnormalities were present in 3 patients: ventricular repolarization abnormalities (2/5, 40%) and q waves (2/5, 40%). The initial blood tests showed elevated levels of troponin and creatine kinase. The echocardiographic assessment revealed left ventricular (LV) dysfunction in every patient (median ejection fraction, 30%; IQR, 13%), LV dilatation in 1, left atrial dilatation in 4 and mitral valve regurgitation in 4. Left ventricular hypertrophy was present in 4 patients (80%). Significant right ventricular dysfunction was present in 2 patients.

The clinical diagnosis of myocarditis was confirmed in all but one patient by cardiovascular magnetic resonance imaging (CMR), the primary tool for non-invasive assessment of myocardial inflammation.⁵ [Table 1](#) documents the Lake-Louise criteria and the presence of pericardial effusion. The patient that did not undergo CMR in the acute phase presented with cardiogenic shock almost requiring mechanical