

## Bibliografía

1. Bouchard M, Hoschtitzky A, Gatzoulis M. Diagnosis and management of congenital absence of pericardium: a case report. *Eur Hear J Case Rep.* 2019;3(4):1–5.
2. Shah AB, Kronzon I. Congenital defects of the pericardium: a review. *Eur Heart J Cardiovasc Imaging.* 2015;16(8):821–7.
3. Verde F, Johnson PT, Jha S, Fishman EK, Zimmerman SL. Congenital absence of the pericardium and its mimics. *J Cardiovasc Comput Tomogr.* 2013;7(1):11–7.
4. Maisch B, Seferović PM, Ristić AD, Erbel R, Rienmüller R, Adler Y, et al. Guidelines on the diagnosis and management of pericardial diseases: executive summary. The task force on the diagnosis and management of pericardial diseases of the European Society of Cardiology. *Eur Heart J.* 2004;25(7):587–610.
5. Pérez-Casares A, Cesar S, Brunet-García L, Sanchez-de-Toledo J. Echocardiographic evaluation of pericardial effusion and cardiac tamponade. *Front Pediatr.* 2017;5:1–10.
6. Macaione F, Barison A, Pescetelli I, Pali F, Pizzino F, Terrizzi A, et al. Quantitative criteria for the diagnosis of the congenital absence of pericardium by cardiac magnetic resonance. *Eur J Radiol.* 2016;85(3):616–24.

Laia Brunet-García<sup>a,\*</sup>, Juan Manuel Carretero Bellón<sup>b,c</sup>, Alex Pérez-Casares<sup>b</sup>, Fredy Hermógenes Prada Martínez<sup>b</sup>, Joan Sánchez-de-Toledo<sup>b</sup>

<sup>a</sup> *Unidad de Cardiología Pediátrica, Consorci Sanitari del Maresme, Hospital de Mataró, Mataró, Barcelona, Spain*

<sup>b</sup> *Unidad de Cardiología Pediátrica, Hospital Sant Joan de Déu, Esplugues de Llobregat, Barcelona, Spain*

<sup>c</sup> *Unidad de Cardiología Pediátrica, Hospital Universitari Joan XXIII, Universitat Rovira i Virgili, Tarragona, Spain*

\* Corresponding author.

E-mail addresses: [laiabrunetg@gmail.com](mailto:laiabrunetg@gmail.com), [lbrunetga@gmail.com](mailto:lbrunetga@gmail.com) (L. Brunet-García).

<https://doi.org/10.1016/j.anpede.2022.04.006>  
2341-2879/ © 2021 Asociación Española de Pediatría. Published by Elsevier España, S.L.U. This is an open access article under the CC BY-NC-ND license (<http://creativecommons.org/licenses/by-nc-nd/4.0/>).

## Unicentric experience in percutaneous stent treatment of aortic coarctation in children and teenagers<sup>☆</sup>



### Experiencia unicéntrica en el tratamiento percutáneo con stent de la coartación de aorta en niños y adolescentes

To the editor:

The advantages of stenting for treatment of coarctation of the aorta compared to balloon angioplasty is that it avoids excessive dilation of the adjacent aorta and elastic recoil of the vessel, in addition to sealing potential acute dissections, thereby reducing the incidence of aneurysms, recurrence of coarctation and aortic rupture. Most hospitals consider it the procedure of choice for native coarctation and for recurrent coarctation in patients with weights greater than 25 to 30 kg, in whom the calibre of femoral arteries is usually adequate.<sup>1</sup> Below this weight, although there is not sufficient evidence to establish the optimal therapeutic approach, angioplasty or surgery are used in most cases.<sup>2,3</sup> We conducted a retrospective analysis of all the patients aged less than 18 years managed with percutaneous stent implantation between 1996 and 2020 and followed up for at least 1 year. The resulting consecutive sample included 25 patients with a mean age of 10.6 years and a mean weight of 33.9 kg, of who 16% had weights of less than 30 kg. Thirteen patients were treated for native coarctation and 12 for recurrence of coarctation treated with surgery. Three of the cases of

recurrent coarctation had required angioplasty due to a previous recurrence before placement of the stent. The most frequent associated cardiac defects were bicuspid aortic valve and ventricular septal defect (VSD) (Table 1).

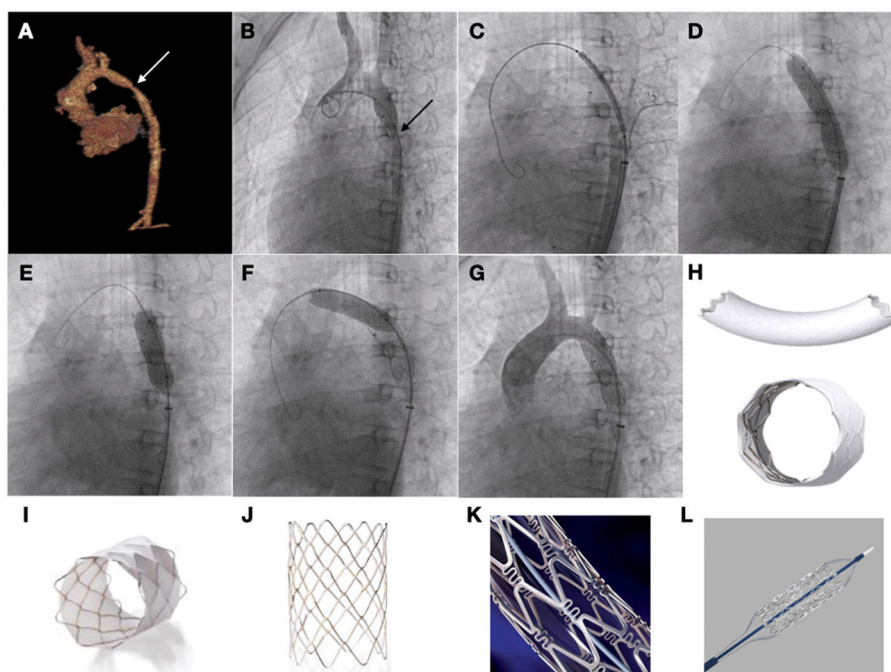
In 20 cases (80%) the coarctation was at the level of the aortic isthmus, in 2 (12%) at the level of the aortic arch (8%) at the level of the diaphragmatic aorta.

**Table 1** Clinical and haemodynamic characteristics of the sample.

Clinical variables	
Mean age ± SD (years)	10.6 ± 4.6
Mean weight ± SD (kg)	33.9 ± 18.9
Male sex	18 (72%)
Associated heart defects (other than aortic valve defect)	5 (20%)
VSD	
Anomalous pulmonary venous return	1 (4%)
Bicuspid aortic valve	14 (56%)
Significant aortic valve disease	2 (8%)
Type of coarctation	
Native	13 (52%)
Recurrent	12 (48%)
Previous surgical treatment	
End-to-end anastomosis	8 (32%)
Subclavian flap	3 (12%)
Patch aortoplasty	1 (4%)
Previous angioplasty	3 (12%)
Haemodynamic variables	
Aortic arch diameter ± SD (mm)	13.2 ± 3.8
Diaphragmatic aorta diameter ± SD (mm)	15.12 ± 4.4
Coarctation diameter ± SD (mm)	
Previous procedure ± SD	5.1 ± 2.2
After stenting ± SD	14.6 ± 3.7
Transaortic gradient (invasive)	
Previous ± SD	33.6 ± 14.3
After stenting ± SD	2.8 ± 4.1
Stent diameter ± SD (mm)	15 ± 4.2
Stent length ± SD (mm)	38.8 ± 18.2
Need of more than 1 stent	2 (8%)
ePTFE-covered stent	6 (24%)

ePTFE: expanded polytetrafluoroethylene; SD, standard deviation; VSD, ventricular septal defect.

<sup>☆</sup> Please cite this article as: Fernández González L, Alcibar Villa J, Blanco Mata R, Arriola Meabe J, Galdeano Miranda JM. Experiencia unicéntrica en el tratamiento percutáneo con stent de la coartación de aorta en niños y adolescentes. *An Pediatr (Barc).* 2022;96:542–544.



**Figure 1** Patient aged 10 years with Williams syndrome and recurrent coarctation of aorta referred for percutaneous stent implantation. (A and B) CT and angiography images showing narrowing of the aortic lumen. (C) Advancing the stent to the target area. (D) Inflation of stent with visualization of reduced expansion at the level of the isthmus. (E and F) Post-dilation of both the distal and the proximal portions of the stent. (G) Angiographic verification. (H) BeGraft stent. (I) Covered CP stent. (J) CP stent (uncovered). (K) Palmaz Genesis stent. (L) Formula stent.

All procedures were performed via the femoral approach with guiding catheters ranging from 8F to 16F under general anaesthesia. The size of the stent was chosen based on the measurements obtained by computed tomography and angiography, with a 1:1 ratio for the stent diameter and the diameter of the aorta at the level of the diaphragm unless there was a significant difference in diameter at the level of the aortic arch, which requires adjusting the stent to the proximal diameter for post-dilation of the distal end with a larger balloon to adjust it to the size of the diaphragmatic aorta.

Stenting was successful in 100% of cases, achieving both a reduction of the transcoarctation pressure gradient and an increase in the diameter of the aortic lumen, differences that were statistically significant. In 19 cases, the implanted stents were uncovered: Palmaz (Cardinal Health Inc, Dublin, OH, USA), CP stent (NuMED Inc, Hopkinton, NY, USA) and Formula (Cook Medical, Bloomington, IN, USA). Another 6 were covered with expanded polytetrafluoroethylene: covered CP stent (NuMED Inc, Hopkinton, NY, USA) and BeGraft (Bentley InnoMed GmbH, Hechingen, Germany) (Fig. 1).

All patients remained in follow-up for a mean of 12.9 years (SD,  $\pm 7.4$ ), with monitoring of symptoms and radiological features. Five patients (20%) required reintervention in mean of  $6.9 \pm 8.7$  years. In 2 patients it consisted of surgical repair with prosthetic material due to a calibre mismatch, in 2 cases of implantation of a secondary stent overlapping the first due to recurrence of coarctation at the distal end, and in 1 case in redilation of the proximal end of the stent. The observed complications were 2 cases of

femoral artery thrombosis that resolved with conservative management with anticoagulants.

The variables that were significantly associated with the need of reintervention were previous repair with balloon angioplasty and coarctation at the level of the aortic arch or the diaphragm ( $P < 0.05$ ). One patient (4%) developed post-cardiotomy shock after undergoing a hybrid procedure for surgical repair of a complex cardiac defect and stenting at the level of the aortic arch, and died 24 hours after.

In the paediatric and adolescent population, the cardiac anatomy is usually not complex or associated with calcification or substantial tortuosity, so the procedure is usually performed with uncovered stents, which have a very favourable safety profile in both the short and long term, with an incidence of complications at the level of the aortic wall of less than 2%, and a smaller calibre, which is important for the prevention of complications at the vascular access site. Covered stents are reserved for cases of complex cardiac anatomy, presence of prostheses or Turner or Williams syndrome, which are associated with a more fragile aortic wall and therefore a higher risk of complications.<sup>4,5</sup> It is important to select the appropriate time for the intervention and the correct stent size, since growth can give rise to a calibre mismatch, and consequently stents should be selected to allow further expansion with growth, even considering sequential dilation strategies, which has an impact on the rate of reintervention compared to the adult population.<sup>6</sup> Taking these aspects into account, we consider that stent implantation for management of coarctation of aorta in the paediatric and adolescent population is safe and effective in the long term.

## Bibliografía

- Forbes TJ, Garekar S, Amin Z, Zahn EM, Nykanen D, Moore P, et al. Procedural results and acute complications in stenting native and recurrent coarctation of the aorta in patients over 4 years of age: a multi-institutional study. *Catheter Cardiovasc Interv.* 2007;70:276–85.
- Forbes TJ, Kim DW, Du W, Turner DR, Holzer R, Amin Z, et al. Comparison of surgical, stent, and balloon angioplasty treatment of native coarctation of the aorta: an observational study by the CCISC (Congenital Cardiovascular Interventional Study Consortium). *J Am Coll Cardiol.* 2011;58:2664–74.
- Mohan UR, Danon S, Levi D, Connolly D, Moore JW. Stent implantation for coarctation of the aorta in children <30 kg. *JACC Cardiovasc Interv.* 2009;2:877–83.
- Meadows J, Minahan M, McElhinney DB, McEnaney K, Ringel R. Intermediate outcomes in the prospective, multicenter coarctation of the aorta stent trial (COAST). *Circulation.* 2015;131:1656–64.
- Taggart NW, Minahan M, Cabalka AK, Cetta F, Usmani K, Ringel RE. COAST II Investigators. Immediate outcomes of covered stent placement for treatment or prevention of aortic wall injury associated with coarctation of the aorta (COAST II). *JACC Cardiovasc Interv.* 2016;9:484–93.
- Pan M, Ojeda S, Hidalgo F, Suárez de Lezo J, Lostalo A, Mazuelos F, et al. Percutaneous reintervention on aortic coarctation stenting. *EuroIntervention.* 2020;15:1464–70.

Luis Fernández González<sup>a,\*</sup>, Juan Alcibar Villa<sup>a</sup>, Roberto Blanco Mata<sup>a</sup>, Josune Arriola Meabe<sup>a</sup>, Jose Miguel Galdeano Miranda<sup>b</sup>

<sup>a</sup> *Cardiología Intervencionista, Hospital Universitario de Cruces, Baracaldo, Vizcaya, Spain*

<sup>b</sup> *Cardiología Pediátrica, Hospital Universitario de Cruces, Baracaldo, Vizcaya, Spain*

\* Corresponding author.

E-mail address: [luisfg82@hotmail.com](mailto:luisfg82@hotmail.com)

(L. Fernández González).

<https://doi.org/10.1016/j.anpede.2021.08.005>

2341-2879/ © 2021 Asociación Española de Pediatría. Published by Elsevier España, S.L.U. This is an open access article under the CC BY-NC-ND license (<http://creativecommons.org/licenses/by-nc-nd/4.0/>).

## The resurgence of acute bronchiolitis cases after the declaration of the end of state of emergency<sup>☆</sup>



### Resurgimiento de los casos de bronquiolitis aguda tras la declaración del final del estado de alarma

Dear Editor:

Acute bronchiolitis (AB) is a viral infection that causes annual outbreaks, in the case of Spain, with the epidemic season starting approximately in October of one year and ending in March or April the following year.<sup>1</sup> The non-pharmacological interventions implemented on the Spanish population as a result of the coronavirus 2019 (COVID-19) pandemic were responsible, at least in part, for a decrease in the incidence of childhood infectious diseases<sup>2</sup>, including AB.<sup>3,4</sup> In May 9, 2021, the government of Spain declared the end of the state of alarm, which was followed by a progressive de-escalation of the preventive measures implemented until that time. This could have led to the re-emergence of different viral agents involved in the pathogenesis of AB, as described in other geographical areas.<sup>5</sup>

In an extension of a previous study<sup>3</sup> and in the framework of the same research project, the Spanish Collaborative Study for the Care of Infants Hospitalised with Acute

Bronchiolitis (known by the acronym of its Spanish name, ECEALHBA), we conducted a substudy with the aim of determining whether there was a resurgence of AB cases in the form of an outbreak after the state of alarm was lifted, and to compare the outbreaks in different epidemic seasons, in addition to the frequency of hospitalization, grouped in different periods based on the pandemic.

We collected data on the cases of AB that required admission prospectively from April 16 to August 31, 2021 on the same study variables and applying the same inclusion criteria.<sup>3</sup> Thus, we analysed all cases of AB over 6 epidemic seasons, 2015–2016 to 2020–2021. We established 3 study periods based on 2 key dates: (1) Prepandemic period (P1), from September 1, 2015 to March 15, 2020 (declaration of state of alarm); (2) COVID-19 pandemic during state of alarm (P2), from March 15, 2020 to May 9, 2021 (end of state of alarm), and (3) COVID-19 pandemic after lifting of state of alarm (P3), from May 9, 2021 to the end of data collection.

A total of 4809 infants with a median age of 2.4 months (interquartile range, 1.4–4.5) and a median length of stay (LOS) of 4.4 days (standard deviation, 2.7), of who 384 (8.0%) required admission to the intensive care unit (ICU). The epidemic seasons before the pandemic took place in the typical time of year, the winter months, while in the 2020–2021 season, during the pandemic, it took place in the summer months and was shorter and less severe compared to preceding seasons (Table 1A and Fig. 1).

The most common profile of infants admitted to hospital during P2 compared to P1 and P3 was male sex, older age, negative for respiratory syncytial virus (RSV), with a shorter LOS and not requiring admission to the ICU. However, when we compared infants admitted during P3 (the period with the summer outbreak) with those admitted in P1 (period with typical winter outbreaks), these differences were not significant (Table 1B).

<sup>☆</sup> Please cite this article as: Rius-Peris JM, Marcilla Vázquez C, Molini Menchón N, Felipe Almira E, Silvestre Beneyto R, en representación del Grupo Investigador Proyecto ECEALHBA. Resurgimiento de los casos de bronquiolitis aguda tras la declaración del final del estado de alarma. *An Pediatr (Barc).* 2022;96:544–547.