



SCIENTIFIC LETTER

Casuistics of inflammatory myofibroblastic tumor in a tertiary center*



Casuística de tumor miofibroblástico inflamatorio en centro terciario

Dear Editor,

Inflammatory myofibroblastic tumours (IMTs) are infrequent lesions of intermediate malignant potential that develop in the first decades of life.^{1,2} They have been described to appear in multiple sites, with the lung being most common,¹ followed by the abdomen and, more rarely, the brain, orbit, soft tissues and genitourinary tract.^{2,3} Their aetiology is unknown, although some predisposing factors have been described, such as a history of surgical intervention, repeated traumatic injury, chronic infection or radiation therapy.^{2,3}

The clinical picture varies depending on the involved region. Local symptoms may develop due to a mass effect, such as cough, haemoptysis, chest pain or atelectasis in case of lung involvement or abdominal pain or melena in case of abdominal involvement.¹ Up to 40% of IMTs are asymptomatic and detected by chance in imaging tests.¹ They are frequently associated with anaemia, thrombocytosis, elevation of the erythrocyte sedimentation rate (ESR) and hypergammaglobulinaemia, especially in abdominal tumours.¹ The findings of imaging are nonspecific, usually with visualization of a well-defined, irregular solid lesion, with calcifications in 25% of cases.² In contrast-enhanced imaging, IMTs may exhibit delayed-phase heterogeneous enhancement.² Diagnosis requires ruling out other possible tumours, abscesses and chronic infections (by *Aspergillus* or mycobacteria).¹ The diagnosis is confirmed by histology, with visualization of spindle-shaped myofibroblasts and variable amounts of inflammatory cells (eosinophils, plasma cells and lymphocytes),^{2,3} and the tumours are usually positive for vimentin, actin, CD34 and CD117.^{2,3} Anaplastic lymphoma kinase (ALK) reactivity is observed in 50% of cases, more frequently in younger patients, but not in cases of distant metastasis, which are usually ALK-negative.⁴

The standard of care is complete resection of the tumour, which is curative in most cases.² However, close monitoring is required, as in some cases the tumour can recur or become malignant and require adjuvant treatment such as chemotherapy, radiation therapy or immunosuppressive drugs.¹ In the case of ALK-positive tumours, there is a specific therapeutic option: ALK inhibitors.^{5,6} These drugs play an important role, as they can be used in cases in which resection would be complicated as neoadjuvant therapy or in case of local or metastatic recurrence, thereby achieving an increase in overall survival.⁵ Crizotinib was one of the first such drugs to be used, but there have been reports of poor initial response or development of resistance after a few months of treatment, which stimulated the development of second-generation ALK inhibitors (ceritinib, alectinib) that have shown promising results.⁶

With the aim of understanding the characteristics of the cases managed in a tertiary care hospital, we conducted a retrospective descriptive study in patients aged less than 16 years managed between 2005 and 2020, and identified 5 cases of IMT. We analysed the following variables: age at diagnosis, sex, presentation at onset, tumour location, diagnostic tests performed, treatment and outcome (Table 1).

We included a total of 5 cases, corresponding to 3 boys and 2 girls. The mean age at diagnosis was 5.6 years (range, 1.8–12.2 years). Of all tumours, 2 were located in the lung, 2 in the abdomen and 1 in bone. In this case series, the most frequent clinical manifestations at onset were associated with the mass effect (pain in the ribcage, abdominal pain and seizures), although all patients also had constitutional symptoms. One patient received an initial diagnosis of pulmonary tuberculosis and another patient a diagnosis of liver abscess. The salient findings of laboratory tests were thrombocytosis (in 4 patients), anaemia (in 3) and elevation of C-reactive protein elevation (in 3), ESR (in 2) and lactate dehydrogenase (in 2).

The initial diagnosis (Fig. 1) was confirmed in all cases by the pathological examination of a biopsy sample, supplementing the histological examination with immunohistochemistry and in situ fluorescence in the most recent cases (3/3 ALK +; 3/4 actin +; 2/3 vimentin +). All patients underwent complete resection of the tumour, with favourable outcomes in 4 out of the 5 observed in the followup (median duration, 7 years). One patient experienced malignant transformation of the tumour (inflammatory fibrosarcoma) and early relapse after surgery, requiring adjuvant therapy with ceritinib, which achieved a quick initial response, but ultimately with progression in a few months resulting in death.

* Please cite this article as: Martínez Navarro G, Pérez Chamorro M, Veiga Canuto D, Juan Ribelles A, Fernández Navarro JM. Casuística de tumor miofibroblástico inflamatorio en centro terciario. An Pediatr (Barc). 2021;95:364–366.

Table 1 Series of cases of inflammatory myofibroblastic tumour reviewed in our hospital.

	Sex	Age (years)	Site	Presentation	ALK		Actin	Vimentin	First-line treatment	Recurrence	Followup (years)
					IHC	FISH					
1	F	1	Lung	Weight faltering and anaemia	NP	NP	NP	NP	Surgery	No	13
2	M	2	Liver	Fever and hepatomegaly	NP	NP	+	NP	Surgery	No	6
4	M	5	Lung	Fever and constitutional symptoms	+	NP	+	+	Surgery	No	8
3	M	12	Ribcage	Pain in ribcage and constitutional symptoms	–	+	+	–	Surgery	Yes	Died
5	F	8	Paravesical	Abdominal pain and dysuria	+	+	–	+	Surgery	No	3

F, female; FISH, fluorescent in situ hybridization; IHC, immunohistochemistry; M, male; NP, not performed.

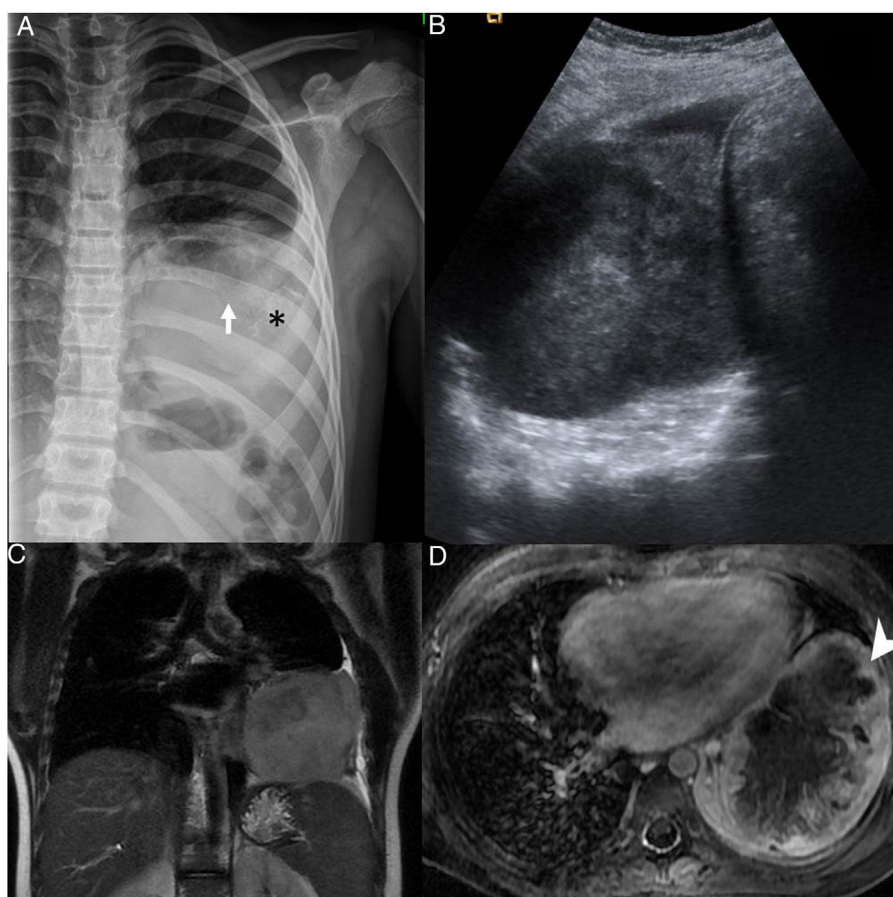


Figure 1 (A) Radiograph of the ribcage showing infiltration and partial destruction of the posterior shaft of the left 8th rib (white arrow) associated with a large intrathoracic, extrapulmonary soft-tissue mass with faint amorphous calcifications (*) and mild pleural effusion. (B) Ultrasound image of the heterogeneous mass in the thorax. (C) T2-weighted magnetic resonance imaging (MRI), coronal plane and (D) intravenous contrast-enhanced, fat-saturated T1-weighted MRI, transversal plane, showing a lobulated mass in contact with the mediastinal, pericardial, axillary and diaphragmatic pleura with peripheral enhancement (arrow point) and necrosis in the central area.

Inflammatory myofibroblastic tumours have an intermediate malignant potential. Their presentation varies depending on their anatomical location and systemic inflammatory manifestations. The management is based on tumour location, feasibility of surgical resection, the course of disease and ALK expression. Treatment with ALK inhibitors has shown promising results. The findings in our series are similar to those reported in the previous literature. We contribute information on a tumour located in the ribcage, a site for which the available data is scarce.

References

- Camela F, Gallucci M, di Palma E, Cazzato S, Lima M, Ricci G, et al. Pulmonary inflammatory myofibroblastic tumor in children: a case report and brief review of literature. *Front Pediatr*. 2018;6:35.
- Liu L, Kong X, Lu X, Cao D. Pediatric endobronchial inflammatory myofibroblastic tumor: a case report and review of the literature. *Clin Pract*. 2016;6:853.
- Cantera J, Alfaro M, Rafart D, Zalazar R, Muruzabal M, Barquín P, et al. Inflammatory myofibroblastic tumours: a pictorial review. *Insights Imaging*. 2014;6:85–96.
- Coffin C, Hornick J, Fletcher C. Inflammatory myofibroblastic tumor. *Am J Surg Pathol*. 2007;31:509–20.
- Vargas-Madueno F, Gould E, Valor R, Ngo N, Zhang L, Villalona-Calero M. EML4-ALK rearrangement and its therapeutic implications in inflammatory myofibroblastic tumors. *Oncologist*. 2018;23:1127–32.
- Brivio E, Zwaan C. ALK inhibition in two emblematic cases of pediatric inflammatory myofibroblastic tumor: efficacy and side effects. *Pediatr Blood Cancer*. 2019;66:e27645.

Gorka Martínez Navarro^{a,*}, María Pérez Chamorro^a, Diana Veiga Canuto^b, Antonio Juan Ribelles^a, José María Fernández Navarro^a

^a Sección de Oncología y Hematología Infantil, Hospital Universitari i Politècnic La Fe, Valencia, Spain

^b Servicio de Radiodiagnóstico, Hospital Universitari i Politècnic La Fe, Valencia, Spain

* Corresponding author.

E-mail address: martinez_gor@gva.es (G. Martínez Navarro).

<https://doi.org/10.1016/j.anpede.2020.12.016>
2341-2879/ © 2021 Published by Elsevier España, S.L.U. on behalf of Asociación Española de Pediatría. This is an open access article under the CC BY-NC-ND license (<http://creativecommons.org/licenses/by-nc-nd/4.0/>).

Current content of infant cereals and possible alternatives: Not everything counts in childhood nutrition^{☆,☆☆}



Contenido actual de los cereales para lactantes y posibles alternativas: no todo vale en nutrición infantil

Dear Editor:

In recent years, an abundance of information has spread in social media suggesting that infants should not be fed baby cereal (BC) products on account of their high free sugar content and their sweet taste.¹ Proposed alternatives include corn starch, semolina, oatmeal or brown rice.

The advantages of introducing BC products in complementary feeding are their texture and the contribution of fibre, energy, iron and zinc, mainly. The disadvantages are the free sugar content and sweet taste of these products.²

The Sociedad Española de Gastroenterología, Hepatología y Nutrición Pediátrica (Spanish Society of Paediatric Gastroenterology, Hepatology and Nutrition, SEGHP)³ recommends that the intake of free sugars until age 2 years amount to less than 5% of the total energy intake (TEI). Since consumption of fruit juice in the first year of life is currently discouraged, BC are the main source of free sugars in the infant's diet.

In 2018, we reviewed the nutrient composition of 98 BC brands sold in Spain. Assuming a mean energy intake of 750 kcal/day in the second semester of life based on current recommendations, consumption of 25 g a day of BC would correspond to an intake of free sugars exceeding 5% of the TEI in 1 brand, or 5 brands in case of consumption of 30 g per day. The contribution of fibre of BC would amount to 1.2–1.5 g per day. In 2020, we reviewed 110 brands of BC and found an overall decrease in sugar content (the percentage of products with 5 or fewer grams of sugar per 100 g of product went from 18.3% to 30.9%) and an increase in the fibre content (45.4% compared to the previous 40.8%).⁴ At present, daily consumption of 25 or 30 g of BC of any commercial brand does not contribute more than 5% of the TEI in the form of free sugars.

On the other hand, an excessive protein intake in the first months of life can predispose to future obesity. For this reason, several regional governments and paediatric societies in Spain, such as the Asociación Española de Pediatría de Atención Primaria (AEPap),⁵ recommend an intake of high biological value protein (HBVP) in complementary feeding of 20–40 g. Daily consumption of 500 mL of stage 2 formula and 20–40 g of meat or fish contribute 2.2–7.2 mg of iron

[☆] Please cite this article as: Vitoria Miñana I. Contenido actual de los cereales para lactantes y posibles alternativas: no todo vale en nutrición infantil. *An Pediatr (Barc)*. 2021;95:366–367.

^{☆☆} Previous presentation: partial results of this study were presented at the XXVI Congress of the Sociedad Española de Gastroenterología, Hepatología y Nutrición Pediátrica, May 16–18, 2019, Santander, Spain.