

to 40% of paediatricians³ and 25% of paediatric emergency physicians.⁵ The low prevalence found in our study may be explained by different factors: on one hand, our sample was younger compared to other studies, and on the other we defined burnout as an altered score in all three scales (other authors considered an altered score in any scale sufficient to consider the syndrome to be present).^{1,5,6}

The risk factors for developing burnout syndrome are working full time in the emergency department and having an exclusively clinical role. Protective factors described in the previous literature (that were not assessed in our study) were continuing education of health care professionals, work-life balance, teamwork and specific personality traits.^{2,6}

Lastly, some authors have suggested that burnout should be perceived as a manifestation of a dysfunctional health care system, and that measures should be taken at the individual and collective level. Given the current professional trend of exclusive, specialised dedication to emergency care, protective strategies must be developed to prevent job burnout: strategies aimed at improving care pathways, reducing the burden of bureaucratic tasks, avoiding long work days and facilitating the wellbeing, work-life balance and personal development of emergency care staff.^{2,3,5,6}

Acknowledgments

We thank the administrators and health care staff that have participated in the study from the following hospitals: Carles Luaces Cubells (Hospital Sant Joan de Déu), Sebastián González Peris (Hospital Universitari Vall d'Hebron), Neus Pociello (Hospital Universitari Arnau in Vilanova de Lleida), Eva Botifoll García (Hospital Sant Joan de Déu in Manresa), Abel Marínez Mejías (Consorci Sanitari de Terrassa), Toni de Francisco (Hospital Universitari Germans Trias i Pujol), Xavier Codina Puig (Hospital General de Granollers), Sandra Moya Villanueva (Hospital Parc Taulí of Sabadell), Ester Castellarnau Figueras (Hospital Universitari de Tarragona Joan XXIII), Montse Gispert-Saüch (Hospital Universitari Doctor Josep Trueta), Elisabet Coca Fernández (Hospital de

la Santa Creu i Sant Pau), Fernando David Panzino (Hospital General del Parc Sanitari Sant Joan de Déu), Matilde Viñas Viña (Hospital Universitari Dexeus), Amaia Bilbao Garitagoitia (Parc de Salut Mar), Pablo Ercoli (Fundació Sant Hospital La Seu d'Urgell), Hospital de Santa Caterina and Clínica Sant Josep.

References

1. Arora M, Asha S, Chinnappa J, Diwan AD. Review article: burnout in emergency medicine physicians. *Emerg Med Australas.* 2013;25:491–5.
2. Gorelick MH, Schremmer R, Ruch-Ross H, Radabaugh C, Selbst S. Current workforce characteristics and burnout in pediatric emergency medicine. *Acad Emerg Med.* 2016;23:48–54.
3. Shanafelt TD, Boone S, Tan L, Dyrbye LN, Sotile W, Satele D, et al. Burnout and satisfaction with work-life balance among US physicians relative to the general US population. *Arch Intern Med.* 2012;172:1377–85.
4. Cañadas-de la Fuente GA, San Luis C, Manuel Lozano L, Vargas C, García I, de la Fuente EI. Evidencia de validez factorial del Maslach Burnout Inventory y estudio de los niveles de burnout en profesionales sanitarios. *Rev Latinoam Psicol.* 2014;46:44–52.
5. Patterson J, Gardner A. Burnout Rates in Pediatric Emergency Medicine Physicians. *Pediatr Emerg Care.* 2017, <http://dx.doi.org/10.1097/PEC.0000000000001379>.
6. Estry-Behar M, Doppia MA, Guetarni K, Fry C, Mchet G, Pelloux P, et al. Emergency physicians accumulate more stress factors than other physicians—results from the French SESMAT study. *Emerg Med J.* 2011;28:397–410.

Cristina Parra Cotanda*, Victoria Trenchs Sainz de la Maza, Carles Luaces Cubells

Servicio de Urgencias, Hospital Sant Joan de Déu, Esplugues de Llobregat, Barcelona, Spain

* Corresponding author.

E-mail address: cparra@sjdhospitalbarcelona.org (C. Parra Cotanda).

18 June 2019 17 September 2019

2341-2879/ © 2020 Published by Elsevier España, S.L.U. on behalf of Asociación Española de Pediatría. This is an open access article under the CC BY-NC-ND license (<http://creativecommons.org/licenses/by-nc-nd/4.0/>).

COVID-19 respiratory failure: ECMO support for children and young adult patients[☆]



Insuficiencia respiratoria COVID-19: soporte con ECMO para niños y adultos jóvenes

To the Editor:

Severe acute respiratory syndrome coronavirus 2 (SARS-CoV-2) affects adults predominantly, with the greatest number of admissions to the intensive care unit (ICU) and highest

mortality found in this age group.¹ Although coronavirus disease 2019 (COVID-19) in children has been described as being less severe with a shorter recovery time,² we present the case of a female patient aged 16 years, previously healthy and with no known contacts with COVID-19, that suffered severe pneumonia due to infection by SARS-CoV-2 requiring veno-venous extracorporeal membrane oxygenation (ECMO) and experienced a full recovery.

The patient presented to the emergency department of the regional hospital in her area with cough and fever of 6 days' duration. The chest radiograph evinced pneumonia (Fig. 1A), which prompted admission to the inpatient ward. At 48 h, the PCR test for detection of SARS-CoV-2 turned out positive, so prescriptions were made for ritonavir/Lopinavir (for up to 7 days), hydroxychloroquine (for up to 10 days), azithromycin (for up to 5 days) and interferon β -1b (for up to 7 days). On the same day, the condition of the patient worsened, as she developed tachycardia, tachypnoea, dyspnoea,

[☆] Please cite this article as: Gimeno-Costa R, Barrios M, Heredia T, García C, Hevia Ld. Insuficiencia respiratoria COVID-19: soporte con ECMO para niños y adultos jóvenes. *An Pediatr (Barc).* 2020;93:202–205.

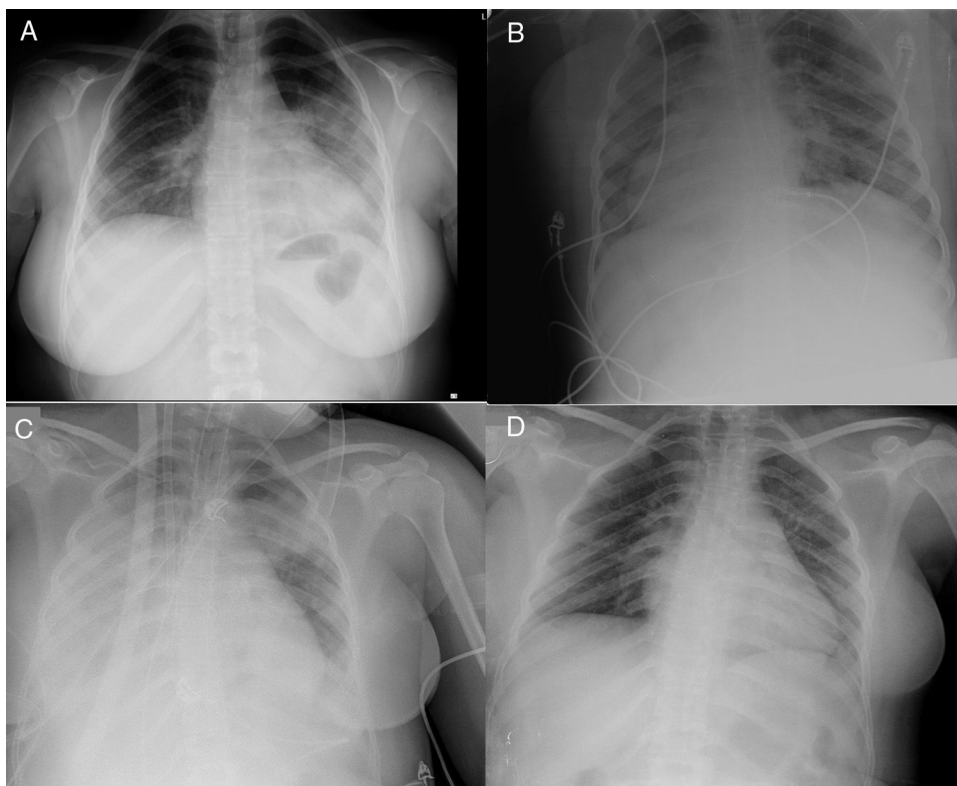


Figure 1 Plain chest radiograph. A) Chest radiograph in emergency department of the regional hospital B) Chest radiograph at admission in ICU of regional hospital (prone position). C) Chest department at admission to ICU after transfer to referral hospital (day 0 of ECMO). D) Chest radiograph in inpatient ward of referral hospital (discharge day).

fever (39.9°C) and her oxygen saturation (SaO_2) dropped to 90% (4L/min of supplemental oxygen). The patient was transferred to the ICU and immediately required orotracheal intubation and invasive mechanical ventilation (Fig. 1B). In the 72 h that followed, the patient was managed with neuromuscular blocking agents, a positive end-expiratory pressure (PEEP) of 12–14 cmH_2O , inhaled nitric oxide and ventilation in the prone position (2 sessions). After 4 days in the PICU, the partial pressure of oxygen (PaO_2) and the PaO_2 /fraction of inspired oxygen (FiO_2) worsened (the latter dropped to 70 mmHg for 6 h), which prompted activation of the mobile ECMO team of the tertiary care referral hospital in our autonomous community. The patient was connected to a portable ECMO system (Cardiohelp®, Maquet Cardiopulmonary AG, Hirrlingen, Germany) with a femoral-jugular veno-venous configuration (Fig. 1C): 21 F multistage drainage cannula and 19 F return cannula.

After connection to the ECMO system, the patient was transferred to the ICU of the referral hospital. On arrival, she had a heart rate of 77 bpm and a blood pressure of 131/61 mmHg with administration of noradrenaline at a dose of $0.1 \mu\text{g}/\text{kg}/\text{minute}$. She received ventilation with a tidal volume of 3 mL/kg of body weight, a FiO_2 of 50% and a PEEP of 14 cmH_2O . The initial ECMO blood flow was 4.2 L/min with a FiO_2 of 100% (with a sweep of 4 L/min). The salient findings were lymphopaenia, marked elevation of interleukin 6, C-reactive protein, ferritin and D-dimer levels, and a negative troponin test (Table 1). At admission in the ICU of our referral hospital, we initiated treatment with tocilizumab (initial

dose of 600 mg followed by 400 mg/12 h after), methylprednisolone (1 mg/kg/24 h, 3 doses) and switched antiviral treatment to remdesivir (initial dose of 200 mg followed by 100 mg/24 h for 4 days).

The patient responded favourably. The levels of pro-inflammatory cytokines went down and pulmonary function improved: increase in the $\text{PaO}_2:\text{FiO}_2$ ratio and improvement in dynamic compliance with a lower PEEP (Table 1). After 180 h, it became possible to discontinue ECMO and extubate the patient. After 8 days in the ICU and 7 in the inpatient ward of the referral hospital, the patient was discharged home without need of supplemental oxygen and was able to walk unassisted (negative PCR test for SARS-CoV-2) (Fig. 1D).

Extracorporeal membrane oxygenation should be considered salvage therapy in cases refractory to conventional mechanical ventilation, ventilation in the prone position and/or recruitment manoeuvres.³ The frequency of ECMO utilization during the COVID-19 pandemic has been of 0.5%–1% of all hospitalised patients. In Europe, as of May 7, 2020, 1068 adult patients have required support with ECMO.⁴ Although cases of pneumonia due to SARS-CoV-2 have been reported in infants⁵, children⁶ and young adults,¹ these patients have generally had good outcomes and rarely required extracorporeal life support. Our patient developed severe pneumonia refractory to standard therapy and required ECMO. The European Survey of Neonatal/Paediatric COVID-19 Patients in ECMO includes few patients, including ours.⁴ Adult patients with COVID-19 need between 20 and 50 days of ECMO to recover. In the case of our patient,

Table 1 Laboratory data. Ventilation and ECMO settings.

	Reference	ECMO day 0	ECMO day 1	ECMO day 2	ECMO day 3	ECMO day 4	ECMO day 5	ECMO day 6	ECMO day 7	ECMO day 8	Post-ECMO
Haemoglobin (g/dL)	12–14.5	9.2	8.1	8.5	8.6	9.1	9	9.4	8.8	9	9.2
Leucocytes ($\times 10^3/\text{mm}^3$)	3.5–10.5	8.88	5.84	5.91	5.34	8.31	10.73	17.94	15.56	15.95	4.81
Neutrophils ($\times 10^3/\text{mm}^3$)	1.8–8.0	7.11	4.06	5.90	3.46	5.5	7.23	14.21	11.47	12.50	11.78
Lymphocytes ($\times 10^3/\text{mm}^3$)	1.5–7.0	0.77	1.12	1.51	1.20	1.45	2.18	2.09	1.52	2.00	2.18
Platelets ($\times 10^3/\text{mm}^3$)	150–400	202	192	244	283	377	309	329	207	162	179
Albumin (g/dL)	3.9–4.9	2.4	2.1	2.3	2.3	2.7	2.9	3.2	3	3.2	3.9
Sodium (mmol/L)	135–150	143	143	141	138	138	135	138	137	141	141
Potassium (mmol/L)	3.5–5.5	3.7	3.9	4.2	4.3	4.2	4.8	4.6	4.4	4.2	4.2
Ionised calcium (mg/dL)	4.3–5.2	4.6	4.8	4.6	4.7	4.7	4.7	4.7	4.8	4.9	
Glucose (mg/dL)	76–110	109	99	79	130	103	92	98	99	95	79
ALT (U/L)	5–35	23	25	32	38	61	53	51	45	44	41
LDH (U/L)	135–214	361	345	379	373	471	441	609	557	518	288
Urea (mg/dL)	10–50	15	14	23	24	21	25	31	37		
Creatinine (mg/dL)	0.26–0.77	0.39	0.33	0.35	0.4	0.4	0.49	0.45	0.41	0.47	0.53
Arterial lactate (mmol/L)	0.3–1.6	0.9	0.7	0.6	0.7	0.5	0.6	0.7	0.4	0.5	
C-reactive Protein (mg/L)	0–5	192.9	178.6	98.6	40.8	22.8	12	8.7	6.4	6	1.9
Interleukin-6 (pg/mL)	0–100	125.9		782.9	273.6			216.7		148.8	42.3
Ferritin (ng/mL)	15–150				283						70
Procalcitonin (ng/mL)	0–0.5	0.74		0.46	0.27	0.19	0.12	0.1	0.06	0.04	0.03
Fibrinogen (mg/dL)	170–437			700		520	396	321	235	179	221
D-dimer (ng/mL)	20–500	1275	1136	1751		3386 ^a	13 391 ^a	23 563 ^a	25 415 ^a	32 355 ^a	1374
Antithrombin III (%)	80–130				87			106			
pCO ₂ (mmol/L)		55	41.8	46	46.5	46.8	44.7	46.7	47.8	42.8	
Ventilator FiO ₂ (%)		100	60	30	30	30	30	30	40	35	
PaO ₂ :FiO ₂		67	133	230	233	226	219	232	406	600	
PEEP (cmH ₂ O)		14	12	15	12	12	12	10	8	5	
Dynamic compliance (mL/cmH ₂ O)		15	24	10	14	21	25	34	41	45	
ECMO blood flow (L/min)		4	4.2	4	4	3.7	3.6	3.3	3	2.5	
Sweep gas flow (L/min)		3.5	4	4	4.5	4	3.9	2.5	2	2	
ECMO FiO ₂ (%)		100	70	100	100	100	90	80	60	30	
Tidal volume (mL/kg)		4.02	4.25	3.47	3.28	3.58	3.46	3.6	4.44		

^a Probably due to thrombus formation in the ECMO membrane.

7 days of ECMO sufficed to maintain oxygenation and allowed delivery of ultra-protective ventilation until the inflammatory response abated. We did not detect any adverse effects of the combination of antiviral and anti-inflammatory treatments used in the patient. We also did not need to adjust the usual dosage, so we surmise that there were no pharmacokinetic alterations associated with the use of the circuit or the extracorporeal membrane.

Many articles published during the current pandemic describe the course of disease in patients that remain in the ICU (even under ECMO). Ours is the first case of a paediatric patient managed with veno-venous ECMO that has fully recovered and been discharged home free of sequelae. In this case, extracorporeal life support proved safe (including an interhospital transfer), so it can be contemplated as an option in children and adolescents for management of COVID-19 if their condition requires such support.

References

1. Guan WJ, Ni ZY, Hu Y, Liang W, Ou C, He L, et al. Clinical Characteristics of Coronavirus Disease 2019 in China. *N Engl J Med*. 2020;382:1708–20.
2. Lu X, Zhang L, Du H, Zhang J, Li YY, Qu J, et al. SARS-CoV-2 Infection in Children. *N Engl J Med*. 2020;382:1663–5.
3. Ramanathan K, Antognini D, Combes A, Paden M, Zakhary B, Ogino M, et al. Planning and provision of ECMO services for severe ARDS during the COVID-19 pandemic and other outbreaks of emerging infectious diseases. *Lancet Respir Med*. 2020. Mar 20. [online ahead of print].
4. EURO ELSO. European Survey on ECMO in COVID-19 pts at 7/05/20. Available in: <https://www.euroelso.net/covid-19/covid-19-survey/>. Accessed at 10 de mayo de 2020.
5. Alonso Díaz C, López Maestro M, Moral Pumarega MT, Flores Antón B, Pallás Alonso CR. Primer caso de infección neonatal por SARS-CoV-2 en España. *An Pediatr (Barc)*. 2020;92:237–8.
6. Ong JSM, Tosoni A, Kim Y, Kissoon N, Murthy S. Coronavirus Disease 2019 in critically ill children: a narrative review of the literature. *Pediatr Crit Care Med*. 2020. Apr 7. [online ahead of print].

Ricardo Gimeno-Costa^{a,*}, Marcos Barrios^a,
Tomás Heredia^b, Carmen García^c, Luis de Hevia^a

^a *Área de Medicina Intensiva, Hospital Universitari i Politècnic la Fe, Valencia, Spain*

^b *Servicio de Cirugía Cardíaca, Hospital Universitari i Politècnic la Fe, Valencia, Spain*

^c *Servicio de Medicina Intensiva, Hospital de La Ribera, Alzira, Spain*

* Corresponding author.

E-mail address: gimeno_ric@gva.es (R. Gimeno-Costa).

18 May 2020 31 May 2020

2341-2879/ © 2020 Asociación Española de Pediatría. Published by Elsevier España, S.L.U. This is an open access article under the CC BY-NC-ND license (<http://creativecommons.org/licenses/by-nc-nd/4.0/>).