

Table 1 Clinical and laboratory data of very preterm newborns with a discharge diagnosis of congenital hypothyroidism detected by neonatal screening.

Case/sex	1/F	2/M	3/M
GA (weeks)	26	29	27
BW (g)	580	840	1150
TSH-48 h (mIU/mL)	7.3	2.3	3.5
TSH-15 days (mIU/mL)	1.7	6.1	1.6
TSH-discharge (mIU/mL)	487 (90 days)	234 (60 days)	91.1 (67 days)
Free T ₄ (ng/dL)	0.21	0.23	0.31
Thyroid scintigraphy	NA	TGIS	TGIS

BW, birth weight; F, female; GA, gestational age; M, male; NA, not available; TGIS, thyroid gland in situ; TSH, thyroid stimulating hormone; T₄, thyroxine.

References

- Kaluarachchi DC, Allen DB, Eickhoff JC, Dawe SJ, Baker MW. Increased congenital hypothyroidism detection in preterm infants with serial newborn screening. *J Pediatr*. 2018;31691–3, pii: S0022-3476.
- Léger J, Olivieri A, Donaldson M, Torresani T, Krude H, van Vliet G, et al. European Society for Paediatric Endocrinology consensus guidelines on screening, diagnosis, and management of congenital hypothyroidism. *J Clin Endocrinol Metab*. 2014;99:363–84.
- Woo HC, Lizarda A, Tucker R, Mitchel ML, Vohr B, Oh W, et al. Congenital hypothyroidism with a delayed thyroid stimulating hormone elevation in very premature infants: Incidence and growth and developmental outcomes. *J Pediatr*. 2011;158:538–42.
- LaFranchi SH. Screening preterm infants for congenital hypothyroidism: better the second time around. *J Pediatr*. 2014;164:1259–61.
- Kaluarachchi DC, Colaizy TT, Pesce LM, Tansey M, Klein JM. Congenital hypothyroidism with delayed thyroid-stimulating hormone elevation in premature infants born at less than 30 weeks gestation. *J Perinatol*. 2017;37:277–82.
- Osborn DA, Hunt RW. Prophylactic postnatal thyroid hormones for prevention of morbidity and mortality in preterm infants. *Cochrane Database Syst Rev*. 2007. CD005948.

Raquel Yahyaoui^{a,b,*}, Rocío Jiménez-Machado^a, Juan Pedro López Sigüero^{b,c}

^a *Laboratorio de Metabopatías, Hospital Regional Universitario de Málaga, Málaga, Spain*

^b *Instituto de Investigación Biomédica de Málaga (IBIMA), Málaga, Spain*

^c *Sección de Endocrinología Pediátrica, Hospital Regional Universitario de Málaga, Málaga, Spain*

*Corresponding author.

E-mail address: raquelyahyaoui@gmail.com (R. Yahyaoui).

<https://doi.org/10.1016/j.anpede.2019.01.019>

2341-2879/ © 2019 Asociación Española de Pediatría. Published by Elsevier España, S.L.U. This is an open access article under the CC BY-NC-ND license (<http://creativecommons.org/licenses/by-nc-nd/4.0/>).

Atrial fibrillation. A presentation of 2 cases[☆]



Fibrilación auricular. A propósito de 2 casos

Dear Editor:

Atrial fibrillation (AF) is an exceptional arrhythmia in the pediatric age group in the absence of complex congenital heart defects or previous cardiac surgery. We present 2 cases of paroxysmal AF in childhood, both in patients without a known history of cardiac disease, triggered by intense physical activity and that responded well to treatment. We also reviewed the literature on this disease in the pediatric age group.

Case 1 corresponded to a male adolescent aged 14 years that presented to the emergency department with palpita-

tions and a sensation of difficulty breathing with onset a few hours prior after performance of physical activity (martial arts, a sport with a high static component and a moderate dynamic component). He had no medical history of interest and was not receiving any ongoing pharmacological treatment. The father had idiopathic AF.

Several diagnostic tests were performed, among which the most relevant was an electrocardiogram (ECG) that showed an irregular rhythm with narrow QRS complexes and a heart rate of 80 beats per minute with multiple low-amplitude F-waves, compatible with AF (Fig. 1). The arterial blood pressure was 122/71 mmHg. The body mass index (BMI) was under the 95th percentile. The results of blood chemistry tests were normal, with no abnormalities in electrolyte levels and negative results of drug testing in urine; thyroid hormone levels were normal. A Doppler ultrasound scan ruled out structural heart defects, revealing normal atria and ventricular function both in systole and diastole and absence of intracardiac thrombi. The scan detected the presence of persistent left superior vena cava with moderate dilatation of the coronary sinus, which was confirmed by a saline contrast study performed by injection of shaken physiological saline in the left cephalic vein.

[☆] Please cite this article as: Roguera Sopena M, Sabidó Sánchez L, Villuendas Sabaté R, del Alcázar Muñoz R. Fibrilación auricular. A propósito de 2 casos. *Arch Bronconeumol*. 2020;92:47–49.

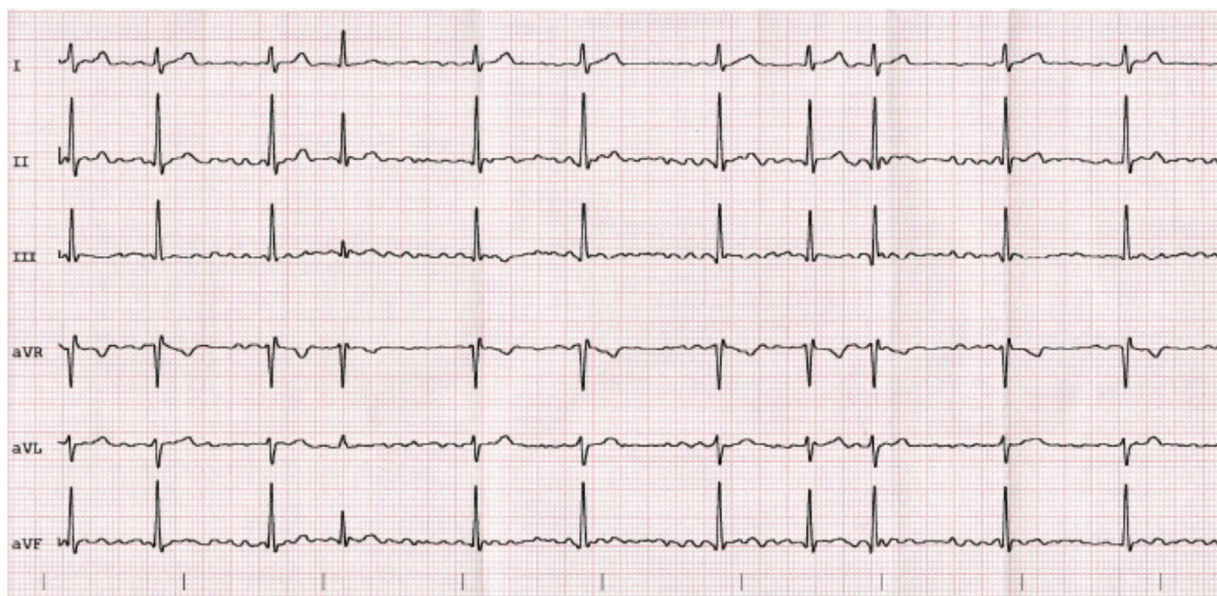


Figure 1 Electrocardiogram of case 1.

The patient was given a dose of oral flecainide (2.5 mg/kg), which achieved restoration of the sinus rhythm. This was followed by initiation of maintenance therapy with flecainide.

At 12 months of follow-up the patient had experienced no recurrences, and the antiarrhythmic drug therapy was discontinued. A subsequent cardiac stress test revealed a normal heart rhythm and blood pressure, both at peak exertion and during recovery, with no associated vagal symptoms. The patient remained asymptomatic 9 months later.

Case 2 corresponded to a male adolescent aged 17 years referred to the emergency department due to syncope following exertion (bodybuilding a sport with a high static component and a moderate dynamic component) that exhibited complete neurologic recovery in a few seconds with immediate development of palpitations and the sensation of tachycardia. The patient was put under observation with performance of a full ECG, which revealed atrial fibrillation

with ventricular contractions occurring at 110–120 beats per minute (Fig. 2).

The patient was given an oral dose of 2.5 mg/kg of flecainide, which achieved restoration of the sinus rhythm.

The physical examination revealed a mild systolic ejection murmur best heard over the aortic valve. The BMI was below the 95th percentile. The Doppler ultrasound scan revealed a bicuspid aortic valve with two raphe of mild severity, a disorder that had not been diagnosed previously. The atria had normal morphology and were not enlarged. There was no evidence of thrombi in the heart.

The patient had no personal or family history of interest and was not undergoing chronic pharmacological treatment. The urine drug test was negative and the levels of serum electrolytes and thyroid hormones were normal.

The patient remained under pharmacological treatment with flecainide for 12 months, without recurrence of arrhythmia at 5 months of follow-up.

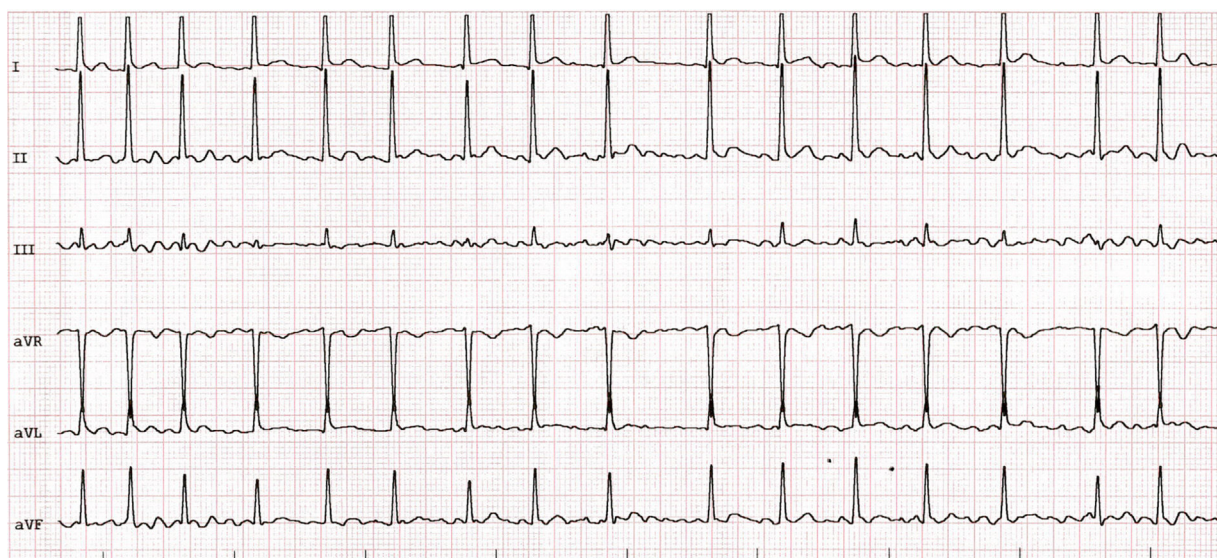


Figure 2 Electrocardiogram of case 2.

Isolated atrial fibrillation is an infrequent arrhythmia in the pediatric population, especially in the absence of organic heart disease of a probably multifactorial etiology. Both of the cases we present here corresponded to a first episode of AF that was haemodynamically insignificant in patients with no known history of heart disease.

Persistent left superior vena cava, diagnosed in case 1, has been associated with the development of supraventricular arrhythmias, including AF. Radiofrequency catheter ablation of these connections can prevent their recurrence. Hsu et al. described 5 cases of AF where electrophysiology testing identified persistent left superior vena cava as the source arrhythmia.^{1,2}

To our knowledge, an association between AF and bicuspid aortic valve, a defect detected in case 2, has not been previously reported, and therefore the coexistence of these 2 disorders could be coincidental and unrelated to the disease process.

Intense physical activity may cause electrical and structural changes in the atria that would promote the development of an episode of AF. In both our patients, AF was associated with physical activity. There is also evidence of an association between chest trauma with commotio cordis and AF.³

Cases of isolated familial AF have been reported in the literature in association with genetic mutations affecting multiple ion channels and circulating hormones such as atrial natriuretic peptide. However, the diagnostic yield of genetic testing for this type of arrhythmia is currently not known.^{4,5} In this regard, the presence of idiopathic AF in the father of case 1 may have increased the risk of AF in our patient. In addition, consumption of some recreational substances, such as cannabis, can trigger AF. In the cases presented here, we ruled out the consumption of arrhythmogenic substance use.

In a series of 1750 cases of isolated AF in children, the only risk factors identified were obesity with a BMI above the 95th percentile, male sex and age greater than 14 years.⁶

At present there is no consensus regarding the first-line antiarrhythmic drug for treatment of AF in the pediatric age group. However, drugs used to control heart rate (such as beta blockers) are the most widely used agents. In the 2 cases presented here, treatment with flecainide was chosen

with the aim of achieving cardioversion. In cases refractory to pharmacotherapy, electrical cardioversion and radiofrequency ablation of the sources of atrial arrhythmia are effective alternatives.⁶

Lastly, the use of anticoagulant therapy was ruled out in both cases due to the low risk of thrombosis and the early recovery of the sinus rhythm. In any case, there are no guidelines providing the indication of prophylactic treatment for prevention of stroke in this population.

References

1. Hsu LF, Jais P, Keane D, Wharton JM, Deisenhofer I, Hocini M, et al. Atrial fibrillation originating from persistent left superior vena cava. *Circulation*. 2004;109:828–32.
2. Ozcan EE, Szeplaki G, Merkely B, Geller L. Isolation of persistent left superior vena cava during atrial fibrillation ablation. *Indian Pacing Electrophysiol J*. 2015;15:130–2.
3. Ota K, Bratincsak A. Atrial fibrillation induced by commotio cordis secondary to a blunt chest trauma in a teenage boy. *Pediatrics*. 2015;135:e199.
4. Oyen N, Ranthe MF, Carstensen L, Boyd HA, Olesen MS, Olesen SP, et al. Familial aggregation of lone atrial fibrillation in young persons. *J Am Coll Cardiol*. 2012;60:917–21.
5. Roberts JD, Gollob MH. Impact of genetic discoveries on the classification of lone atrial fibrillation. *J Am Coll Cardiol*. 2010;55:705–12.
6. El-Assaad I, al-Kindi SG, Saarel EV, Aziz PF. Lone pediatric atrial fibrillation in the United States: analysis of over 1500 cases. *Pediatr Cardiol*. 2017;38:1004–9.

Marc Roguera Sopena*, Laura Sabidó Sánchez, Roger Villuendas Sabaté, Ricardo del Alcázar Muñoz

Hospital Germans Trias i Pujol, Badalona, Barcelona, Spain

*Corresponding author.

E-mail address: mruguera.germanstrias@gencat.cat (M. Roguera Sopena).

<https://doi.org/10.1016/j.anpede.2019.01.018>
2341-2879/ © 2019 Asociación Española de Pediatría. Published by Elsevier España, S.L.U. This is an open access article under the CC BY-NC-ND license (<http://creativecommons.org/licenses/by-nc-nd/4.0/>).

Mesenteric lymphatic malformation: A rare cause of an acute abdomen[☆]



Malformación linfática mesentérica: una causa poco frecuente de abdomen agudo

Dear Editor:

Mesenteric lymphatic malformations, also known as lymphangiomas or cystic hygromas, are rare lesions originating from the proliferation of lymphatic vessels in the mesentery.¹ They mainly affect children aged less than

5 years and the most frequent location are the head, neck and axillary region, with intraabdominal locations accounting for less than 1–5% of cases.^{1–4} The clinical presentation varies depending on the size and location of the lesion from the absence of symptoms to acute abdomen (abdominal pain, abdominal distension, signs of peritoneal irritation).^{4,5} Although recent articles have described management with percutaneous sclerotherapy,¹ the first-line treatment continues to be complete surgical resection.^{3,4} In this article, we describe the approach to the diagnosis and treatment of 2 cases of mesenteric lymphatic malformation managed in our unit.

Case A

Boy aged 3 years with an unremarkable previous history that sought care in the emergency department for diffuse

[☆] Please cite this article as: Merino-Mateo L, Morante Valverde R, Redondo Sedano JV, Benavent Gordo MI, Gómez Fraile A. Malformación linfática mesentérica: una causa poco frecuente de abdomen agudo. *Arch Bronconeumol*. 2020;92:49–51.