

tive compared to its use against *Neisseria gonorrhoeae*. In addition, the risk of neonatal ophthalmia due to *C. trachomatis* is currently greater compared to the risk due to *N. gonorrhoeae*, as the former is more prevalent in pregnant women.^{3,5} For all the above reasons, the health authorities in some countries recommend screening pregnant women (which requires definition of the target population based on the prevalence of infection by age groups) and treating those infected, while the usefulness of neonatal prophylaxis remains under debate.^{1,3,6} Screening during pregnancy would allow the prevention of complications in the mother (pelvic inflammatory disease, sterility, etc.) and reduce the burden of disease in newborns, as maternal infection would be controlled before delivery.

In conclusion, based on our findings, we estimate that at least 1 in 1000 newborns in Spain acquires a *C. trachomatis* infection during birth, despite the routine implementation of ocular prophylaxis in newborns.

Funding

This study was partially funded by a grant from the Fondo de Investigación Sanitaria (FIS PI10/02191).

References

1. Workowski KA, Bolan GA, Centers for Disease Control and Prevention. Sexually transmitted diseases treatment guidelines, 2015. *MMWR Recomm Rep*. 2015;64:1–137.
2. Martins J, Ribeiro Luís C, Correia de Aguiar T, Garrote Marcos JM, João Rocha Brito M. *Chlamydia trachomatis* infection in the first year of life. *An Pediatr (Barc)*. 2011;74:298–302.
3. Piñero L, Lekuona A, Cilla G, Lasa I, Martínez-Gallardo LP, Korta J, et al. Prevalence of *Chlamydia trachomatis* infection in parturient women in Gipuzkoa, Northern Spain. *Springerplus*. 2016;5:566.
4. Hammerschlag MR, Cummings C, Roblin PM, Williams TH, Delke I. Efficacy of neonatal ocular prophylaxis for the prevention of chlamydial and gonococcal conjunctivitis. *N Engl J Med*. 1989;320:769–72.
5. Peuchant O, Le Roy C, Desveaux C, Paris A, Asselineau J, Maldonado C, et al. Screening for *Chlamydia trachomatis*, *Neisseria gonorrhoeae*, and *Mycoplasma genitalium* should it be integrated into routine pregnancy care in French young pregnant women? *Diagn Microbiol Infect Dis*. 2015;82:14–9.
6. Hammerschlag MR, Smith-Norowitz T, Kohlhoff SA. Keeping an eye on *Chlamydia* and *Gonorrhea* conjunctivitis in infants in the United States, 2010–2015. *Sex Transm Dis*. 2017;44:577.

Luis Piñero^{a,*}, Javier Korta-Murua^{b,d},
Sheila López-Cuesta^b, Izaskun Lasa^c, Gustavo Cilla^a

^a Servicio de Microbiología, Hospital Universitario Donostia-Instituto BioDonostia, San Sebastián, Guipúzcoa, Spain

^b Servicio de Pediatría, Hospital Universitario Donostia-Instituto BioDonostia, San Sebastián, Guipúzcoa, Spain

^c Servicio de Ginecología, Hospital Universitario Donostia-Instituto BioDonostia, San Sebastián, Guipúzcoa, Spain

^d Departamento de Pediatría, Facultad de Medicina, EHU-UPV, San Sebastián, Guipúzcoa, Spain

* Corresponding author.

E-mail address: luisdario.pineirovazquez@osakidetza.eus (L. Piñero).

2341-2879/

© 2018 Asociación Española de Pediatría. Published by Elsevier España, S.L.U. This is an open access article under the CC BY-NC-ND license (<http://creativecommons.org/licenses/by-nc-nd/4.0/>).

Diagnosis of three cases of thyroid cancer in one year[☆]



Diagnóstico de 3 casos de cáncer de tiroides en un año

Dear Editor:

Although thyroid cancer is the most frequent malignancy of the endocrine system, it is very rare in children. Ninety percent of paediatric cases correspond to differentiated thyroid cancers (DTCs). Secondary thyroid cancer is the most frequent type in children previously treated with head and neck irradiation. The Spanish Registry of Child Tumours (Registro Español de Tumores Infantiles, RETI-SEHOP) reported an incidence of 3–4 cases per 10⁶ children

in the 1980–2013 period, similar to the incidence reported by the International Agency for Research on Cancer (ACCIS) in Europe. The Registry also described an increase in the annual incidence that has also been observed in the United States.¹ Thyroid cancer in children usually presents as a nodule in the thyroid or regional lymphadenopathy. Compared to adults, the disease tends to be more advanced at the time of diagnosis, with metastases in regional cervical lymph nodes and distant metastatic disease (lungs), and a greater rate of recurrence.² Traditionally, treatment has consisted of total thyroidectomy, excision of local and regional metastases, administration of radioactive iodine (I¹³¹) and thyroid-stimulating hormone (TSH) suppression, which achieved high cure rates. However, long-term longitudinal studies have revealed an increased mortality in survivors due to secondary cancers in patients that received radiation therapy.³ Due to the low incidence of this cancer, trials have not been conducted to optimise treatment, which is based on data from retrospective studies and, more recently, in the 2015 guidelines of the American Thyroid Association (ATA).⁴

We present the cases of 3 patients with a diagnosis of differentiated papillary thyroid cancer in 2011. The patients presented with a thyroid nodule or cervical

[☆] Please cite this article as: Villalba Castaño C, Carcavilla Urquí A, Aragónés Gallego Á, Sastre Marcos J, Morlan López MÁ. Diagnóstico de 3 casos de cáncer de tiroides en un año. *An Pediatr (Barc)*. 2019;90:397–399.

Table 1 Current outcomes in patients, 6 years after diagnosis.

Patient	1	2	3
Current chronological age in years	14.13	17.66	21.79
Chronological age at diagnosis in years	8.16	11	14.64
Sex	Female	Female	Male
Cumulative I ¹³¹ dose	600 mCi	450 mCi	360 mCi
Last WBS post I ¹³¹	Diffuse bilateral lung involvement bilateral	Diffuse bilateral lung involvement and cervical lymphadenopathy of indeterminate nature	No uptake
Stimulated Tg (normal range, 10–85 ng/mL)	21.8 ng/mL	6.65 ng/mL	17.2 ng/mL
Anti-Tg Abs (normal range, 10–115 IU/mL)	>500 IU/mL	>500 IU/mL	<20 IU/mL
Staging in last followup	AJCC 2 (T4a N1b M1)	AJCC 2 (T3a N1b M1)	AJCC 2 (T1a N1b M1)
Molecular testing	BRAF negative TERT negative	BRAF negative TERT negative	BRAF negative RET-PTC 1 positive TERT negative
Hypoparathyroidism	No	No	Yes
Comments	TSH suppression Watchful waiting	TSH suppression Monitoring of cervical lymphadenopathy Watchful waiting	TSH suppression Persistent disease, not localised, possibly cervical

Staging: AJCC/UICC II.

Anti-Tg Abs, antithyroglobulin antibodies; Tg, thyroglobulin (tested after suspending levothyroxine); WBS, whole body scan after treatment with radioactive iodine.

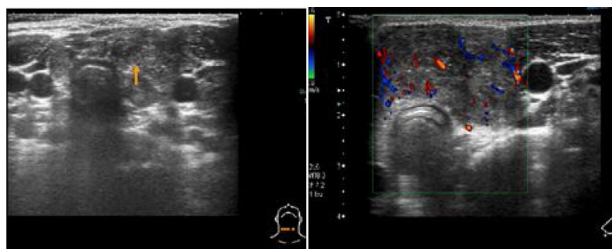


Figure 1 Patient 1. Ultrasound findings indicative of malignancy: solid nodule in left lobe and isthmus of the thyroid (0.18 × 0.37 × 0.4 mm), heterogeneous, hypoechoic, with poorly defined margins and microcalcifications. Doppler ultrasound scan revealing increased intranodular blood flow.

lymphadenopathy. None had relevant risk factors or a family history of DTC. The assessment included a cervical ultrasound examination that found signs of malignancy (Fig. 1). The findings of fine needle aspiration biopsy (FNAB) of the lesions was compatible with papillary thyroid cancer with lymph node involvement in all 3 cases. The results of blood tests were normal. The patients underwent a total thyroidectomy with lymph node dissection (central and lateral). This was followed by initiation of TSH suppression with levothyroxine. All patients experienced hypoparathyroidism as an immediate complication of surgery. Later on, having suspended treatment with levothyroxine, they underwent ablation of the thyroid remnant with I¹³¹, with the dose calculated based on body weight (50–120 mCi). The first whole-body scan revealed metastases in the lung and extensive lymph node involvement (AJCC/UICC 2 T3-4a N1b M1, ATA Pediatrics High Risk), and the patients required between 3 and 6 doses. One patient had a recurrence in the form of a malignant contralateral lymph node, which was removed after diagnosis by means of

ultrasound and measurement of thyroglobulin in a FNAB specimen. The follow-up included stimulated thyroglobulin testing, measurement of antithyroglobulin antibodies, scintigraphy, positron-emission tomography or computed tomography scans and cervical ultrasound examinations. Two patients continue to have residual disease in the lungs (Table 1).

The diagnosis of 3 cases of DTC in one year is unusual in our region (population aged 0–14 years in Castilla-La Mancha in 2010–2013 period, 326 958). This could be related to the increased incidence described worldwide, which does not seem to be attributable solely to advances in diagnostic techniques. In our hospital, there have been no new cases since, so it is possible that this cluster was the product of chance. The increased predisposition to thyroid carcinogenesis in childhood and adolescence suggests a possible link to exposure to ionising radiation or chemicals early in life.¹ We did not identify any risk factors in our patients. As described in the literature, the combination of ultrasound examination and FNAB offered a high diagnostic yield. The histological examination of thyroid tissue obtained by means of FNAB is a well-established method for diagnosis of thyroid nodules in adults due to its high accuracy, but this approach is not widely accepted in the paediatrics field, where surgery is in some cases the initial intervention.² The new guidelines of the ATA recommend this approach, basing the management on the clinical presentation and ultrasound findings rather than the size of the nodule, and reserving surgery as first-line treatment for hyperfunctioning nodules or nodules with indeterminate histological findings.⁴ The recommended surgical approach, which was applied in our patients, is total or partial thyroidectomy with central lymph node dissection and selective dissection of lateral lymph nodes. This aggressive approach is associated with a higher incidence of complications and should be performed in specialised facilities. In the cases presented here, the patients developed

hypoparathyroidism after surgery, and one had Horner syndrome after surgical resection of a recurrence in the lymph nodes. The high incidence of complications could have been due to the extension of the surgery and the younger age of the patients. Our patients received different doses of I^{131} based on disease extension. There is no consensus on the use of radiotherapy in children, and at present it is recommended in cases with local, regional or distant residual disease or involving iodine-avid tissues, planning the treatment on a case-to-case bases if more than 1 dose is needed due to the risk of long-term complications.⁵ Despite the updated guidelines for management published by the ATA, further research is necessary to optimise treatment.

References

1. Bonachi L, Frazier AL, Laurinavicius F, Braga K, Rodríguez-Galindo C. Increase in the incidence of differentiated thyroid carcinoma in children adolescents, and young adults: a population-based study. *J Pediatr*. 2014;164:1481–5.
2. Avram AM, Shulkin BL. Thyroid cancer in children. *J Nucl Med*. 2014;55:705–7.
3. Brown AP, Chen J, Hitchcock YJ, Szabo A, Shrieve DD, Tward JD. The risk of second primary malignancies up to 3 decades after the treatment of differentiated thyroid cancer. *J Clin Endocrinol Metab*. 2008;93:504–15.
4. Francis GL, Wagnerspack SG, Bauer AJ, Angelos P, Benvenga S, Cerutti JM, et al. Management guidelines for children with thyroid nodules and differentiated thyroid cancer. The American Thyroid Association Guidelines Task Force on Pediatric Thyroid Cancer. *Thyroid*. 2015;25:716–59.
5. Kim HY, Gelfand MJ, Sharp SE. SPECT/CT imaging in children with papillary thyroid carcinoma. *Pediatr Radiol*. 2011;41:1008–12.

Clara Villalba Castaño^{a,*}, Atilano Carcavilla Urquí^b, Ángel Aragonés Gallego^c, Julia Sastre Marcos^d, Miguel Ángel Morlan López^e

^a *Servicio de Pediatría, Hospital General de Villalba, Collado Villalba, Madrid, Spain*

^b *Servicio de Endocrinología Pediátrica, Hospital Infantil La Paz, Madrid, Spain*

^c *Servicio de Pediatría, Complejo Hospitalario Universitario de Toledo, Toledo, Spain*

^d *Servicio de Endocrinología y Nutrición, Complejo Hospitalario Universitario de Toledo, Toledo, Spain*

^e *Servicio de Cirugía General, Complejo Hospitalario Universitario de Toledo, Toledo, Spain*

* Corresponding author.

E-mail address: clrvillalba@gmail.com (C. Villalba Castaño). 2341-2879/

© 2018 Asociación Española de Pediatría. Published by Elsevier España, S.L.U. This is an open access article under the CC BY-NC-ND license (<http://creativecommons.org/licenses/by-nc-nd/4.0/>).