

## SCIENTIFIC LETTERS

## ***Actinotignum* induced balanopostitis in children. A literature review and a case report**<sup>☆</sup>



### **Balanopostitis por *Actinotignum* en niños. Revisión bibliográfica y presentación de un caso**

Dear Editor:

*Actinotignum schaalii* (*A. schaalii*, formerly known as *Actinobaculum schaalii*) is a facultative-anaerobic gram-positive bacillus that was first described in 1997. The *Actinotignum* genus includes 2 other species: *Actinotignum urinale* and *Actinotignum sanguinis*. *A. schaalii* is the species most frequently associated with infection in humans,<sup>1</sup> especially urinary tract infections (UTIs), with 172 cases described through October 2016, 6 of them in paediatric patients (ages 0 to 15 years). Although most of the cases of infection by *A. schaalii* described to date in the literature have occurred in adult patients, the paediatric population seems to be susceptible as well. We present the first case in which *A. schaalii* was isolated in a paediatric patient with balanopostitis, who was managed in the outpatient paediatric emergency department of the Hospital Universitario San Cecilio of Granada, Spain.

The patient was a boy aged 7 years that presented in the emergency department with inflammation of the penis that had become apparent that day. He did not have urinary symptoms or systemic manifestations. The most relevant finding of the history taking was that the patient had spent the weekend at the beach. He also had a history of phimosis and balanopreputial adhesions treated with topical corticosteroids at age 5 years. He was correctly vaccinated and had no other personal or family history of interest. The physical examination revealed inflammation and erythema in the glans, foreskin and shaft of the penis, with pain on retracting the foreskin and appearance on manipulation of an abundant yellow-green purulent exudate. The rest of the physical examination was unremarkable. A sample of the exudate was collected for microbiological testing, and the

patient was treated with a rinse with physiological saline followed by application of bacitracin, neomycin and polymyxin B cream. The discharge diagnosis was balanitis, and the prescribed treatment consisted of rinses with physiological saline and topical application of mupirocin cream. Three days after discharge, the patient had a follow-up appointment at his primary care clinic, with evidence of significant clinical improvement, and was instructed to continue with the current treatment until completing a total of 7 days. The PCR tests of the balanopreputial exudate were negative for *Chlamydia trachomatis*, *Neisseria gonorrhoeae*, *Mycoplasma* spp. and *Ureaplasma* spp. At 48 h, culture on blood agar plates with elevated CO<sub>2</sub> had produced very small colonies (<1 mm) (Fig. 1) of a gram-positive, slightly curved rod with features compatible with the corynebacteria, slow-growing, non-haemolytic and oxidase and catalase negative. The bacterium was identified by means of MALDI-TOF mass spectrometry as *A. schaalii* (score, 2.4). The results of the antibiogram and estimated minimum inhibitory concentrations (mg/L) were: sensitivity to vancomycin (0.25), ampicillin (0.016), amoxicillin-clavulanic acid (0.016) and cefotaxime (0.016), and resistance to clindamycin (>256).

*A. schaalii* is a bacterium whose natural habitat is not well known, although it can be part of the microbiota in the genitourinary tract.<sup>1</sup> It is suspected that it is an underdiagnosed cause of genitourinary infections, partly due to technical difficulties in its isolation, as it grows weakly in culture in room air and its identification sometimes requires the use of molecular methods.<sup>2</sup> This bacterium is usually associated with UTIs in older adults with underlying diseases of the kidney or urinary system, and it has also been described in association with endocarditis, osteomyelitis and soft-tissue infections.<sup>1</sup> Infection by *A. schaalii* has been associated with the increased moisture that results from the use of diapers in children and from incontinence in older adults, a factor that may promote colonization by this bacterium and lead to a higher incidence of UTIs.<sup>3</sup>

To date, 7 cases of infection by this bacterium in the paediatric age group have been reported (Table 1),<sup>3–6</sup> of which 5 corresponded to UTIs, 1 to an intradural abscess and the last one to the case presented here. Five of these patients had a history of urogenital disease and 4 had risk factors such as use of diapers, enuresis or, in the case we present here, wetness due to prolonged wearing of swimming trunks. *A. schaalii* is an emerging uropathogen whose presence should be considered in paediatrics, especially in children aged less

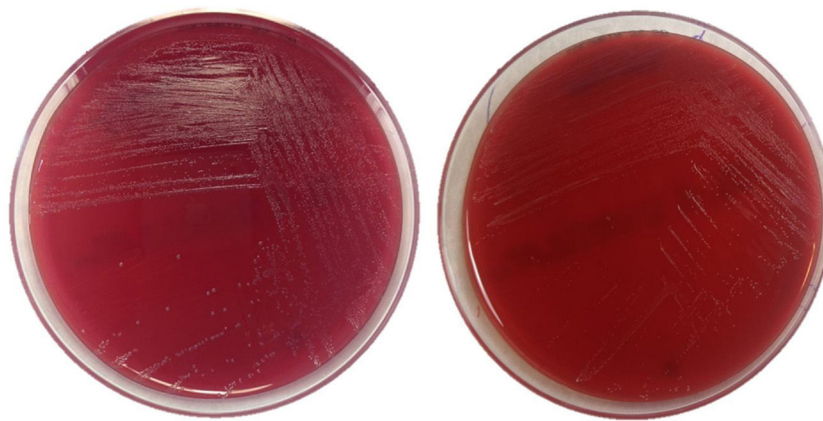
<sup>☆</sup> Please cite this article as: Ruiz-García C, Muñoz-Hoyos A, Lara-Oya A, Navarro-Marí JM, Gutiérrez-Fernández J. Balanopostitis por *Actinotignum* en niños. Revisión bibliográfica y presentación de un caso. An Pediatr (Barc). 2018;89:246–248.

**Table 1** Infections by *Actinotignum schaalii* in paediatric patients.

Case no.	Age	Sex	Clinical presentation	Specimen	Concomitant microbiota	Urogenital problems	Other predisposing conditions	Treatment	Reference
1	5 years	Male	Pyelonephritis	Urine	No	Ureteropelvic junction obstruction	Congenital left hemiplegia, epilepsy	Amoxicillin-clavulanic acid (2 days) followed by vancomycin (14 days)	Pajkrt et al. <sup>5</sup>
2	9 months	Female	Cauda equina syndrome	Intradural abscess fluid	Non-haemolytic <i>Streptococcus</i>	No	Syringomyelia, use of diapers	Surgical drainage, penicillin, metronidazole	Reinhard et al. <sup>6</sup>
3	3 years	Female	Cystitis	Urine	<i>Klebsiella pneumoniae</i>	No	Recurrent UTIs, use of diapers	Cotrimoxazole (7 days) followed by amoxicillin (10 days)	Andersen et al. <sup>3</sup>
4	13 years	Male	Cystitis. Reinfection at 1 year	Urine	No	Neurogenic bladder	Enuresis	Pivampicillin (20 days) followed by mecillinam (10 days) followed by pivampicillin (14 days)	
5	8 months	Male	Cystitis	Urine	No	Neurogenic bladder	Myelomeningocele, use of diapers	Cotrimoxazole (7 days) followed by amoxicillin (14 days)	Zimmermann et al. <sup>4</sup>
6	15 years	Male	Cystitis	Urine	No	Neurogenic bladder, vesicoureteral reflux, bladder diverticulum	Myelomeningocele, paraplegia	Amoxicillin-clavulanic acid (7 days)	<sup>a</sup>
7	7 years	Male	Balanoposthitis	Balanopreputial exudate	No	Phimosis, balanopreputial adhesions	Wetness, swimming trunks	Topical mupirocin (7 days)	Case presented in this article

<sup>a</sup> Personal communication, Dr Reto Lienhard, microbiologist at the Laboratoire de Référence Borrelia (ADMED Microbiologie) in La-Chaux-de-Fonds, France.

Table adapted from Zimmermann et al.<sup>4</sup>



**Figure 1** Picture of *Actinotignum schaalii* colonies in culture media. Growth in blood agar after 48 of culture under anaerobic conditions (left) and aerobic conditions (right).

than 4 years with kidney or urinary system diseases, who use diapers or who have enuresis or other conditions that lead to increased moisture in the genital area, and specifically in cases of suspected UTI with negative results of routine cultures.<sup>3,4</sup> This organism should also be considered as a possible aetiological agent in balanopreputial infections. It is important to remember that *A. schaalii* is usually resistant to fluoroquinolones and cotrimoxazole, the latter of which is commonly used for UTI treatment and prophylaxis in paediatric practice. At present, the recommended treatment for a known or suspected infection by *A. schaalii* is amoxicillin or a cephalosporin.<sup>6</sup> In infections of the glans or foreskin, topical treatment with mupirocin may suffice, although further research is required to determine the prognosis, associated complications and appropriate treatment of infections by *A. schaalii*.

## References

1. Lotte R, Lotte L, Ruimy R. *Actinotignum schaalii* (formerly *Actinobaculum schaalii*): a newly recognized pathogen – a review of the literature. *Clin Microbiol Infect.* 2016;22:28–36.
2. Lara-Oya A, Navarro-Marí JM, Gutiérrez-Fernández J. *Actinotignum schaalii* (previamente denominado *Actinobaculum schaalii*): una nueva causa de balanitis. *Med Clin (Barc).* 2016;147:131–2.
3. Andersen LB, Bank S, Hertz B, Søby KM, Prag J. *Actinobaculum schaalii*, a cause of urinary tract infections in children? *Acta Paediatr Oslo Nor.* 2012;101:e232–4.
4. Zimmermann P, Berlinger L, Liniger B, Grunt S, Agyeman P, Ritz N. *Actinobaculum schaalii*: an emerging pediatric pathogen? *BMC Infect Dis.* 2012;12:201.
5. Pajkrt D, Simmons-Smit AM, Savelkoul PH, van den Hoek J, Hack WW, van Furth AM. Pyelonephritis caused by *Actinobaculum schaalii* in a child with pyeloureteral junction obstruction. *Eur J Clin Microbiol Infect Dis.* 2003;53:679–82.
6. Reinhard M, Prag J, Kemp M, Andresen K, Klemmensen B, Højlyng N, et al. Ten cases of *Actinobaculum schaalii* infection: clinical relevance, bacterial identification, and antibiotic susceptibility. *J Clin Microbiol.* 2005;43:5305–8.

Carlos Ruiz-García<sup>a</sup>, Antonio Muñoz-Hoyos<sup>a,b</sup>, Ana Lara-Oya<sup>c</sup>, José María Navarro-Marí<sup>c</sup>, José Gutiérrez-Fernández<sup>c,d,\*</sup>

<sup>a</sup> Unidad de Gestión Clínica de Pediatría y Neonatología, Hospital Universitario Clínico San Cecilio, Instituto de Investigación Biosanitaria de Granada, Granada, Spain

<sup>b</sup> Departamento de Pediatría, Facultad de Medicina, Universidad de Granada, Instituto de Investigación Biosanitaria de Granada, Granada, Spain

<sup>c</sup> Laboratorio de Microbiología, Hospital Virgen de las Nieves, Instituto de Investigación Biosanitaria de Granada, Granada, Spain

<sup>d</sup> Departamento de Microbiología, Facultad de Medicina, Universidad de Granada, Instituto de Investigación Biosanitaria de Granada, Granada, Spain

\* Corresponding author.

E-mail address: josegf@go.ugr.es (J. Gutiérrez-Fernández). 2341-2879/

© 2017 Asociación Española de Pediatría. Published by Elsevier España, S.L.U. This is an open access article under the CC BY-NC-ND license (<http://creativecommons.org/licenses/by-nc-nd/4.0/>).