



IMAGES IN PAEDIATRICS

Dermoid cyst of the auricle

Quiste dermoide del pabellón auricular

Elena Dina^{a,*}, Àngels Martínez Arias^a, Carmen María Blázquez Mañá^b^a Servicio Otorrinolaringología, Hospital Universitario Parc Taulí, Barcelona, Spain^b Servicio Anatomía Patológica, Hospital Universitario Parc Taulí, Barcelona, Spain

Available online 5 April 2024

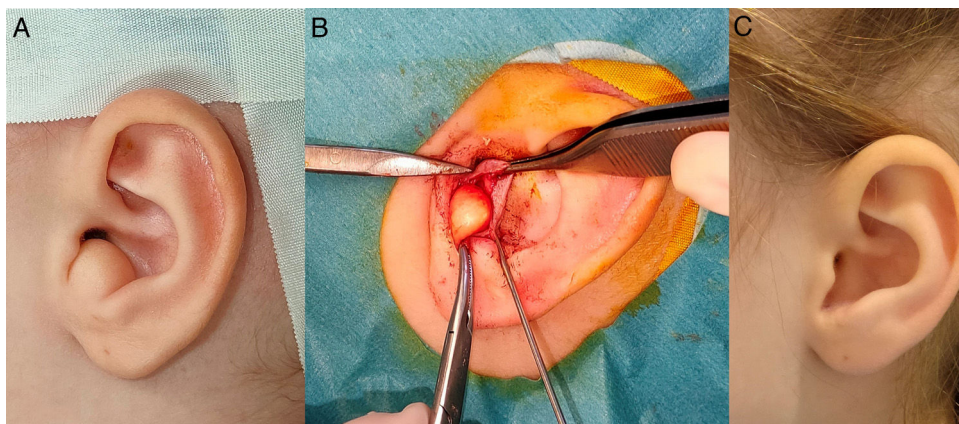


Figure 1 (A) Dermoid cyst in the left ear lobe. (B) Intraoperative image. (C) Outcome at 2 years.

A girl aged 2 years with no history of interest presented with an elastic painless mass measuring 2 cm in diameter at the level of the concha in the left ear lobe, with normal appearance of the skin (Fig. 1A) that had been growing progressively in the past 7 months. The otoscope exam was normal in both ears.

The management was surgical, with complete resection of the lesion, which turned out to be an encapsulated cystic structure (Fig. 1B). In two years of follow-up, there have been no signs of recurrence, and the cosmetic outcome has been excellent (Fig. 1C).

The findings of the histological examination were consistent with dermoid cyst (Fig. 2A and B), of two sections stained with haematoxylin and eosin, one revealed a cystic lesion filled with anucleate keratin fragments, and the other a pilosebaceous unit in the cyst wall.

DOI of original article: <https://doi.org/10.1016/j.anpedi.2022.01.006>

* Corresponding author.

E-mail address: elena.dina@gmail.com (E. Dina).

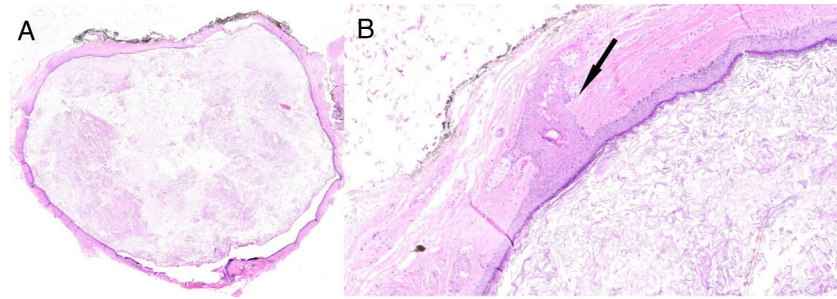


Figure 2 Two sections stained with haematoxylin and eosin showing (A) a cystic lesion filled with anucleate keratin fragments ($\times 2.5$ magnification) and (B) a pilosebaceous unit in the cyst wall, (arrow) ($\times 15$ magnification).

Dermoid cysts are benign congenital tumours that develop in the early years of life, 70% of which are diagnosed by age 5 years. Histologically, they feature a capsule of keratinised squamous epithelium containing fragments of keratin and skin adnexa. Seven percent are found in the head and neck (80% at the orbital/periorbital level). Ear involvement is rare, with fewer than 30 cases described in the literature, most at the base or behind the ear, and exceptionally in the ear lobe.^{1–3}

The differential diagnosis mainly includes epithelial cysts, which are more frequent in the ear lobe and external ear and have the same macroscopic appearance. They can be congenital or acquired and only contain keratin.³ The

management is always surgical due to the risk of malignant transformation.¹

References

1. Horikiri M, Ueda K, Kato M. Dermoid cyst of the auricle: a rare manifestation. *BMJ Case Rep.* 2014;2014:bcr2014205826.
2. Choi JS, Bae YC, Lee JW, Kang GB. Dermoid cysts: Epidemiology and diagnostic approach based on clinical experiences. *Arch Plast Surg.* 2018;45:512–6.
3. Jung K, Choi HJ, Nam DH. Characteristic of the Dermoid Cyst of the Auricle. *Arch Craniofac Surg.* 2014;15:22–7.