

IMAGES IN PAEDIATRICS

It's not all ingrowing nail: Childhood retronychia

No todo es uña encarnada: retroniquia en la infancia



Cristina Nogueroles Blanco^{a,*}, Sara Fuentes Carretero^b, Carme Grande Moreillo^b,
Jaume Margarit Mallol^b

^a Servicio de Pediatría, Hospital Universitari Mútua, Terrassa, Barcelona, Spain

^b Servicio de Cirugía Pediátrica, Hospital Universitari MútuaTerrassa, Terrassa, Barcelona, Spain

Available online 14 March 2024

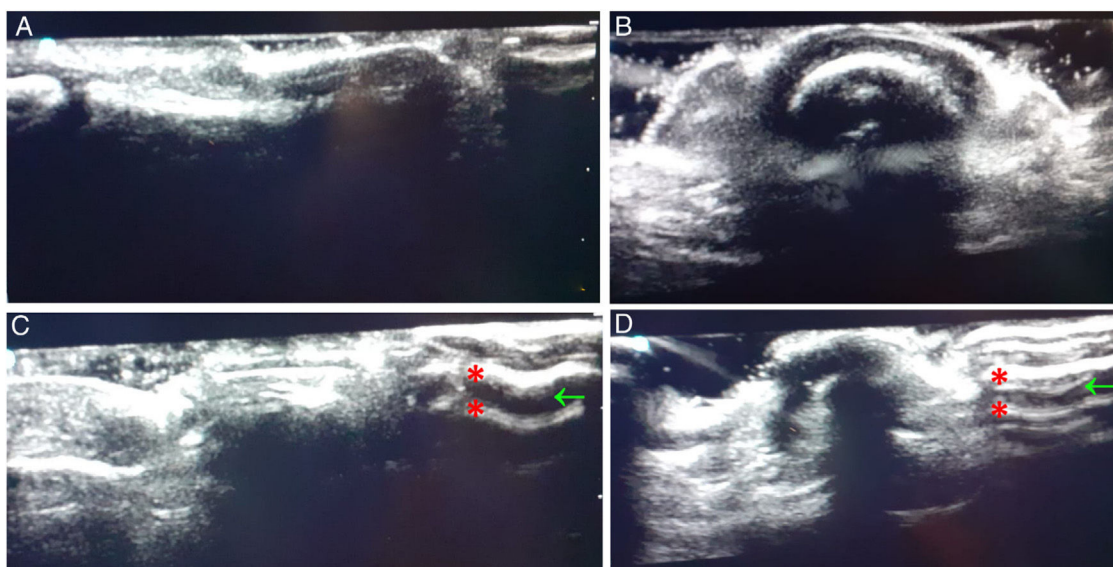


Figure 1 Comparison of ultrasound appearance of the first two toes. Longitudinal (A) and transversal (B) views of the healthy nail compared to the longitudinal (C) and transversal (D) nail involved in retronychia. We can see two superimposed nail plates (*), characteristic of retronychia, with a hypoechoic space in between (arrow).

Retronychia is an infrequent disease in children and adolescents that is associated with the combination of 3 factors: disruption of the nail plate's growth, misalignment of the nail matrix and the nail plate and poor adhesion of the old plate to the nail bed.^{1,2} The pressure of the nail against the

proximal nail fold causes pain and inflammation, and the repeated disruption of the growth of the nail matrix leads to the stacking of successively generated nail plates. It is usu-

DOI of original article: <https://doi.org/10.1016/j.anpede.2022.08.004>

* Corresponding author.

E-mail address: cnogueroles@mutuaterrassa.cat (C. Nogueroles Blanco).

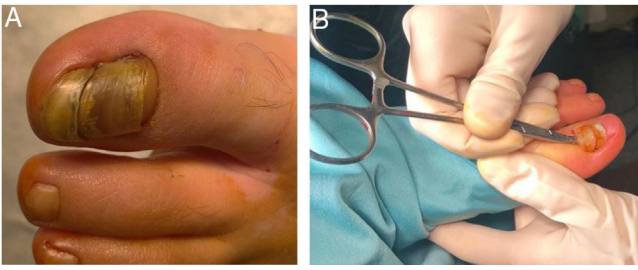


Figure 2 (A) Preoperative appearance of the affected nail. Proximal elevation of the nail with periungual erythema. (B) Surgical management with total proximal nail avulsion.

ally triggered by trauma or local injury, although it can also develop spontaneously.³ It is diagnosed based on the clinical findings, although ultrasound imaging can be used as a non-invasive confirmatory test.^{2,3} The definitive treatment is surgical, through proximal avulsion of the nail, removing the old nail plate and the underlying ingrown plates.³

We describe a series of 4 patients that received a diagnosis of retronychia after developing pain and erythema in the first toe with proximal rising of the nail, confirmed in the ultrasound examination by the visualization of multiple nail plates, among other findings (Fig. 1). After initial treatment with empiric antibiotherapy, all patients underwent definitive treatment with surgery, with total proximal avulsion of the nail (Fig. 2), which achieved a cure.

References

1. Diniz Borges Figueira de Mello C, Da Rocha e Souza M, Fonseca Noriega L, Di Chiacchio N. Retronychia. *An Bras Dermatol*. 2018;93:707–11.
2. Litaïem N, Drissi H, Zeglaoui F, Kchachemoune A. Retronychia of the toenails: a review with emphasis on pathogenesis, new diagnostic and management trends. *Arch Dermatol Res*. 2019;311:505–12.
3. Au AS, Leung WY, Tran D. Retronychia: a literature review. *J Am Podiatr Med Assoc*. 2020;110:1–6.