



IMAGES IN PAEDIATRICS

Unusual suprasternal mass

Masa supraesternal inusual



Ignacio Aldana Villamañán^a, María Aldana Villamañán^b, Javier González Llorente^c,
Javier Aldana Gómez^{d,*}

^a Hospital Clínico Universitario de Valladolid, Valladolid, Spain

^b Hospital Universitario, Torrejón de Ardoz, Madrid, Spain

^c Servicio de Radiología, Hospital Recoletas, Segovia, Spain

^d Servicio de Pediatría, Hospital Recoletas, Segovia, Spain

Received 10 February 2023; accepted 20 March 2023

Available online 9 September 2023

A girl aged 5 years presented with a suprasternal mass that appeared on crying starting 10 days prior, which had not been observed before, with no associated symptoms or previous history of disease.

In the physical examination, the Valsalva manoeuvre revealed a noncompressible suprasternal mass measuring 5 × 4 cm that disappeared at the end of the manoeuvre (Figs. 1 and 2, Appendix B, Video in supplemental material).

Cervical masses require early and accurate diagnosis because they may be signs of severe disease.¹ This case is atypical and rare, as the mass appeared intermittently in the context of increasing intrathoracic pressure. This narrowed down the potential diagnoses²: apical lung herniation (compressible, crepitus), laryngocoele (adults, possible stridor or dyspnoea), jugular phlebectasia (compressible and usually lateral) and thymic herniation (suprasternal, more frequent between ages 3 and 5 years, when the thymus is largest, not compressible, silent on auscultation).

Sonography is the gold standard for imaging and usually sufficient.^{2,3} In this case, the ultrasound examination detected superior herniation of the thymus (Fig. 3). This quick and safe diagnosis made other procedures involving radiation, biopsy or surgery unnecessary.^{2,3}

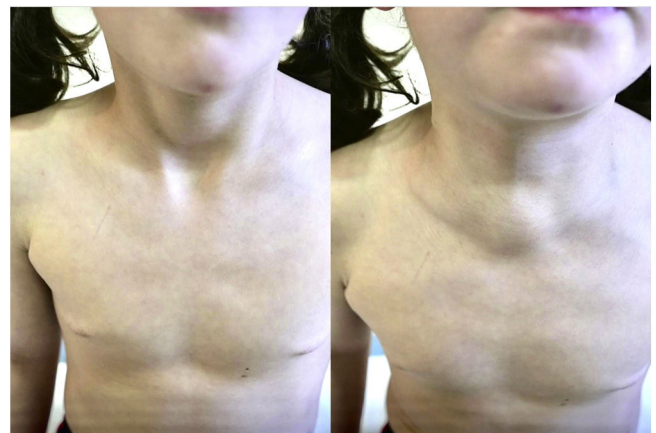

Figure 1 Frontal view. Left: no evidence of a suprasternal mass with the patient at rest. Right: appearance of a suprasternal mass with performance of the Valsalva manoeuvre, which did not cause pain, aphonia, dysphagia or dyspnoea.

Since the patient was asymptomatic and this type of herniation tends to resolve as the size of the thymus decreases, there was no need for surgical resection or any other treatment.

DOI of original article: <https://doi.org/10.1016/j.anpedi.2023.03.007>

* Corresponding author.

E-mail address: jaldanag@hotmail.com (J. Aldana Gómez).

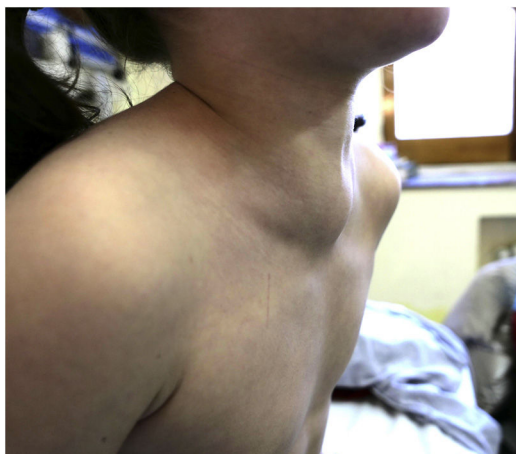

Figure 2 Lateral view of the suprasternal mass during the Valsalva manoeuvre. The mass was not compressible, there was no crepitus and was silent on auscultation.

Appendix A. Supplementary data

Supplementary material related to this article can be found, in the online version, at doi:<https://doi.org/10.1016/j.anpedi.2023.03.007>.

References

1. Loreto Álvarez S, Carolina Sepúlveda R, Aníbal Espinoza G, Matías Gómez G. Timo cervical aberrante: masa cervical pediátrica inusual, revisión bibliográfica y reporte de un caso. *Rev Otorinolaringol Cir Cabeza Cuello*. 2020;80:69–74.
2. Choo Su S, Hess T, Whybourne A, Chang AB. Intermittent mid-line suprasternal neck mass caused by superior herniation of the thymus. *J Paediatr Child Health*. 2015;51:344–6.
3. McDougall CM, Culham G, Seear MD, Chilvers MA. Superior herniation of the mediastinum presenting as an anterior neck mass on straining. *Pediatric Pulmonol*. 2012;47:710–7.

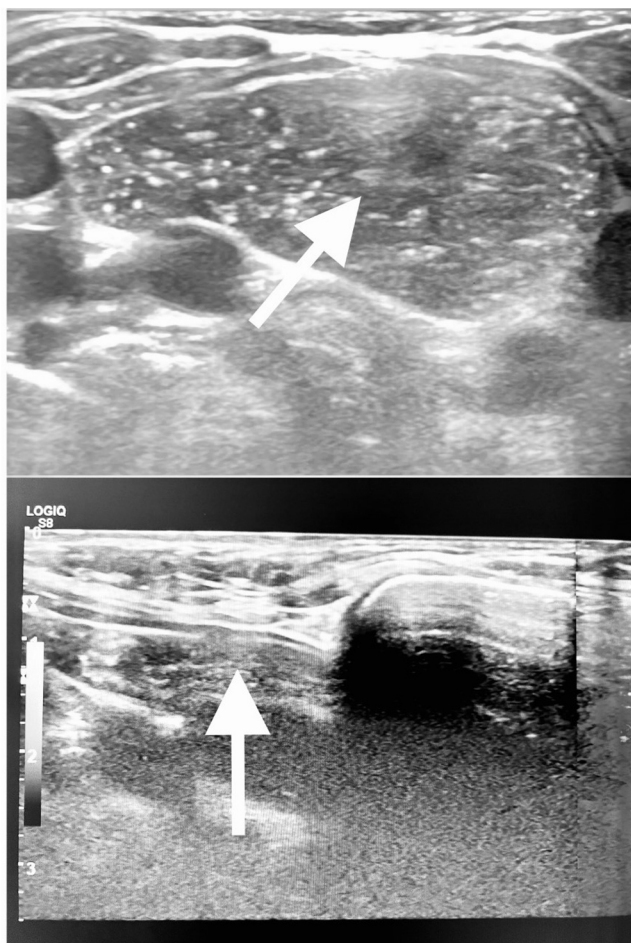


Figure 3 Ultrasound image of the suprasternal region during the Valsalva manoeuvre. Top: axial plane. Bottom: sagittal plane. Both show thymic tissue with normal sonographic characteristics with suprasternal herniation (white arrows).