



## IMAGES IN PAEDIATRICS

**Meconium plug syndrome in twins****Síndrome del tapón meconial en gemelos**

**Alejandro Pérez-Muñuzuri\***, Natalia Mandiá-Rodríguez,  
Carolina López-Sanguos, Olalla López-Suárez



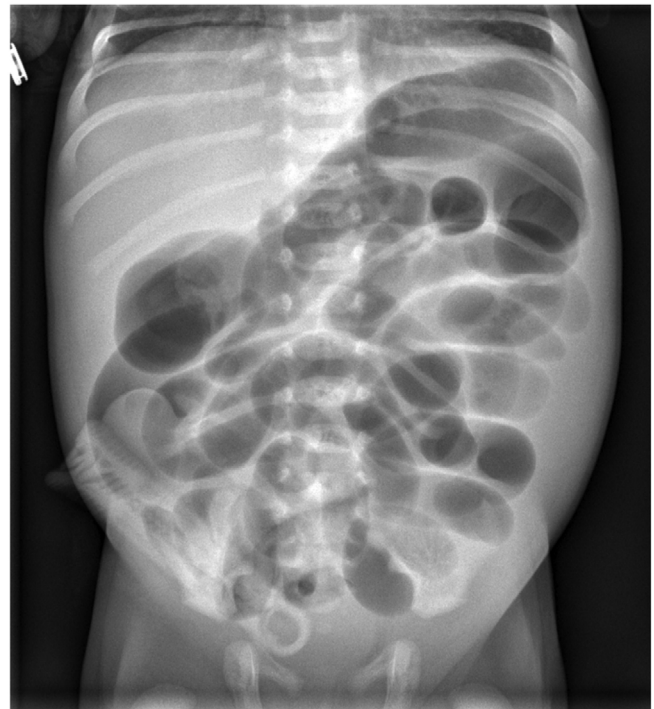
*Department of Neonatology, Hospital Clínico Universitario de Santiago de Compostela, Universidad de Santiago de Compostela, Santiago de Compostela, A Coruña, Spain*

Received 22 March 2022; accepted 22 April 2022

Available online 13 March 2023

Meconium plug syndrome is a cause of large intestine obstruction, characterised by delay of meconium passage past the first 24 h post birth due to a thickened, rubbery meconium that settles in the shape of the colon, completely obstructing its lumen. Its thickening seems to result from the immaturity of intestinal peristalsis, which makes the meconium stay longer than normal in the colon, giving rise to the change in consistency. This is a frequent condition in infants born preterm, to mothers with gestational diabetes or exposed to magnesium sulphate before birth.<sup>1,2</sup>

We present the case of a pair of monozygotic twins born to term (37<sup>+1</sup> weeks) with birth weights of 2300 and 2490 g, with no relevant history. They were admitted to hospital at 27 h post birth due to delayed passage of meconium, significant abdominal distension, unhealthy skin colour and septic appearance. The abdominal X-ray revealed dilatation of the intestinal loops (Fig. 1). Following administration of an enema of N-acetylcysteine 10% solution, the infants passed a viscous meconium-stained umbilical cord imprinted with the haustra of the colon (Fig. 2). Both patients showed continuous improvement, with adequate intestinal transit and absence of vomiting. The presence of comorbidities was ruled out.<sup>3</sup> Neither patient has since had further episodes of intestinal obstruction.



**Figure 1** Dilatation of intestinal loops.

DOI of original article: <https://doi.org/10.1016/j.anpedi.2022.04.012>

\* Corresponding author.

E-mail address: [alejandroperezmunuzuri@sergas.es](mailto:alejandroperezmunuzuri@sergas.es)

(A. Pérez-Muñuzuri).



**Figure 2** Meconium-stained umbilical cord imprinted with the haustra of the colon.

Early diagnosis is important to enable prompt treatment and avoid performance of unnecessary examinations and tests. The associated occurrence in 2 monozygotic twins could suggest a yet unknown genetic component.

### References

1. Yasir M, Kumaraswamy AG, Rentea RM. Meconium plug syndrome. In: StatPearls [Internet]. Treasure Island (FL): StatPearls Publishing; 2021.
2. Paradiso VF, Briganti V, Oriolo L, Coletta R, Calisti A. Meconium obstruction in absence of cystic fibrosis in low birth weight infants: an emerging challenge from increasing survival. *Ital J Pediatr.* 2011;14:37.
3. Keckler SJ, St Peter SD, Spilde TL, Tsao K, Ostlie DJ, Holcomb GW, et al. Current significance of meconium plug syndrome. *J Pediatr Surg.* 2008;43(5):896–8.