

Influence of hydroxyurea on the severity of acute chest syndrome in patients with sickle cell disease[☆]



Influencia de la hidroxiurea en la gravedad de los episodios de síndrome torácico agudo en pacientes con drepanocitosis

To the editor:

Sickle-cell disease is one of the most frequent inherited diseases, and its prevalence is growing in Spain due to immigration.¹ The term “sickle cell” refers to the distorted crescent shape that red blood cells (RBCs) develop due to the polymerization of their atypical form of haemoglobin, haemoglobin S, which results from a point mutation in the haemoglobin beta gene. The distorted shape of the RBCs and their interaction with other blood cells, plasma factors and the vascular endothelium cause their destruction and obstruction of small vessels, producing inflammation and ischaemia.² This can lead to various complications, acute and chronic.

One of the most frequent and severe complications is acute chest syndrome (ACS), which is the second leading cause of admission in affected individuals and is associated with significant morbidity and mortality. It is a form of acute lung injury caused by lung infarction and inflammation with or without atelectasis possibly associated with respiratory infection.³

For more than 20 years, hydroxyurea (HU) has been used as a disease-modifying treatment. It has been found to reduce the frequency of pain episodes in these patients in addition to other acute complications, including ACS.⁴ However, studies have not been performed to determine whether it can modify the course of ACS, reducing the severity of the episodes.

We conducted a study to analyse whether chronic treatment with HU had an impact on the severity of ACS episodes requiring admission in our hospital. We conducted a retrospective study of

ACS episodes in paediatric patients (aged 0-17 years) with sickle cell disease managed between 1987 and 2019 in a secondary care hospital in the Community of Madrid, Spain. The collection and analysis of data on patients with sickle cell disease (all of them included in the nationwide REHem register) was approved by the ethics committee of the hospital, the Department of Child Protection and the Spanish Agency on Data Protection, and was promoted by the Sociedad Española de Hematología y Oncología Pediátricas (Spanish Society of Paediatric Haematology and Oncology, SEHOP) The statistical analysis was performed with the software SPSS® version 25.

The study included 64 episodes of ACS in 23 of the 48 patients with sickle cell disease managed at the hospital. The median duration of follow-up was 36 months (range, 0-216 meses). The median age at the time of the episode was 3.7 years (range, 0.8-16.8). Each patient experienced a median of 2 episodes (range, 1-9). In 26.6% of the episodes, the patient was being treated with HU, but we only considered it actual treatment in 20.3% of the total (n = 13), as we excluded from this count patients that did not appear to adhere to the treatment because they had not exhibited any significant increase in the mean corpuscular volume. The median time elapsed from initiation of treatment with HU to the first episode of ACS was 6 months.

We conducted a comparative analysis of 2 groups in the sample, the group of patients that was receiving HU (and adhering to treatment) (n = 13) and the group that did not receive HU (n = 51). We assessed whether there were statistically significant differences between the groups in the parameters used to define the severity of an ACS episode: length of stay, degree of haemoglobin reduction, degree of radiographic involvement, need of transfusion and type of transfusion (simple transfusion vs exchange transfusion/erythrocytapheresis), need of intravenous analgesia or opiates, need of oxygen therapy, admission to the intensive care unit and death. The eligibility for simple transfusion and erythrocytapheresis/partial manual exchange transfusion was determined in every case by the same person (ACB, one of the authors of the study) (see Table 1). We compared some baseline characteristics in the 2

Table 1 Indications for performance of simple transfusion and partial manual exchange transfusion/erythrocytapheresis in patients with sickle cell disease admitted due to an episode of ACS.

Indications for simple transfusion

Mild/moderate episode de ACS with reduction of Hb by at least 2 g/dL relative to baseline or Hb < 7 g/dL with hypoxemia

Indications for partial manual exchange transfusion/erythrocytapheresis

Severe ACS episode with multilobar involvement, pleural effusion and hypoxemia

Multilobar involvement that does not improve with simple transfusion

Multilobar involvement in patient with a previous history of recurrent severe ACS episodes

Rapid progression and clinical deterioration with hypoxaemia and need of high flow/invasive ventilation

Moderate episode of ACS (single lobe involvement) without significant reduction in Hb level and without hypoxaemia but with persistent symptoms (high fever, local hypoventilation and chest pain requiring IV morphine) after 14 days of inpatient care

ACS, acute thoracic syndrome; Hb, haemoglobin; IV, intravenous.

[☆] Please cite this article as: González-Pérez C, Gómez-Carpintero García A, Cervera Bravo Á. Influencia de la hidroxiurea en la gravedad de los episodios de síndrome torácico agudo en pacientes con drepanocitosis. An Pediatr (Barc). 2022;97:63–65.

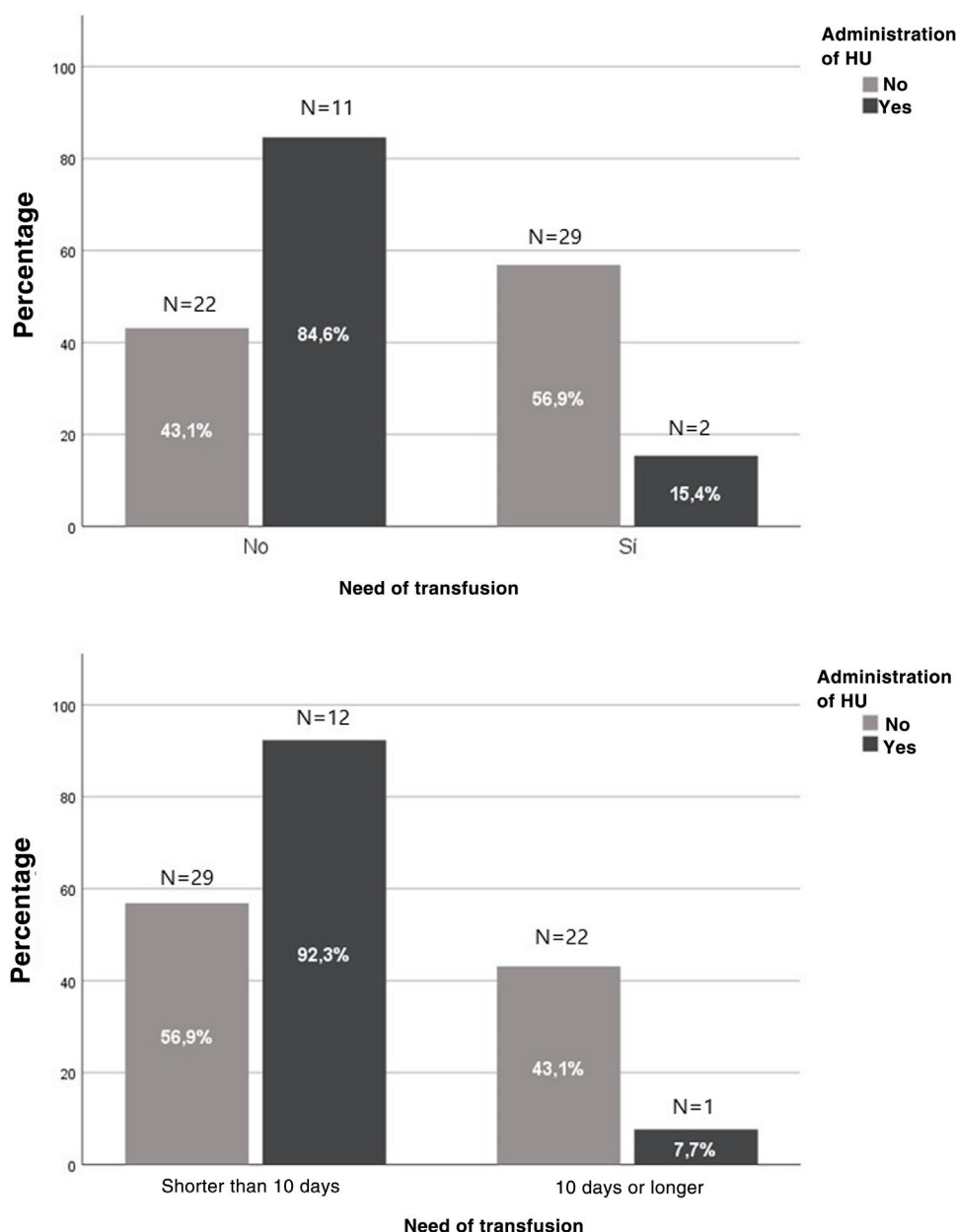


Figure 1 Impact of hydroxyurea on the severity of acute chest syndrome episodes in patients with sickle cell disease.

groups to determine whether they were comparable (sex, age, year of admission), and found no significant differences between them.

In the group treated with HU, we found a decrease in the risk of transfusion from 56.9% to 15.3% (OR, 0.138; 95% confidence interval [CI], 0.028-0.687; $P = .012$). In addition, only 9 patients required erythrocytapheresis/partial manual exchange transfusion, all in the group not treated with HU ($P = .019$). We also found a reduction in the frequency of hospitalization longer than 10 days from 43.1% to 7.7% in the treated group (OR, 0.11; 95% CI, 0.013-0.910; $P = .022$) (Fig. 1).

There are biases in this study due to its retrospective design and the significant difference between the numbers of treated and untreated patients, the latter group being very small. In addition, the study covered many years, so the management of the patients was probably not homogeneous, especially in the oldest cases. However, our study seems to suggest that treatment with HU can have an impact not only in reducing the frequency of episodes of ACS, but also their severity.

References

1. Cela E, Bellón JM, de la Cruz M, Beléndez C, Berruenco R, Ruiz A, et al. National registry of hemoglobinopathies in Spain (REPHem). *Pediatr Blood Cancer*. 2017;64, <http://dx.doi.org/10.1002/pbc.26322>.
2. Ware RE, de Montalembert M, Tshilolo L, Abboud MR. Sickle cell disease. *Lancet*. 2017;390:311–23.
3. Jain S, Bakshi N, Krishnamurti L. Acute chest syndrome in children with sickle cell disease. *Pediatr Allergy Immunol Pulmonol*. 2017;30:191–201.
4. Nevitt SJ, Jones AP, Howard J. Hydroxyurea (hydroxycarbamide) for sickle cell disease. *Cochrane Database Syst Rev*. 2017;4:CD002202.

Carlos González-Pérez*, Ana Gómez-Carpintero García, Áurea Cervera Bravo

Servicio de Pediatría, Hospital Universitario de Móstoles, Móstoles, Madrid, Spain

* Corresponding author.

E-mail address: carlosgp893@gmail.com (C. González-Pérez).

<https://doi.org/10.1016/j.anpede.2021.08.006>

2341-2879/ © 2021 Asociación Española de Pediatría. Published by Elsevier España, S.L.U. This is an open access article under the CC BY-NC-ND license (<http://creativecommons.org/licenses/by-nc-nd/4.0/>).

Splenic nodules as guiding signs in pediatric population with visceral leishmaniasis[☆]



Nódulos esplénicos como signo guía de leishmaniasis visceral en población infantil

To the editor:

Visceral leishmaniasis (VL) is a zoonosis that can be caused by more than 20 species, including *Leishmania donovani* and *Leishmania infantum*, which are endemic to the Mediterranean basin.¹

The paediatric population and immunocompromised individuals are at highest risk of this disease.^{2,3}

The prolonged incubation period and nonspecific clinical manifestations of VL pose challenges to its diagnosis, which may result in delayed diagnosis and an increase in morbidity and mortality.

Thus, we hypothesised that given the suspicion of VL, performance of an abdominal ultrasound scan could be helpful, as the presence of splenic nodules (SNs) could be indicative of this disease.^{4–6}

We conducted a retrospective longitudinal single-centre observational and analytical study. We collected data on demographic, clinical and laboratory variables for the period between January 2012 and December 2019 in a tertiary care children's hospital in a highly endemic region, including very patient aged less than 15 years with a diagnosis of VL, and performing a comparative analysis with the statistical software SPSS[®] version 25.0 based on whether or not they had SNs.

During the study period, VL was diagnosed in 20 patients, of who 45% (n = 9) had SNs.

Since the aim of the study was to characterize the group of patients with SNs, we describe the main findings in this group, and summarise the results for the main clinical variables in both groups in Table 1.

We found a slight predominance of male versus female patients (55.6% vs 44.4%); 88.9% of the patients resided in rural areas, 77.7% had had contact with dogs and 75% had spent time in the countryside. None of the patients had comorbidities.

From a clinical perspective, we ought to highlight that all patients presented with the classic triad of fever, cytopenia and splenomegaly. In addition, the physical examination revealed hepatomegaly in 88.9% of the patients and lymph node enlargement in 22.2%.

As concerns the blood counts, 100% of patients presented with anaemia, with a median haemoglobin (Hb) concentration of 8.80 g/dL (IQR, 5.30–9.50), and 22.2% required transfusion of packed red blood cells. Other types of cytopenia detected in the sample were neutropenia (77.8%) and thrombocytopenia (88.9%).

In 100% of cases, leishmaniasis was diagnosed based on serological testing. A bone marrow aspirate sample was obtained only in 2 patients, with the PCR test detecting *L. infantum* in one of them and visualization of the amastigote form of the parasite in the microscopic examination in the other case. In 2 other patients, the workup included PCR testing of peripheral blood for detection of *Leishmania*, which was negative in both.

Every patient underwent an abdominal ultrasound scan at admission, which evinced splenomegaly and multiple multifocal hypoechoic subcentimetre nodular lesions (Fig. 1). The time elapsed to resolution of SNs ranged from 2 to 20 months.

Treatment consisted in intravenous administration of liposomal amphotericin B liposomal at a dose of 4 mg/kg/day for 5 days and a sixth dose on day 10, which achieved a favourable response. Secondary haemophagocytic syndrome developed in 33.3% of the patients, which was diagnosed based on the fulfilment of a minimum of 5 clinical or laboratory criteria (cytopenia, splenomegaly, hypertriglyceridemia, fibrinogen < 1.5 g/L, ferritin > 500 µg/L, elevation of soluble CD25, haemophagocytosis in the bone marrow). None of the patients required admission to the intensive care unit. None of the patients experienced relapse and there were no deaths.

As regards statistically significant differences between the groups, we found a lower age in the group with SNs, with a median age of 8 months (IQR, 4–60 months) compared to 21 months in the group without SNs (IQR, 5–156 months) ($P = .038$). We also found higher lymphocyte counts ($P = .045$) and lesser elevation of C-reactive protein with a median level of 27.29 mg/L in the group with SNs (IQR, 2.53–74.8) compared to 88 mg/L in the group of patients without SNs (IQR, 17.48–170) ($P = .038$) (Table 1).

Given how challenging the diagnosis of VL proves to be in some cases, performance of abdominal ultrasound for detection of SNs should be considered to guide the diagnosis.^{4–6} However, it is important to be aware that these lesions are not pathognomonic of VL, and that the differential diagnosis, depending on the context, must rule out the possibility of metastasis, haematomas, cavernomas, infarction, lymphomas and abscesses.^{4–6}

The use of other imaging techniques, such as CT, MRI or PET/CT has been studied⁷ and not found to be superior compared to ultrasonography, while entailing drawbacks such as exposure to radiation or the need of sedation in paediatric patients.⁴

Our study constitutes the largest case series of patients with VL and SNs described to date. In conclusion, we believe that the sonographic detection of splenic nodules in patients with clinical and laboratory features suggestive of VL, such as fever, splenomegaly and cytopenia, could be very useful, although microbiological tests are always required to confirm the diagnosis.

[☆] Please cite this article as: Casero-González MM, Izquierdo-Palomares L, Cañuelo-Ruiz O, Montero-Yéboles R, de la Torre-Aguilar MJ, Ruiz-Sáez B. Nódulos esplénicos como signo guía de leishmaniasis visceral en población infantil. An Pediatr (Barc). 2022;97:66–68.