



ORIGINAL ARTICLE

QTc interval prolongation in patients infected with SARS-CoV-2 and treated with antiviral drugs^{☆,☆☆}



Roger Esmel-Vilomara^a, Paola Dolader^a, Anna Sabaté-Rotes^a,
Antoni Soriano-Arandes^b, Ferran Gran^a, Ferran Rosés-Noguer^{a,c,*}

^a Servicio de Cardiología Pediátrica, Hospital Universitario Vall d'Hebron, Barcelona, Spain

^b Unidad de Patología Infecciosa e Inmunodeficiencias Pediátricas, Hospital Universitario Vall d'Hebron, Barcelona, Spain

^c Paediatric Cardiology Department, Royal Brompton and Harefield NHS Foundation Trust, Londres, UK

Received 14 February 2021; accepted 9 April 2021

Available online 19 February 2022

KEYWORDS

Sars-CoV-2;
COVID-19;
Child;
Long QT syndrome;
Electrocardiography;
Hydroxychloroquine;
Azitromycin;
Remdesivir;
Lopinavir;
Ritonavir

Abstract

Introduction: Many antiviral agents, such as hydroxychloroquine, have been used to treat COVID-19, without being broadly accepted. QTc prolongation is a worrisome adverse effect, scarcely studied in pediatrics.

Patients and methods: Paediatric patients affected from COVID-19 who received antivirals were matched (1:2) with controls not infected nor exposed. Electrocardiograms were prospectively analyzed at baseline, during the first 72 h of treatment and after 72 h.

Results: Eleven (22.9%) out of 48 patients admitted due to COVID-19 (March–July 2020) received antiviral therapy. All had underlying diseases: congenital heart disease (4/11; 36.4%) and immunosuppression (3/11; 27.3%) stand out. 5/11 (45.5%) received treatment at baseline with a potential effect on QTc. There were no differences observed in the baseline QTc between cases and controls: 414.8 ms (49.2) vs 416.5 ms (29.4), ($P = .716$). Baseline long QT was observed in 2/11 cases and 2/22. Among cases, 10/11 (90.9%) received hydroxychloroquine, mainly associated with azithromycin (8/11; 72.7%), 3 received lopinavir/ritonavir and one remdesivir. The median increase in QTc after 72 h under treatment was 28.9 ms [IQR 48.7] ($P = .062$). 4/11 (36.4%) patients had a long QTc at 72 h, resulting in 3 patients ≥ 500 ms; treatment was stopped in one (QTc 510 ms) but ventricular arrhythmias were not documented.

[☆] Please cite this article as: Esmel-Vilomara R, Dolader P, Sabaté-Rotes A, Soriano-Arandes A, Gran F, Rosés-Noguer F. Evolución del intervalo QTc en pacientes con infección SARS-COV-2 tratados con fármacos antivirales. An Pediatr (Barc). 2022;96:213–220.

^{☆☆} Previous presentations: The results of the study were submitted to the 54th Annual Meeting for European Paediatric and Congenital Cardiology held in May 25–27, 2021 in Goteborg.

* Corresponding author.

E-mail address: froses@vhebron.net (F. Rosés-Noguer).

Conclusions: The use of antivirals caused an increase on the QTc interval after 72 h of treatment, being the QTc long in 36.3% of the patients, although no arrhythmic events were observed. The use of hydroxychloroquine and antivirals requires active QTc monitoring and it is recommended to discontinue treatment if QTc > 500 ms.

© 2022 Published by Elsevier España, S.L.U. on behalf of Asociación Española de Pediatría. This is an open access article under the CC BY-NC-ND license (<http://creativecommons.org/licenses/by-nc-nd/4.0/>).

PALABRAS CLAVE

SARS-CoV-2;
COVID-19;
Pediatría;
QT largo;
Electrocardiograma;
Hidroxicloroquina;
Azitromicina;
Remdesivir;
Lopinavir;
Ritonavir

1

Evolución del intervalo QTc en pacientes con infección SARS-COV-2 tratados con fármacos antivirales **Resumen**

Introducción: Muchos antivirales, como hidroxicloroquina, se han utilizado para el tratamiento de COVID-19. La prolongación del QTc es un efecto adverso preocupante, escasamente estudiado en pediatría.

Pacientes y métodos: Los pacientes pediátricos con COVID-19 que recibieron tratamiento antiviral se emparejaron (1:2) con controles no infectados ni expuestos al tratamiento. Se analizaron prospectivamente los electrocardiogramas basal, en las primeras 72 horas de tratamiento y posterior a 72 horas.

Resultados: Once (22,9%) de 48 pacientes pediátricos ingresados por COVID-19 (Marzo-Julio 2020) recibieron terapia antiviral. Todos presentaban patologías de base; destacando cardiopatías (4/11; 36,4%) e inmunosupresión (3/11; 27,3%); 5/11 (45,5%) recibían tratamiento de base con potencial efecto sobre el QTc. No hubo diferencias en el QTc basal entre casos y controles: 414,8 ms (49,2) vs 416,5 ms (29,4) ($P = ,716$). Se observó QTc prolongado basal en 2/11 casos y 2/22 controles. De los casos, 10/11 (90,9%) recibieron hidroxicloroquina, principalmente asociada a azitromicina (8/11; 72,7%); tres recibieron lopinavir/ritonavir, uno remdesivir. La mediana de incremento del QTc tras 72 horas fue de 28,9 ms [RIC 48,7] ($P = ,062$); 4/11 (36,4%) presentaron un QTc largo, de los cuáles en tres ≥ 500 ms. En uno se paró el tratamiento (QTc 510 ms) pero no se documentaron arritmias ventriculares.

Conclusiones: El uso de fármacos antivirales causó un incremento del QTc tras 72 horas de tratamiento, considerándose un QTc largo en el 36,4% de los pacientes, aunque no se objetivaron eventos arritmicos. El uso de hidroxicloroquina y antivirales requiere monitorización activa del QTc y se recomienda suspender el tratamiento si el QTc > 500 ms.

© 2022 Publicado por Elsevier España, S.L.U. en nombre de Asociación Española de Pediatría. Este es un artículo Open Access bajo la licencia CC BY-NC-ND (<http://creativecommons.org/licenses/by-nc-nd/4.0/>).

Introduction

The outbreak of severe acute respiratory syndrome coronavirus 2 (SARS-CoV-2) that causes coronavirus disease 2019 (COVID-19) was declared a pandemic and global health emergency by the World Health Organization on January 30, 2020¹ and continues to be the main concern of health care systems worldwide, with more than 100 million confirmed cases and 2 500 000 deaths recorded to date.^{1,2} In Spain, there have been more than 3 000 000 confirmed cases of COVID-19 and more than 70 000 related deaths to date.^{1,3}

In the early literature on COVID-19, severe cases in the paediatric population were only reported exceptionally, but as time went by, the number of cases described in this age group has grown,⁴⁻⁶ although the severity of the disease has continued to be far lower compared to the adult population. In Spain, only 0.8% of the total cases were in individuals under 18 years.⁴

At present, there are no authorised or universally accepted therapies for aetiological treatment of COVID-19.

While numerous agents have been investigated and multiple studies published, there is still no widely accepted antiviral treatment.^{2,7,8}

The first published studies that presented limited data on the in vitro suppression of SARS-CoV-2 activity led to the use of drugs in the aminoquinoline group: chloroquine and hydroxychloroquine, previously used for treatment of Ebola, H7N9 influenza and severe acute respiratory syndrome (SARS) associated with coronavirus infection.^{2,7} The treatment regimens varied between countries and hospitals, in the clinical indication for their use and in published studies.^{9,10} Current studies with more robust methods have not been able to replicate past results, and these drugs carry a risk of harm to the patient, as their use has been associated with several potential adverse effects, most importantly those involving the heart.^{2,7,11,12}

Among the adverse events documented in association with the use of hydroxychloroquine, QT interval prolongation and severe ventricular arrhythmias are among the most alarming,^{13,14} especially when combined with

other drugs with similar potential adverse effects, such as azithromycin.^{11,15}

The evidence on electrocardiographic abnormalities in paediatric patients with COVID-19 is scarce.¹⁶ There is also a dearth of data on the use of hydroxychloroquine and other antiviral drugs in large series of paediatric patients outside the context of the COVID-19 pandemic. The association between hydroxychloroquine and heart conduction disorders, well established in adults, continues to be unpredictable in paediatric patients, and only one study in paediatric patients with systemic lupus erythematosus has attempted, unsuccessfully, to establish this association.¹⁷

The aim of our study was to assess the degree of QT interval prolongation in paediatric patients with COVID-19 managed in our hospital in relation to the administration of hydroxychloroquine and antiviral drugs recommended for treatment of COVID-19: lopinavir/ritonavir, remdesivir and azithromycin.

Sample and methods

We selected patients from the total population of paediatric patients admitted to the Hospital Universitario Vall d'Hebron (Barcelona, Spain) due to COVID-19 confirmed by polymerase chain reaction (PCR) in a nasopharyngeal aspirate sample or a positive serology test. We collected data prospectively between March and July of 2020.

The inclusion criterion was administration hydroxychloroquine, azithromycin, lopinavir/ritonavir or remdesivir for treatment of COVID-19 pneumonia during the period under study, met by a total of 11 cases.

We matched cases for age and sex in a 1:2 ratio to controls without structural heart disease that did not receive any of the drugs under study and without SARS-CoV-2 infection.

For all patients, we collected data on the diagnosis of COVID-19 and pre-existing diseases. When it came to treatment, we recorded the different drugs used and the duration of treatment. Treatment regimens were selected according to the indications established in the protocol of the hospital applicable at the time admission of each patient, which was based on the current recommendations and evidence available at the time.

The standard oral hydroxychloroquine regimen was 6.5 mg/kg/day in children under 6 years or 10 mg/kg/day in children aged 6 or more years to a maximum of 400 mg/day for a total of 5 days. Remdesivir was administered intravenously at a dose of 2.5 mg/kg/day (maximum, 100 mg) for 9 days following a loading dose of 5 mg/kg (maximum, 200 mg) on day 1. Lopinavir/ritonavir was administered orally with a dose of lopinavir of 600 mg/m²/day in infants under 3 months, 24 mg/kg/day in patients with a body weight of up to 15 kg and 20 mg/kg/day in patients with a weight of 15 kg or greater to a maximum of 800 mg/kg/day. Azithromycin was delivered through the oral route at a dose of 10 mg/kg/day for a total of 3 days.

All the electrocardiograms (ECGs) were interpreted manually by the same researcher. The QT interval was measured for 3 different beats, and the corrected QT interval (QTc) was calculated using the Bazett formula ($QTc = QT / \sqrt{RR}$). We defined QTc prolongation as a QTc greater than 440 ms in male patients and 460 ms in female patients. The clinical

variables analysed were changes in the ECG observed during the administration of the drugs under study relative to baseline. To this end, we established 3 time periods for ECG analysis: baseline before treatment initiation, before 72 h of treatment, and after 72 h of treatment, and we calculated differences in the QTc interval between baseline and the first 72 h of treatment, and between the first 72 h of treatment and after the first 72 h. Due to the challenging circumstances of the time when the study took place, the ECG performed before initiation of treatment was not saved in 2 of the cases.

We have expressed categorical data as proportions and compared them with the *F*-test. We expressed quantitative data as median and interquartile range (IQR), as the data did not follow a normal distribution. We compared continuous data with the Mann-Whitney *U* test or the Kruskal-Wallis test. To analyse trends in the QTc interval, we used the Wilcoxon signed-rank test for paired samples. We used a *P*-value of less than .05 to define statistical significance. The statistical analysis was conducted with the software SPSS version 27.0 (IBM).

Results

Between March and December 2020, a total of 48 paediatric patients required admission to our hospital in the context of SARS-CoV-2 infection. Of this total, only 11 received at least one of the drugs under study, corresponding to 22.9% of the total, and all of them managed between the months of March and May. No paediatric patient received these drugs at a later time.

The age of the patients varied widely from 17 days in the youngest and 15 years in the oldest, with a median age of 9 years (IQR, 10.5 years). A total of 45.5% (5/11) were female. [Table 1](#) and [Table 2](#) present the demographic characteristics of the patients.

One of the salient characteristics of the sample was the presence of significant comorbidities in all 11 patients, diseases that in most cases contributed to the need of admission in the context of infection by SARS-CoV-2. The most frequent underlying diseases were heart diseases (4/11; 36.4%) and diseases resulting immunosuppression, including 2 patients with blood tumours and 1 liver transplant recipient (3/11; 27.3%). Six of the 11 patients (54.5%) required admission to the intensive care unit due to the severity of the disease.

As concerns treatment, 90.9% (10/11) of the patients received hydroxychloroquine, which was the most frequently used drug. In most cases, hydroxychloroquine was combined with azithromycin (8/11 [72.7%]: all but 2 patients treated with hydroxychloroquine), which was the most frequently prescribed combination of drugs. Three patients (27.3%) received lopinavir/ritonavir and 1 (9.1%) remdesivir. The only paediatric patient that received remdesivir was a girl aged 12 months with congenital surfactant deficit that was already receiving hydroxychloroquine and azithromycin for treatment of underlying disease, to which lopinavir/ritonavir and remdesivir were added. None of the patients in the sample received tocilizumab.

Two patients in the COVID-19 case group (2/11; 18.2%) and 2 in the control group (2/22; 9.1%) had QTc prolongation

Table 1 Individual description of the patients included in the study.

Patient	Age	Sex	Underlying disease	COVID-19 treatment	Previous medication that could affect QT	Prolonged baseline QT	[0.8–10]QTc (ms)			Treatment discontinuation	Development of arrhythmia
							Baseline	<72 h	>72 h		
1	15 years	Female	Congenital mitral valve stenosis and regurgitation, carrier of mechanical valve. Complete heart block after surgery. Chronic heart failure.	Lopinavir/ritonavir	Sotalol and flecainide	Yes	470	487	500	No	No
2	17 days	Male	Dextrocardia with situs inversus. Atrial septal defect.	Hydroxychloroquine Azithromycin		No	414	415	464	No	No
3	12 months	Female	Severe bronchopulmonary dysplasia. Congenital surfactant deficiency.	Hydroxychloroquine Azithromycin Lopinavir/ritonavir Remdesivir	Hydroxychloroquine Azithromycin	No	–	379	392	No	No
4	21 months	Male	B-cell acute lymphoblastic leukaemia.	Hydroxychloroquine Azithromycin	Cotrimoxazole	No	428	373	404	No	No
5	15 years	Female	Asthma	Hydroxychloroquine Azithromycin		No	–	416	431	No	No
6	6 months	Female	Complete AV septal defect. Down syndrome.	Hydroxychloroquine Azithromycin		No	412	403	442	No	No
7	9 years	Male	Brainstem dysgenesis with mega cisterna magna. Spastic dystonic tetraparesis.	Hydroxychloroquine Azithromycin		No	387	453	413	No	No
8	11 years	Male	Liver transplant recipient due to biliary cirrhosis secondary to alpha-1-antitrypsin deficiency.	Hydroxychloroquine Azithromycin	Tacrolimus	No	415	413	402	No	No
9	12 years	Female	B-cell acute lymphoblastic leukaemia.	Hydroxychloroquine Azithromycin	Cotrimoxazole	No	379	436	425	No	No
10	6 months	Male	Dilated cardiomyopathy.	Hydroxychloroquine		Yes	489	471	510	Yes	No
11	11 years	Male	Hypothyroidism	Hydroxychloroquine		No	419	430	500	No	No

AV, atrioventricular; QTc, corrected QT interval.

Table 2 Demographic characteristics of the sample. Comparison of cases and controls.

Characteristic	Cases: n (%)	Controls: n (%)	P
<i>Total</i>	11 (100%)	22 (100%)	
<i>Age in months:</i>			
Median (interquartile range)	110 (136)	110 (140)	.895
<i>Sex</i>			
Male	6 (54.5%)	12 (54.5%)	.645
Female	5 (45.5%)	10 (45.5%)	
Comorbidities	11 (100%)	6 (27.3%)	
Heart disease	4 (36.4%)	0 (0%)	
Lung disease	2 (18.2%)	2 (9.1%)	
Malignant blood tumour	2 (18.2%)	4 (18.2%)	
Solid organ transplant	1 (9.1%)	0 (0%)	
Neurologic disease	1 (9.1%)	0 (0%)	
Metabolic disease	1 (9.1%)	0 (0%)	
Previous outpatient medication	9 (81.1%)	4 (18.2%)	
With effect on QT	5 (45.5%)	2 (9.1%)	
<i>QTc before treatment</i>			
Median (interquartile range)	414.8 (49.2)	416.5 (29.4)	.716
Received treatment		0 (0%)	
Hydroxychloroquine	10 (90.9%)		
Azithromycin	8 (72.7%)		
Lopinavir/ritonavir	3 (27.3%)		
Remdesivir	1 (9.1%)		
<i>Severity of episode</i>			
Admission to ward	5 (45.5%)	0 (0%)	
Admission to intensive care unit	6 (54.5%)	0 (0%)	

QTc, corrected QT interval.

at baseline (>440 ms in male patients and >460 ms in female patients). The median baseline QTc in the case group was 414.8 ms (IQR, 49.2), and we did not find significant differences compared to the control group (median QTc, 416.5 ms; IQR, 29.4) ($P = .716$). Both cases and controls had a variety of underlying diseases. In fact, 45.5% (5/11) of the group with COVID-19 was in treatment with drugs that affect the QTc interval at baseline: 1 patient was in treatment with sotalol and flecainide, 1 with tacrolimus, 2 with cotrimoxazole and 1, as we noted above, with azithromycin and hydroxychloroquine. All of them were receiving these drugs for long-term medication. In the control group, 2 patients (9.1%) had chronic respiratory diseases and 4 (18.2%) had malignant blood tumours, in 2 cases treated with medication that could affect the QT interval (cotrimoxazole).

The analysis of QTc changes in the case group revealed a median increase of the QTc of only 1.5 ms (IQR, 50.25) between the baseline ECG and the ECG tracings in the first 72 h of treatment. The median QTc increase starting from 72 h of treatment initiation was 28.9 ms (IQR, 48.7; $P = .062$) (Fig. 1). Four of the 11 patients with COVID-19 (36.4%) had a prolonged QTc for age, with prolongation present at baseline in 2. Three of them (27.2%) reached a QTc interval of 500 ms or greater, and treatment with hydroxychloroquine was discontinued early in 1 due to a QTc of 510 ms (the other 2 had a QTc of 500 ms). None of the patients experienced severe ventricular arrhythmias during the stay and none died.

When it came to the differences between the administered antiviral agents, of the 3 patients that received lopinavir/ritonavir, 2 experienced prolongation of the QTc

interval, which was already present at baseline in 1 (this patient was also the only one in the cohort that did not receive hydroxychloroquine). As for remdesivir, the only patient treated with this drug did not exhibit QTc prolongation; this patient also received lopinavir/ritonavir and was under treatment with azithromycin and hydroxychloroquine for underlying disease.

Discussion

At present, there are very few data on electrocardiographic abnormalities in patients with COVID-19 in the paediatric population. We present an analysis of a series of patients that received antiviral treatment in a tertiary care hospital in Barcelona, Spain (11 of a total of 48 paediatric patients admitted in 2020).

We ought to highlight the substantial proportion of patients with significant comorbidities, a factor that probably plays a role in hospital admission and therefore in pharmacological treatment. In addition to the presence of chronic comorbidities, we ought to mention the high proportion of patients that were receiving medication for underlying conditions, including drugs with an effect on the QTc interval (5/11; 45.5%), and that 2 (18.2%) had a prolonged QTc at baseline. Due to the presence of a number of patients with different diseases in the control group (6/22 [27.3%]; 2/22 [9.1%] treated with drugs that could affect the QTc interval) and the small sample size, we may not be able to rule out the similarity of the baseline QTc in both groups.

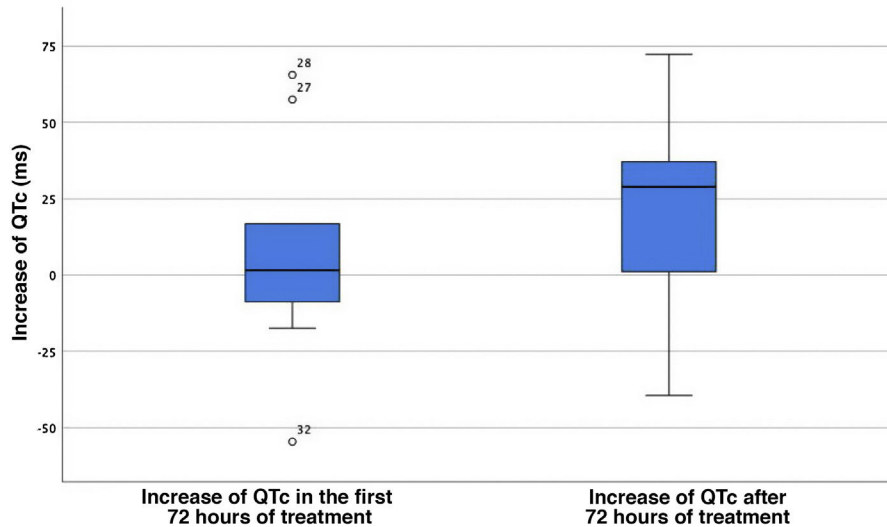


Figure 1 Increase of the QTc interval in the first 72 h of treatment and after 72 h from treatment initiation. The central value corresponds to the median, and the edges of the box mark the interquartile range. The isolated points with accompanying values are outlier QTc values. QTc, corrected QT interval.

Table 3 Risk factors for QT interval prolongation.

General risk factors	Illness-related risk factors
Congenital long QT syndrome	Hypokalaemia
Use of QT-prolonging medication	Hypomagnesemia
Female sex	Sepsis
	Myocardial injury, ischemia, or heart failure
	Renal impairment
	Bradycardia (heart rate <60 bpm)
	Recent conversion from atrial fibrillation

Source: Jankelson et al.¹⁰

When it comes to antiviral agents with arrhythmogenic potential, such as hydroxychloroquine, their long half-lives (approximately 1 month) result in a greater accumulation and higher concentrations of the drug with chronic use compared to short-term use, so shorter courses are probably safer for treatment of COVID-19.^{10,13}

On the other hand, patients with COVID-19 could constitute a group at increased risk of arrhythmia due to the greater incidence of myocardial injury and heart failure associated with the disease.¹⁸ In addition, these patients have been found to be more likely to have other risk factors for arrhythmia, such as sepsis, hypoxia, electrolyte imbalances, multiple organ failure and concomitant use of other drugs that prolong the QT interval,^{10,19} which was also the case in our sample, with a high proportion of patients with chronic diseases and ongoing pharmacological treatment of underlying disease (45.5% were receiving drugs that could affect the QTc interval). Table 3 presents the known risk factors for QT prolongation.¹⁰ Severe hypoxia, which has been

described in some patients with COVID-19 pneumonia, would also increase the risk of arrhythmia,²⁰ so that it is the patient with most severe disease that are most at risk of developing severe arrhythmias.¹⁰ In our sample of 11 patients, none developed arrhythmia, despite 54.5% of them having severe enough disease to require admission to the intensive care unit and 2 of them requiring invasive mechanical ventilation.

Due to promising preclinical data, hydroxychloroquine has been the most widely used drug among the different pharmacological treatments tried for management of COVID-19.^{7,11,13} It has a structure similar to that of quinidine, a class 1A antiarrhythmic agent whose activity prolongs the QT interval and increases the risk of torsades de pointes¹⁴. Hydroxychloroquine acts by inhibiting KCNH2 potassium channels (also known as hERG channels), blocking the rapid component of the delayed rectifier potassium current (IKr) and increasing the risk of QTc interval prolongation.^{19,21}

A prolonged QTc interval is the electrocardiographic representation of delayed ventricular repolarization and facilitates the development of early depolarizations that could give rise to torsade de pointes.¹⁰ Despite the significant percentage of patients with a prolonged QTc at baseline (2/11; 18.2%) and with treatment (4/11; 36.4%), none developed torsade de pointes or any other form of arrhythmia.

In our study, we found that the largest change in the QTc interval was observed starting from 72 h of treatment, with a median increase of 28.9 ms, although the observed differences were not statistically significant ($P = .062$). The lack of statistical significance is probably due to the small size of the sample, with was the main limitation of the study. Multicentre studies in larger samples would be useful to confirm this association, although the removal of these drugs from the COVID-19 treatment protocols poses a barrier to their performance. To date, no studies have been published on the use of hydroxychloroquine in the context of the pandemic in sizeable samples of paediatric patients, and the only available data come from small cohort studies,¹⁶ so our

case series is one of the few sources in the literature on its use in paediatric patients in Spain.

Many of the protocols for treatment of the novel coronavirus have included the use of azithromycin combined with hydroxychloroquine. Azithromycin also affects the QT interval through inhibition of the IKr current,^{22,23} and it is hypothesised that there is an increased risk of QTc in patients treated with the combination of these 2 drugs, in addition to an increased risk of bundle branch block.⁹ In addition, the IKr current could also be affected in patients with SARS-CoV-2 infection due to the increased production of interleukin-6.²⁴ Given the scarcity of the evidence supporting the beneficial effects of hydroxychloroquine and its combination with azithromycin, some authors recommend trying to avoid their use.²⁵

Other drugs used for treatment of SARS-CoV-2, such as favipiravir or lopinavir/ritonavir, can also result in QT interval prolongation and torsades de pointes.¹³ The combination of several drugs that may affect the QT interval can have a particularly significant effect on patients under chronic treatment with drugs that affect the QT interval, as was the case of the patient treated with sotalol and flecainide with a prolonged baseline QTc.

Since patients who require admission usually have multiple comorbidities and may be receiving several drugs for treatment of underlying diseases, and given the potential effect on the QTc that we observed in the drugs under study, clinicians should carefully consider the risks and benefits of their use and closely monitor the QTc interval. Several publications offer guidance on the monitoring of QT interval prolongation in patients with COVID-19 treated with hydroxychloroquine. Their recommendations are not entirely consistent, with some authors proposing ECG monitoring at baseline and during treatment^{10,13,26} and others reserving this recommendation for at-risk patients,²⁷ while the main barriers to ECG monitoring identified in the literature are the heavy workloads of clinicians and the increased exposure to infected patients associated with this approach.²⁶

When it comes to paediatric patients, it seems reasonable to always do an ECG before initiating treatment and to monitor patients with repeated ECGs, mainly starting from 72 h of treatment, to assess whether they have developed substantial QTc prolongation and suspend treatment in patients with sustained QTc values greater than 500 ms.

Conflicts of interest

The authors have no conflicts of interest to declare.

Data availability

Data will be made available on request.

References

- World Health Organization [Internet]. WHO Coronavirus Disease (COVID-19) Dashboard. Available from: <https://who.sprinklr.com/>.
- Meyerowitz EA, Vannier AGL, Friesen MGN, Schoenfeld S, Gelfand JA, Callahan MV, et al. Rethinking the role of hydroxychloroquine in the treatment of COVID-19. *FASEB J*. 2020;34:6027–37.
- Ministerio de Sanidad de España [Internet]. Enfermedad por nuevo coronavirus COVID-19. Available from: <https://www.mscbs.gob.es/>.
- Tagarro A, Epalza C, Santos M, Sanz-Santaefemia FJ, Otheo E, Moraleda C, et al. Screening and severity of coronavirus disease 2019 (COVID-19) in children in Madrid, Spain. *JAMA Pediatr*. 2020:e201346.
- US Department of Health & Human Services, Centers for Disease Control and Prevention (CDC) COVID-19 Response Team. Coronavirus Disease 2019 in Children – United States, February 12–April 2, 2020. *Morb Mortal Wkly Rep (MMWR)*. 2020;69:422–6.
- Morey-Olivé M, Espiau M, Mercadal-Hally M, Lera-Carballo E, García-Patos V. Cutaneous manifestations in the current pandemic of coronavirus infection disease (COVID 2019). *An Pediatr (Barc)*. 2020;92:374–5.
- Rosenberg ES, Dufort EM, Udo T, Wilberschied LA, Kumar J, Tesoriero J, et al. Association of treatment with hydroxychloroquine or azithromycin with in-hospital mortality in patients with COVID-19 in New York State. *JAMA*. 2020;323:2493–502.
- US Department of Health & Human Services. Centers for Disease Control and Prevention (CDC) [internet]. Coronavirus (COVID-19). Available from: <https://www.cdc.gov/coronavirus/2019-nCoV/index.html/>.
- Das S, Bhowmick S, Tiwari S, Sen S. An updated systematic review of the therapeutic role of hydroxychloroquine in coronavirus disease-19 (COVID-19). *Clin Drug Investig*. 2020;40:591–601.
- Jankelson L, Karam G, Becker ML, Chinitz LA, Tsai MC. QT prolongation, torsades de pointes, and sudden death with short courses of chloroquine or hydroxychloroquine as used in COVID-19: a systematic review. *Heart Rhythm*. 2020;17:1472–9.
- Mercuro NJ, Yen CF, Shim DJ, Maher TR, McCoy CM, Zimetbaum PJ, et al. Risk of QT interval prolongation associated with use of hydroxychloroquine with or without concomitant azithromycin among hospitalized patients testing positive for coronavirus disease 2019 (COVID-19). *JAMA Cardiol*. 2020;5:1036–41.
- Molina JM, Delaugerre C, Le Goff J, Mela-Lima B, Ponscarre D, Goldwirt L, et al. No evidence of rapid antiviral clearance or clinical benefit with the combination of hydroxychloroquine and azithromycin in patients with severe COVID-19 infection. *Med Mal Infect*. 2020;50:384.
- Naksuk N, Lazar S, Peeraphatdit TB. Cardiac safety of off-label COVID-19 drug therapy: a review and proposed monitoring protocol. *Eur Heart J Acute Cardiovasc Care*. 2020;9:215–21.
- World Health Organization. The cardiotoxicity of antimalarials: Malaria Policy Advisory Committee Meeting. 2017.
- Ray WA, Murray KT, Hall K, Arbogast PG, Stein CM. Azithromycin and the risk of cardiovascular death. *N Engl J Med*. 2012;366:1881–90.
- Samuel S, Friedman RA, Sharma C, Ganigara M, Mitchell E, Schlei C, et al. Incidence of arrhythmias and electrocardiographic abnormalities in symptomatic pediatric patients with PCR positive SARS-CoV-2 infection including drug induced changes in the corrected QT interval (QTc). *Heart Rhythm*. 2020;17:1960–6.
- AlTwaajery M, AlMane W, Al-Mayouf SM. Electrocardiographic disturbances in children with systemic lupus erythematosus. *Int J Pediatr Adolesc Med*. 2018;5:127–30.
- Zheng YY, Ma YT, Zhang JY, Xie X. COVID-19 and the cardiovascular system. *Nat Rev Cardiol*. 2020;17:259–60.
- Roden DM. Predicting drug-induced QT prolongation and Torsades De Pointes. *J Physiol*. 2016;594:2459–68.
- Plant LD, Xiong D, Romero J, Dai H, Goldstein SAN. Hypoxia produces pro-arrhythmic late sodium current in cardiac myocytes by SUMOylation of NaV1.5 channels. *Cell Rep*. 2020;30:2225–36.

21. Roden DM. Drug-induced prolongation of the QT interval. *N Engl J Med.* 2004;350:1013–22.
22. Roden DM, Harrington RA, Poppas A, Russo AM. Considerations for drug interactions on QTc in exploratory COVID-19 treatment. *Circulation.* 2020;141:e906–7.
23. Capel RA, Herring N, Kalla M, Yavari A, Mirams GR, Douglas G, et al. Hydroxychloroquine reduces heart rate by modulating the hyperpolarization-activated current *I_f*: novel electrophysiological insights and therapeutic potential. *Heart Rhythm.* 2015;12:2186–94.
24. Lazzerini PE, Boutjdir M, Capecchi PL. COVID-19, arrhythmic risk and inflammation: mind the gap! *Circulation.* 2020;142:7–9.
25. Lane JCE, Weaver J, Kostka K, Duarte-Salles T, Abrahao MTF, Alghoul H, et al. Safety of hydroxychloroquine, alone and in combination with azithromycin, in light of rapid wide-spread use for COVID-19: a multinational, network cohort and self-controlled case series study. *MedRxiv.* 2020, <http://dx.doi.org/10.1101/2020.04.08.20054551>.
26. Giudicessi JR, Noseworthy PA, Friedman PA, Ackerman MJ. Urgent guidance for navigating and circumventing the QTc prolonging and torsadogenic potential of possible pharmacotherapies for COVID-19. *Mayo Clin Proc.* 2020;95:1213–21.
27. Lakkireddy DR, Chung MK, Gopinathannair R, Patton KK, Gluckman TJ, Turagam M, et al. Guidance for cardiac electrophysiology during the coronavirus (COVID-19) pandemic from the Heart Rhythm Society COVID-19 Task Force; Electrophysiology Section of the American College of Cardiology; and the Electrocardiography and Arrhythmias Committee of the Council on Clinical Cardiology, American Heart Association. *Circulation.* 2020;141:e823–31.