

## Clinical ultrasound in pediatric and neonatal interfacility transport<sup>☆</sup>



### Utilidad de la ecografía clínica en el traslado interhospitalario del paciente crítico pediátrico y neonatal

Dear Editor:

Point-of-care ultrasound (POCUS) has become a key tool in the diagnosis and treatment of critically ill children and infants in emergency and intensive care settings.<sup>1,2</sup> However, when it comes to interfacility transport, the available evidence is too scarce to support its use.<sup>3</sup> We present the results of a descriptive study on the use of POCUS in the interfacility transport of critically ill neonatal and paediatric patients that evinced its usefulness.

We collected data on the POCUS examinations performed by a paediatric and neonatal advanced life support land transport team of the medical emergency response system of Catalonia, Spain, between November 1, 2019 and February 29, 2020. The data were collected prospectively by the paediatricians who performed the examinations, who entered the information in a database created for the purpose. All had undergone a theoretical and practical training on POCUS and had experience in the stabilization and transport of critically ill paediatric and neonatal patients. The variables under study included demographic characteristics, initial diagnosis, main compromised system, setting where the POCUS was performed, ultrasound probes and settings used, duration of POCUS, regions examined with POCUS, POCUS protocol, POCUS findings, final diagnosis and impact

of findings on patient management. Images were obtained with a SonoSite Edge II<sup>®</sup> ultrasound system, linear transducers (13–6 MHz) and sector transducers (8–4 and 5–1 MHz).

There were 270 patient transports in the period under study. Twenty-six ultrasound examinations were performed in a total of 23 patients (8.5%). [Table 1](#) summarises the main clinical and demographic characteristics of the patients, and [Table 2](#) the main findings of POCUS. Fourteen POCUS examinations (53.8%) were performed in the ambulance and 12 (46.2%) in the referring hospital, without significant differences in patient characteristics between these groups. The median duration of POCUS examinations was 5 min (range, 3–10). The findings of POCUS led to changes in the diagnosis or management of the patients in 53.8% cases ( $n = 14$ ): drainage of pneumothorax in 3, stepping up of haemodynamic support in 3 (administration of fluids and/or adrenergic agonists), optimization of ventilation after ruling out pneumothorax in 3, avoidance of volume expansion in 2 patients due to absence of signs of hypovolaemia and of performance of a chest radiograph in 1 patient, and a change in diagnosis in 2 patients.

Previous evidence of POCUS demonstrates that the contribution of its findings to clinical decision-making can improve patient outcomes.<sup>4</sup> It has also proven useful in establishing the indication for certain procedures (such as drainage of pneumothorax) or changing the diagnosis.

The scarce evidence on the use of POCUS during transport focuses on neonatal patients,<sup>5</sup> but only one third of the patients that underwent POCUS examination in our study were newborn infants, which highlights the importance of this approach in paediatric patients, too.

There are limitations to the use of POCUS during patient transport. Chief among them is the need of specialised

**Table 1** Main clinical and demographic characteristics of patients and transport events.

	Patients with US $n = 23$	Patients without US $n = 247$	<i>P</i>
<b>[0,1–4]Demographic variables</b>			
Age, median (range)	85 days (4 h–6 years)	66 days (1.5 h–15 years)	.80
Transport to neonatal units, $n$ (%)	8 (34.8%)	62 (25.1%)	[1.0].31
Transport to paediatric units, $n$ (%)	15 (65.2%)	185 (74.9%)	
<b>[0,1–4]</b>			
<b>[0,1–4]Clinical diagnosis</b>			
Bronchiolitis, $n$ (%)	5 (21.7%)	89 (36.0%)	.16
Septic shock, $n$ (%)	4 (17.4%)	1 (0.4%)	< .001
Other types of shock, $n$ (%)	5 (21.7%)	0 (0.0%)	< .001
Neonatal respiratory distress, $n$ (%)	3 (13.0%)	7 (2.8%)	.013
Other, $n$ (%)	6 (26.1%)	150 (60.7%)	.001
<b>[0,1–4]</b>			
<b>[0,1–4]Transport variables</b>			
Time to stabilization in minutes, median (range)	39 (21–129)	45 (6–221)	.72

Time to stabilization: time elapsed between arrival to and departure from the sending hospital.

<sup>☆</sup> Please cite this article as: Subirana Campos L, Renter Valdivinos L, Oller Fradera O, Garcés Montolio L, Gómez Rodríguez J. Utilidad de la ecografía clínica en el traslado interhospitalario del paciente crítico pediátrico y neonatal. *An Pediatr (Barc)*. 2021;95:201–203.

**Table 2** Important findings of performed ultrasound scans ( $n = 26$ ).

Detected compromise	$n$ (%)	Indication	$n$ (%)	Findings	$n$ (%)	Effect on management
Respiratory	14 (53.8%)	Suspected pneumothorax	6 (23.1%)	Confirmation of pneumothorax	3 (11.5%)	Decision to drain
				Absence of pneumothorax	3 (11.5%)	Optimization of ventilation settings
		Examination of lung parenchyma	4 (15.4%)	Change in diagnosis	2 (7.7%)	Diagnosis of RDS (1) and TTN (1)
				Confirmation of diagnosis	2 (7.7%)	Diagnosis unchanged
		Monitoring after pneumothorax drainage	2 (7.7%)	Correct drainage of pneumothorax	2 (7.7%)	Avoided chest X-ray
Suspected pleural effusion	2 (7.7%)	Confirmation of pleural effusion	2 (7.7%)	No change in management		
Cardiovascular	10 (38.5%)	Assessment of volume status	4 (15.4%)	Signs of volume depletion	2 (7.7%)	Volume expansion
				No signs of volume depletion	2 (7.7%)	No volume expansion
		Assessment of cardiac function	6 (23.1%)	Systolic dysfunction	1 (3.8%)	Initiation of vasoactive drug
				Diagnosis of VSD	1 (3.8%)	No change in management
		Adequate cardiac function	4 (15.4%)	No change in management		
Neurologic	2 (7.7%)	Suspected intracranial lesion	2 (7.7%)	Absence of intracranial lesion (TUS)	2 (7.7%)	No change in management

RDS, respiratory distress syndrome; TTN, transient tachypnoea of the newborn; TUS, transfontanellar ultrasound; VSD, ventricular septal defect.

training to prevent errors in its interpretation. However, qualification of previously untrained staff can be achieved in a fairly reasonable time with an appropriate training format.<sup>6</sup> Another limitation is the need to weigh the relevance of the information that may be obtained with this technique against the delay in transport that results from its use. Since transport is a very different context compared to the critical care setting (fewer staff and resources, smaller spaces and crucial importance of the time allocated to tasks), POCUS should be reserved for cases in which, given a specific suspicion, the findings may result in a change in management, clinical situations of which shock may be one example, a condition that was not assessed with the help of POCUS in only one affected patient in our study.

The main limitation of our study is its small sample size, which calls for caution in the interpretation of its results. The low proportion of patients that underwent a POCUS examination could be due to the fact that the period under study included the bronchiolitis season. Point-of-care ultrasound during transport is not indicated in patients with bronchiolitis unless it is required for differential diagnosis or to rule out complications (pneumothorax). Another limitation was that we were unable to determine whether the changes in diagnosis or management resulting from POCUS yielded actual benefits in terms of length of stay, mortality or the severity score at the time of admission.

In conclusion, our findings show that a significant proportion of patients in whom POCUS during transport is indicated may benefit from performance of this technique without an

associated increase in the time to stabilization. The indication of POCUS must be determined on a case-by-case basis to avoid delays in transport. Patients with respiratory or haemodynamic compromise benefitted most from the technique. Performance of POCUS during transport needs to be documented to confirm and strengthen these findings.

## References

1. Le Coz J, Orlandini S, Titomanlio L, Rinaldi VE. Point of care ultrasonography in the pediatric emergency department. *Ital J Pediatr.* 2018;44:87.
2. González Cortés R, Renter Valdovinos L, Coca Pérez A, Vázquez Martínez JL. Point-of-care ultrasound in Spanish paediatric intensive care units. *An Pediatr (Barc).* 2017;86:344–9.
3. Browning Carmo K, Lutz T, Berry A, Kluckow M, Evans N. Feasibility and utility of portable ultrasound during retrieval of sick term and late preterm infants. *Acta Paediatr.* 2016;105:e549–54.
4. El-Nawawy AA, Abdelmohsen AM, Hassouna HM. Role of echocardiography in reducing shock reversal time in pediatric septic shock: a randomized controlled trial. *J Pediatr (Rio J).* 2018;94:31–9.
5. Browning Carmo K, Lutz T, Greenhalgh M, Berry A, Kluckow M, Evans N. Feasibility and utility of portable ultrasound during retrieval of sick preterm infants. *Acta Paediatr.* 2017;106:1296–301.
6. Stritzke A, Soraisham A, Murthy P, Kowal D, Paul R, Kamaluddeen M, et al. Neonatal transport clinician performed ultrasound evaluation of cardiac function. *Air Med J.* 2019;38:338–42.

Lluís Subirana Campos<sup>a,\*</sup>, Luis Renter Valdovinos<sup>b</sup>,  
Olga Oller Fradera<sup>a</sup>, Lledó Garcés Montolio<sup>a</sup>,  
Julia Gómez Rodríguez<sup>a</sup>

<sup>a</sup> Unidad de Transporte SEM Pediátrico y Neonatal (SEMPVH), Hospital Vall d'Hebron, Barcelona, Spain

<sup>b</sup> Unidad de Cuidados Intensivos Pediátricos, Corporació Sanitària Parc Taulí, Sabadell, Spain

\* Corresponding author.

E-mail address: [lsubirana@vhebron.net](mailto:lsubirana@vhebron.net)  
(L. Subirana Campos).

<https://doi.org/10.1016/j.anpede.2020.08.007>  
2341-2879/ © 2021 Published by Elsevier España, S.L.U. on behalf  
of Asociación Española de Pediatría. This is an open access article  
under the CC BY-NC-ND license  
(<http://creativecommons.org/licenses/by-nc-nd/4.0/>).

## Sjögren-Larsson syndrome in Spain: Description of three new cases<sup>☆</sup>



### Síndrome de Sjögren-Larsson en España; descripción de 3 nuevos casos

Dear Editor:

Sjögren-Larsson syndrome (OMIM #270200) is a neurocutaneous disorder characterised by congenital ichthyosis, intellectual disability and spasticity.<sup>1</sup> It is caused by changes in the *ALDH3A2* gene, which encodes the fatty aldehyde dehydrogenase (FALDH) enzyme, involved in the oxidation of aldehydes to fatty acids.<sup>2,3</sup>

We described the different clinical and genetic characteristics of 3 cases diagnosed in our department.

Patient 1, a girl, was the first child of non-consanguineous parents with an unremarkable history. She was born at 36 weeks' gestation, exhibiting mild erythroderma that progressed to ichthyosis vulgaris (based on the findings of the skin biopsy) (Fig. 1).

She was referred to the paediatric neurology department at age 17 months due to severe axial hypotonia with instability in sitting and ichthyosis. The findings of the metabolic, neurophysiological and neuroimaging tests at the time were normal.

Although the patient did not present with additional signs of syndromic ichthyosis,<sup>4</sup> comparative genomic hybridization testing was performed, which detected a 159.6 kb deletion in region 17p11.2, hg19 (chr17:19424245-19583843) that contained the *ALDH3A2* gene. Sequencing of the other *ALDH3A2* allele revealed a frameshift variant in exon 1 (c.86.96del, p.Ala29Aspfs\*21) that gave rise to a truncated protein.

The segregation analysis of the family revealed that both changes were inherited (one from each parent).

A magnetic resonance imaging (MRI) scan performed at age 2 years found myelination defects (Fig. 2). Currently, at age 6 years, the patient has mild intellectual disability and axial hypotonia with spasticity in the lower extremities that precludes independent walking.

The patient has experienced 5 episodes of typical febrile seizures that did not require antiepileptic medication. She has not developed vision abnormalities to date.

Patients 2 and 3 are sisters in a family with no known consanguinity. At birth, at 34 and 36 weeks' gestation, respectively, both presented with moderate ichthyosis described as "lamellar". They developed the ability to sit at around 9 months and independent walking between ages 4 and 6 years. Patient 2 retains independent walking at age 22 years. Both sisters developed signs of spasticity in the first 2 years of life, and Sjögren-Larsson syndrome was suspected due to the detection of myelination defects on neuroimaging.

Both patients developed typical febrile seizures, language delay and mild intellectual disability.

At ages 14 and 16 years, respectively, inclusions were detected in the ocular fundus.

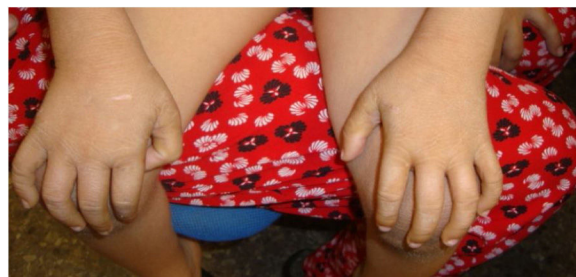

Figure 1 Mild ichthyosis at age 5 years, patient 1.

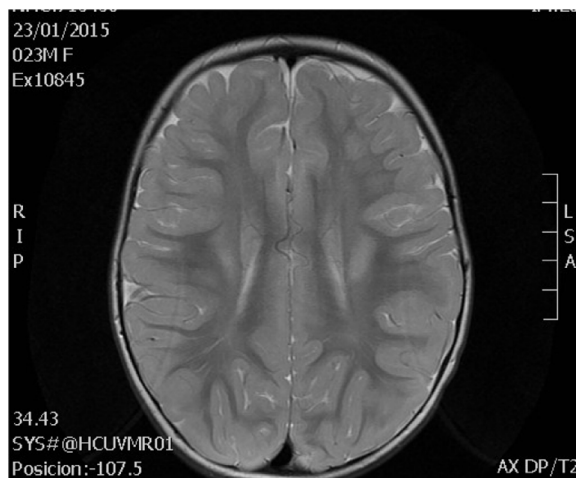


Figure 2 Changes in white matter at age 2 years, patient 1.

<sup>☆</sup> Please cite this article as: Villar-Vera C, Cuesta Peredo A, Monfort-Belenguer L, Abellán Sanchez MR, Martínez-Costa C. Síndrome de Sjögren-Larsson en España; descripción de 3 nuevos casos. *An Pediatr (Barc)*. 2021;95:203–204.