

Llu s Subirana Campos^{a,*}, Luis Renter Valdovinos^b,
Olga Oller Fradera^a, Lled  Garc s Montolio^a,
Julia G mez Rodr guez^a

^a Unidad de Transporte SEM Pedi trico y Neonatal (SEMPVH), Hospital Vall d'Hebron, Barcelona, Spain

^b Unidad de Cuidados Intensivos Pedi tricos, Corporaci  Sanitaria Parc Taul , Sabadell, Spain

* Corresponding author.

E-mail address: lsubirana@vhebron.net
(L. Subirana Campos).

<https://doi.org/10.1016/j.anpede.2020.08.007>
2341-2879/  2021 Published by Elsevier Espa a, S.L.U. on behalf
of Asociaci n Espa ola de Pediatr a. This is an open access article
under the CC BY-NC-ND license
(<http://creativecommons.org/licenses/by-nc-nd/4.0/>).

Sj gren-Larsson syndrome in Spain: Description of three new cases[ ]



S ndrome de Sj gren-Larsson en Espa a; descripci n de 3 nuevos casos

Dear Editor:

Sj gren-Larsson syndrome (OMIM #270200) is a neurocutaneous disorder characterised by congenital ichthyosis, intellectual disability and spasticity.¹ It is caused by changes in the *ALDH3A2* gene, which encodes the fatty aldehyde dehydrogenase (FALDH) enzyme, involved in the oxidation of aldehydes to fatty acids.^{2,3}

We described the different clinical and genetic characteristics of 3 cases diagnosed in our department.

Patient 1, a girl, was the first child of non-consanguineous parents with an unremarkable history. She was born at 36 weeks' gestation, exhibiting mild erythroderma that progressed to ichthyosis vulgaris (based on the findings of the skin biopsy) (Fig. 1).

She was referred to the paediatric neurology department at age 17 months due to severe axial hypotonia with instability in sitting and ichthyosis. The findings of the metabolic, neurophysiological and neuroimaging tests at the time were normal.

Although the patient did not present with additional signs of syndromic ichthyosis,⁴ comparative genomic hybridization testing was performed, which detected a 159.6 kb deletion in region 17p11.2, hg19 (chr17:19424245-19583843) that contained the *ALDH3A2* gene. Sequencing of the other *ALDH3A2* allele revealed a frameshift variant in exon 1 (c.86.96del, p.Ala29Aspfs*21) that gave rise to a truncated protein.

The segregation analysis of the family revealed that both changes were inherited (one from each parent).

A magnetic resonance imaging (MRI) scan performed at age 2 years found myelination defects (Fig. 2). Currently, at age 6 years, the patient has mild intellectual disability and axial hypotonia with spasticity in the lower extremities that precludes independent walking.

[ ] Please cite this article as: Villar-Vera C, Cuesta Peredo A, Monfort-Belenguer L, Abell n Sanchez MR, Mart nez-Costa C. S ndrome de Sj gren-Larsson en Espa a; descripci n de 3 nuevos casos. *An Pediatr (Barc)*. 2021;95:203–204.

The patient has experienced 5 episodes of typical febrile seizures that did not require antiepileptic medication. She has not developed vision abnormalities to date.

Patients 2 and 3 are sisters in a family with no known consanguinity. At birth, at 34 and 36 weeks' gestation, respectively, both presented with moderate ichthyosis described as "lamellar". They developed the ability to sit at around 9 months and independent walking between ages 4 and 6 years. Patient 2 retains independent walking at age 22 years. Both sisters developed signs of spasticity in the first 2 years of life, and Sj gren-Larsson syndrome was suspected due to the detection of myelination defects on neuroimaging.

Both patients developed typical febrile seizures, language delay and mild intellectual disability.

At ages 14 and 16 years, respectively, inclusions were detected in the ocular fundus.

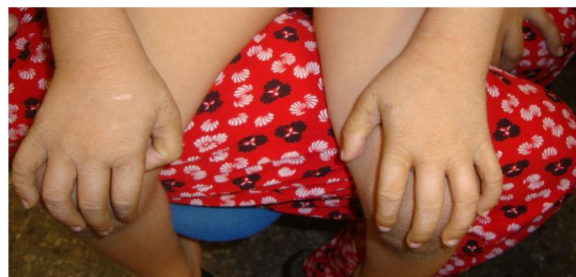

Figure 1 Mild ichthyosis at age 5 years, patient 1.

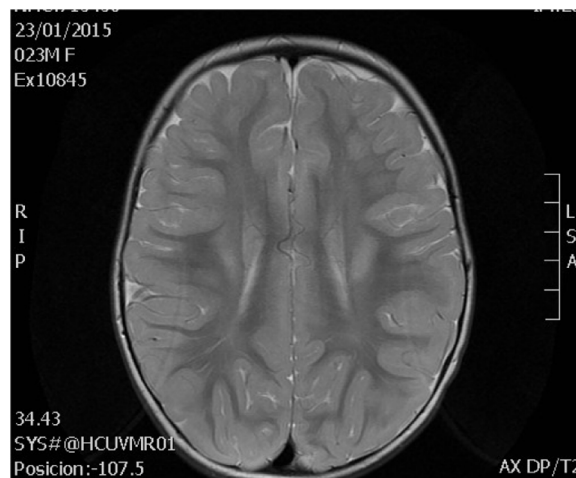


Figure 2 Changes in white matter at age 2 years, patient 1.

The diagnosis was based on enzyme activity assays in fibroblasts and sequencing of the *ALDH3A2* gene. Both patients were homozygous for the previously described variant c.471+1delG (NM_000382.2).

The family segregation analysis confirmed that both parents were carriers of the variant.

As of June 2020, there were 280 reported variants of the *ALDH3A2* gene in 182 individuals with Sjögren-Larsson syndrome (Leiden Open Variation Database [LOVD], PubMed). Some, like c.471+1delG, detected in patients 2 and 3, have been described in many European families. However, the variants detected in patient 1 were novel.⁵

A previous review of cases reported in Spain identified 4 cases diagnosed in adulthood after detection of the characteristic ocular or cutaneous lesions, and only 1 diagnosed in childhood.⁶

The c.86_96del variant produces a shift in the reading frame and results in a truncated protein. However, the presence of another start codon downstream suggests the possibility of a protein missing the first 32 amino acids (of the 508 of the full protein) that could maintain some residual activity and result in an attenuated phenotype.

We believe that it is important to be aware of the association of congenital ichthyosis with neurologic impairment as one of the known neuroichthyotic syndromes and of the presence of carriers of these variants in Spain to facilitate early diagnosis and the establishment of an accurate phenotype/genotype correlation. Patient 1, who had a deletion and a variant that had not been previously described presented with more severe axial hypotonia and milder ichthyosis compared to patients 2 and 3, who had a previously described variant.

References

1. Fuijkschot J, Theelen T, Seyger MMB, van der Graaf M, de Groot IJM, Wevers RA, et al. Sjögren-Larsson syn-

drome in clinical practice. *J Inherit Metab Dis.* 2012;35:955-62.

2. Rizzo WB, Carney G. Sjögren-Larsson syndrome: diversity of mutations and polymorphisms in the fatty aldehyde dehydrogenase gene (*ALDH3A2*). *Hum Mutat.* 2005;26:1-10.
3. Rizzo WB, Carney G, Lin Z. The molecular basis of Sjögren-Larsson syndrome: mutation analysis of the fatty aldehyde dehydrogenase gene. *Am J Hum Genet.* 1999;65:1547-60.
4. Rizzo W, Jenkins S, Boucher P. Recognition and diagnosis of neuro-ichthyotic Syndromes. *Semin Neurol.* 2012;32:075-84.
5. Weustenfeld M, Eidelpes R, Schmuth M, Rizzo W, Zschocke J, Keller M. Genotype and phenotype variability in Sjogren Larsson syndrome. *Hum Mutat.* 2019;40:177-86.
6. Mora-López F, Vilches-Moreno M, Marín-Iglesias R. Nueva mutación en el gen *ALDH3A2* en un niño con síndrome de Sjogren-Larsson. *Rev Neurol.* 2018;67:415-6.

Cristina Villar-Vera^{a,*}, Ana Cuesta Peredo^b, Lucía Monfort-Belenguer^a, María Rosario Abellán Sanchez^c, Cecilia Martínez-Costa^d

^a *Unidad de Neuropediatría, Servicio de Pediatría, Hospital Clínico Universitario de Valencia, Valencia, Spain*

^b *Laboratorio de Bioquímica y Patología Molecular, Hospital Clínico Universitario de Valencia, Valencia, Spain*

^c *Unidad de Genotipado y Diagnóstico Genético, Instituto de Investigación Sanitaria (INCLIVA), Valencia, Spain*

^d *Servicio de Pediatría, Hospital Clínico Universitario de Valencia, Valencia, Spain*

* Corresponding author.

E-mail address: crisvillarvera@gmail.com (C. Villar-Vera).

<https://doi.org/10.1016/j.anpede.2020.07.019>
2341-2879/ © 2021 Published by Elsevier España, S.L.U. on behalf of Asociación Española de Pediatría. This is an open access article under the CC BY-NC-ND license (<http://creativecommons.org/licenses/by-nc-nd/4.0/>).

Antenatal hydronephrosis: Key sign for the diagnostic of a familial genetic disease[☆]



Ectasia piélica antenatal: signo guía para el diagnóstico familiar de una enfermedad genética

Dear Editor:

Hepatocyte nuclear factor-1 beta (*HNF-1β*; genetic locus *17q12*) is involved in the development of several tissues in the organogenesis of the pancreas, liver and genitourinary system. Maturity-onset diabetes of the young (*MODY*)

and renal cysts¹ are the diseases in which the role of *HNF-1β* is well known, but its involvement in other congenital anomalies of the urinary tract is not well understood. These disorders follow an autosomal dominant pattern of inheritance. We present the case of a family affected by a variant of the *HNF1B* gene in which the index case was an infant that received an antenatal diagnosis of hydronephrosis manifesting with renal pelvis dilatation.

The patient was an infant aged 12 months followed up from month 1 post birth due to antenatal diagnosis of hydronephrosis with dilatation of the left renal pelvis and calyces categorised as grade 3-4 (Society for Fetal Urology classification).² The postnatal follow-up ultrasound scan confirmed the dilatation of the renal pelvis and calices, but also detected an abnormally small left kidney (2.5 SD below mean) with 2 cortical cysts, with a normal contralateral kidney. The personal history was otherwise unremarkable. The voiding cystourethrogram was normal and the ^{99m}Tc-MAG3 diuretic renogram found normal function in both kidneys and no evidence of obstruction. The follow-up ultrasound scan at 1 year post birth evinced kidneys of normal size other than the left-sided dilatation, but with bilateral hypere-

[☆] Please cite this article as: Alarcón-Alacio MT, Penela-Vélez de Guevara MT, Ballesteros-García MM, Rivero-Martín MJ. Ectasia piélica antenatal: signo guía para el diagnóstico familiar de una enfermedad genética. *An Pediatr (Barc).* 2021;95:204-206.