

## Induced atypical absence seizures during treatment with perampanel<sup>☆</sup>



### Inducción de crisis de ausencia atípica durante el tratamiento con perampanel

Dear Editor:

Perampanel (PER) is an antiepileptic drug approved for patients aged more than 12 years with partial and generalised tonic-clonic seizures. At present, the available data on their effectiveness in the management of absence seizures are scarce, and the number of patients aged less than 4 years included in these studies is negligible.<sup>1,2</sup> We present the cases of 3 children that developed atypical absence seizures at the time of initiation of PER.

**Case 1.** Girl aged 3 years with no history of interest with onset at age 2 years of progressive myoclonus epilepsy of unknown aetiology, with impairment predominantly of motor skills, ataxia and dysarthria. The patient did not respond to multiple antiepileptic drugs (valproic acid, levetiracetam, ethosuximide, phenytoin, lacosamide, topiramate, zonisamide, clobazam, piracetam and brivaracetam) or a ketogenic diet. Treatment with PER was initiated, reaching a total dose of 2 mg/day, in combination with brivaracetam, clobazam and piracetam. After 1 week she started experiencing frequent atypical absence seizures associated with episodes of progressive atony with a slow drooping of the head and trunk that were documented by video encephalography (VEEG). The patient experienced electroencephalographic resolution of the atypical absence seizures 1 week after discontinuation of PER.

**Case 2.** Girl aged 3 years and 2 months with Angelman syndrome. The patient presented with psychomotor delay and myoclonic seizures with onset at 12 months, and developed an epileptic encephalopathy electroencephalographic pattern with daily episodes of myoclonus refractory to antiepileptic drugs (levetiracetam, valproic acid and clobazam). Treatment with PER in combination with valproic acid and clobazam was initiated, reaching a maximum daily dose of 4 mg/day. The patient exhibited progressive general deterioration with continuous episodes of halts in activity accompanied by repetitive blinking, and VEEG monitoring revealed features of nonconvulsive status epilepticus (continuous atypical absence seizures). After discontinuation of PER, there was a decrease in the absence episodes, with evidence of electrographic improvement.

**Case 3.** Boy aged 1 year and 7 months with psychomotor delay from the early months of life of unknown aetiology. He had onset of epilepsy at age 6 months, with focal

hypomotor seizures and several forms of status epilepticus in the posterior cortex. The epilepsy was refractory to valproic acid, levetiracetam, clobazam, zonisamide, carbamazepine, lacosamide and the ketogenic diet. Treatment with PER was initiated in association with valproic acid, levetiracetam and clobazam. The patient reached a maximum dose of 2 mg/day. Perampanel was discontinued after 3 and a half months following evidence in VEEG of nonconvulsive status epilepticus with atypical absence seizures that disappeared after discontinuation of the drug (Fig. 1).

Changes in the concomitant treatments were not made in any of the patients, and none experienced any relevant side effects from these treatments.

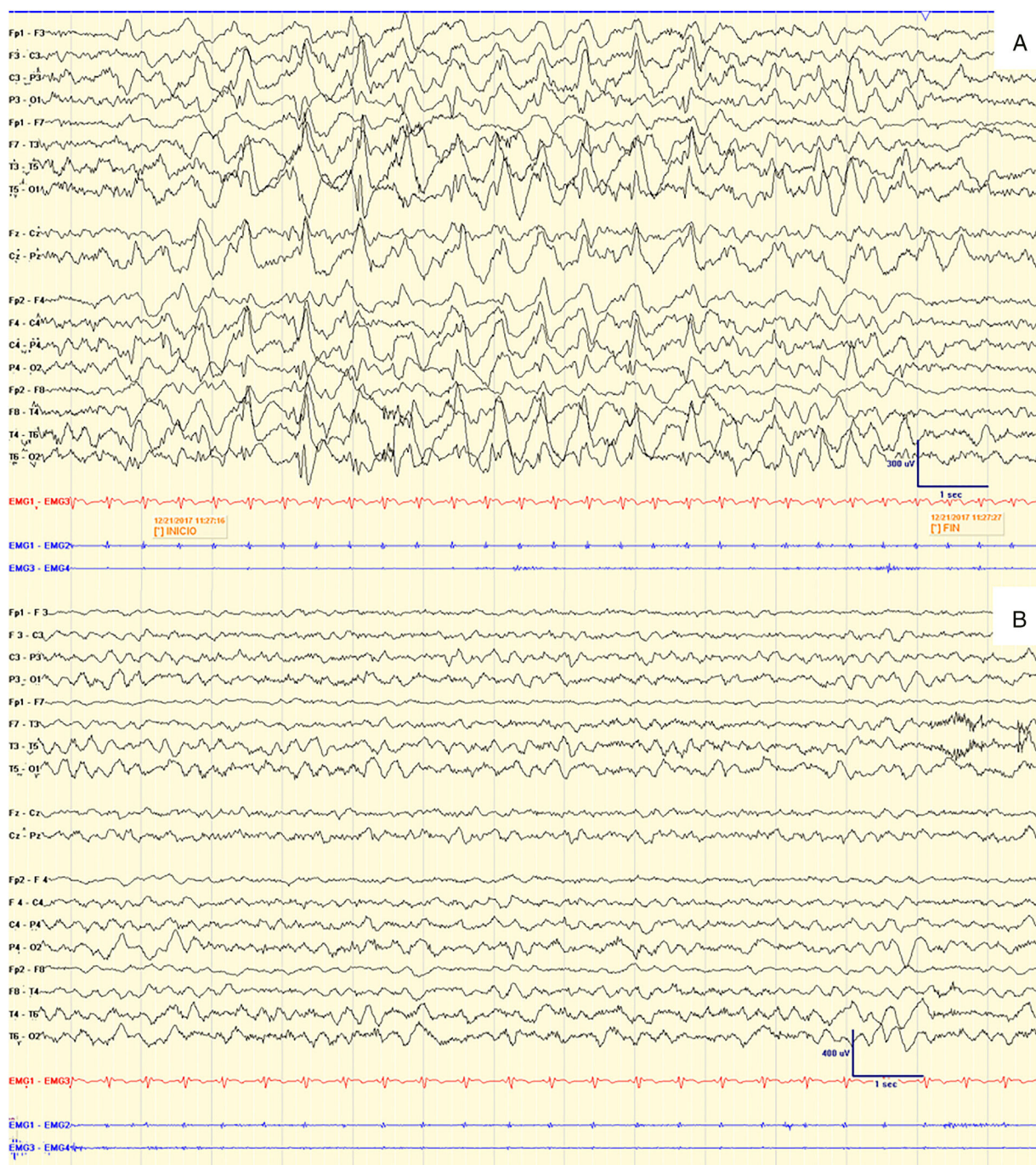
We did not find any reports in the literature of cases of development of atypical absence seizures with PER, but the paradoxical worsening of epilepsy induced by antiepileptic drugs is already a well-known complication.<sup>3</sup>

At present, the literature on the use of PER in the treatment of absence seizures is scarce. French et al.<sup>2</sup> included patients with absence seizures, and although they found no evidence that the drug exacerbated these seizures, they did not analyse the efficacy of PER against them.<sup>2</sup> Villanueva et al. included 37 patients with absence epilepsy, of whom only 7% experienced worsening.<sup>4</sup>

We believe that certain characteristics of our patients may have contributed to their clinical worsening. One was their age, as the study by Biro et al.<sup>5</sup> revealed a greater increase in seizures during treatment with PER in the 2- to 5-year age group. On the other hand, the data on the effectiveness of PER for treatment of atypical absence seizures are scarce. Swiderska et al.<sup>6</sup> analysed the efficacy of PER in 4 patients with atypical absence seizures, and none exhibited a reduction in the seizures. Biro et al.<sup>5</sup> included 4 patients with atypical absence seizures and found 2 patients that did not respond and 1 that experienced an exacerbation of these seizures.<sup>5</sup> Last of all, we think a relevant factor was that our patients had epilepsy refractory to drugs in addition to other unfavourable conditions. For instance, when Villanueva et al.<sup>4</sup> compared the outcomes of treatment with PER in patients with myoclonic seizures, they found a higher frequency of improvement compared to other studies that included patients with refractory epilepsy and other unfavourable conditions, such as progressive myoclonic epilepsy.<sup>4</sup>

The limitations of our study are significant due to its retrospective design and a small sample. However, we believe that contributing information from clinical experience is of great interest for the purpose of starting to profile the characteristics of patients at higher risk of experiencing worsening of specific seizures with PER.

<sup>☆</sup> Please cite this article as: Duat Rodríguez A, Cantarín Extremera V, García Fernández M, García Peñas JJ, Ruiz-Falcó Rojas ML. Inducción de crisis de ausencia atípica durante el tratamiento con perampanel. *An Pediatr (Barc)*. 2019;91:346–348.



**Figure 1** Electroencephalogram of case 3 during treatment with PER (A) and after discontinuation of PER (B). The top image (A) shows the ictal tracing during one of the episodes of reduced movement and changes in facial expression, associated with continuous mild blinking occurring every 5–10 s. The tracings show a slow, high-amplitude spike-wave activity, more or less rhythmical, diffuse and with predominance of the posterior regions pattern, with abrupt onset and end. At this time, the patient was receiving PER at a dose of 2 mg/day. The lower image (B) shows the interictal EEG 2 weeks later, after discontinuation of PER. The tracings reveal adequately organised wake activity, with a tendency towards slowing, without epileptiform abnormalities or asymmetries. There were no atypical absence seizures.

## References

1. Krauss GL, Perucca E, Kwan P, Ben-Menachem E, Wang XF, Shih JJ, et al. Final safety, tolerability, and seizure outcomes in patients with focal epilepsy treated with adjunctive perampanel for up to 4 years in an open-label extension of phase III randomized trials: study 307. *Epilepsia*. 2018;59:866–76.
2. French JA, Krauss GL, Wechsler RT, Wang XF, DiVentura B, Brandt C, et al. Perampanel for tonic-clonic seizures in idiopathic generalized epilepsy A randomized trial. *Neurology*. 2015;85:950–7.
3. Gayatri NA, Livingston JH. Aggravation of epilepsy by anti-epileptic drugs. *Dev Med Child Neurol*. 2006;48:394–8.
4. Villanueva V, Montoya J, Castillo A, Mauri-Llerdà JÁ, Giner P, López-González FJ, et al. Perampanel in routine clinical use in idiopathic generalized epilepsy: the 12-month GENERAL study. *Epilepsia*. 2018;59:1740–52.
5. Biro A, Stephani U, Tarallo T, Bast T, Schlachter K, Flegler M, et al. Effectiveness and tolerability of perampanel in children and adolescents with refractory epilepsies: first experiences. *Neuropediatrics*. 2015;46:110–6.
6. Swiderska N, Tan HJ, Rajai A, Silwal A, Desurkar A, Martland T. Effectiveness and tolerability of perampanel in children, adolescents and young adults with refractory epilepsy: a UK national multicentre study. *Seizure*. 2017;52:63–70.

Anna Duat Rodríguez<sup>a,\*</sup>, Verónica Cantarín Extremera<sup>a</sup>, Marta García Fernández<sup>b</sup>, Juan José García Peñas<sup>a</sup>, María Luz Ruiz-Falcó Rojas<sup>a</sup>

<sup>a</sup> Servicio de Neurología, Hospital Universitario Niño Jesús, Madrid, Spain

<sup>b</sup> Servicio de Neurofisiología, Hospital Universitario Niño Jesús, Madrid, Spain

\* Corresponding author.

E-mail address: [anna.duat@salud.madrid.org](mailto:anna.duat@salud.madrid.org)

(A. Duat Rodríguez).

2341-2879/

© 2019 Asociación Española de Pediatría. Published by Elsevier España, S.L.U. This is an open access article under the CC BY-NC-ND license (<http://creativecommons.org/licenses/by-nc-nd/4.0/>).

## An update of the recommendations of the spanish neonatology society for the use of palivizumab as prophylaxis for severe infections due to syncytial respiratory virus in high risk infants<sup>☆</sup>



### Recomendaciones de la sociedad española de neonatología para la utilización de palivizumab como profilaxis de las infecciones graves por el virus respiratorio sincitial en lactantes de alto riesgo, actualización

To the Editor:

Bronchiolitis, and in particular bronchiolitis caused by respiratory syncytial virus (RSV), is the leading cause of hospital admission in infants aged less than 1 year in Spain. Healthy infants born to term are the infants that require admission due to RSV bronchiolitis most frequently, however, infants in the at-risk group, that is, those born preterm, with bronchopulmonary dysplasia (BPD), with haemodynamically significant congenital heart defects, Down syndrome, neuromuscular disorders or velocardiofacial syndrome are at higher risk of developing severe disease.<sup>1</sup>

General preventive measures such as breastfeeding, hand hygiene and avoiding exposure to tobacco smoke or crowding

are essential. However, in the group of patients at highest risk of severe RSV infection, palivizumab continues to be the only drug authorised for pharmacological prophylaxis.

In 2014, the American Academy of Pediatrics (AAP) published new guidelines with particular emphasis on economic aspects calling for a significant restriction in the use of palivizumab prophylaxis, which have remained without changes in a recent publication.<sup>2</sup>

Recently, the Standards Committee of the Sociedad Española de Neonatología (Spanish Society of Neonatology, SENEo) concluded that the new guideline of the AAP did not contribute additional scientific evidence calling for any changes in the current recommendations for Spain. However, and with the aim of reducing the economic impact of palivizumab prophylaxis due to its high cost, the Committee proposed modifications to ensure its correct and rational use.<sup>3</sup>

There has been evidence of an increase in the incidence of severe disease due to RSV infection in inpatient populations, especially in infants born preterm, who in the past used to receive prophylaxis but stopped receiving it following the changes in the recommendations of the AAP in 2014, accompanied by a considerable increase in the costs associated with hospitalization.<sup>4</sup>

In this sense, the most drastic cut recommended by the AAP concerned the population of infants born preterm at or after 29 weeks' gestation. There is no question that this is a fairly large population, but it is one in which the proportion of RSV infections that produce severe disease requiring hospital admission is very high. For this reason, the Standards Committee of the SENEo<sup>3</sup> determined that there is a higher-risk group within this population that, if identified accurately, comprises patients that could benefit greatly from prophylaxis in both the short and the long term, as corroborated by recent evidence.<sup>5</sup>

The AAP, based on data from descriptive study,<sup>6</sup> determined that the use of risk factors as predictors in the

<sup>☆</sup> Please cite this article as: Sánchez Luna M, et al. Recomendaciones de la Sociedad Española de Neonatología para la utilización de palivizumab como profilaxis de las infecciones graves por el virus respiratorio sincitial en lactantes de alto riesgo, actualización. *An Pediatr (Barc)*. 2019;91:348–350.