



SPECIAL ARTICLE

## Point-of-care ultrasound: Is it time to include it in the paediatric specialist training programme?☆



Juan Mayordomo-Colunga<sup>a,b,r,1</sup>, Rafael González Cortés<sup>c,d,e,r,1</sup>,  
María Carmen Bravo<sup>f</sup>, Roser Martínez Mas<sup>g,s</sup>, José Luis Vázquez Martínez<sup>h,r</sup>,  
Luis Renter Valdovinos<sup>i,j,k,r</sup>, Thomas W. Conlon<sup>l</sup>, Akira Nishisaki<sup>l</sup>,  
Fernando Cabañas<sup>m,n</sup>, José Ángel Bilbao Sustacha<sup>o,t</sup>, Ignacio Oulego Erroz<sup>p,q,r,\*,1</sup>

<sup>a</sup> Sección de Cuidados Intensivos Pediátricos, Área de Gestión Clínica de Pediatría, Hospital Universitario Central de Asturias, Oviedo, Spain

<sup>b</sup> CIBER-Enfermedades Respiratorias, Instituto de Salud Carlos III, Madrid, Spain

<sup>c</sup> Grupo de trabajo de Ecografía de la Sociedad Española de Cuidados Intensivos Pediátricos (SECIP), Spain

<sup>d</sup> Unidad de Cuidados Intensivos Pediátricos, Hospital General Universitario Gregorio Marañón, Madrid, Spain

<sup>e</sup> Red de Salud Materno Infantil y del Desarrollo, RETICS financiada por el ISCIII (Ref. 16/0022), Madrid, Spain

<sup>f</sup> Departamento de Neonatología, Hospital Universitario La Paz, Madrid, Spain

<sup>g</sup> Servicio de Urgencias de Pediatría, Hospital Universitario Cruces, Barakaldo, Vizcaya, Spain

<sup>h</sup> Unidad de Cuidados Intensivos Pediátricos, Hospital Universitario Ramón y Cajal, Madrid, Spain

<sup>i</sup> Unidad de Cuidados Intensivos Pediátricos, Servicio de Medicina Pediátrica, Parc Taulí, Hospital Universitario, Sabadell, Barcelona, Spain

<sup>j</sup> Unidad de Transporte Pediátrico, Hospital Universitario Vall d'Hebron, Universitat Autònoma de Barcelona, Barcelona, Spain

<sup>k</sup> Base SEM-Pediátrico BP61, Sistema de Emergencias Médicas de Catalunya (SEM), Barcelona, Spain

<sup>l</sup> Department of Anesthesiology and Critical Care Medicine, Children's Hospital of Philadelphia and Perelman School of Medicine, University of Pennsylvania, Philadelphia, PA, United States

<sup>m</sup> Departamento de Pediatría y Neonatología, Hospital Universitario Quironsalud, Madrid, Spain

<sup>n</sup> Fundación de Investigación Biomédica, Hospital Universitario La Paz, Madrid, Spain

<sup>o</sup> Área Básica de Salud de Riudoms, Riudoms, Tarragona, Spain

<sup>p</sup> Cardiología Infantil, Unidad de Cuidados Intensivos Pediátricos, Servicio de Pediatría, Complejo Asistencial Universitario de León, León, Spain

<sup>q</sup> IBIOMED, Instituto de Biomedicina de León, León, Spain

<sup>r</sup> Grupo de Trabajo de Ecografía de la Sociedad Española de Cuidados Intensivos Pediátricos (SECIP), Spain

<sup>s</sup> Grupo de Trabajo de Ecografía a Pie de Cama de la Sociedad Española de Urgencias Pediátricas (SEUP), Spain

<sup>t</sup> Grupo de Trabajo de Ecografía Clínica de la Asociación Española de Pediatría de Atención Primaria (AEPAP), Spain

Received 20 June 2019; accepted 22 June 2019

☆ Please cite this article as: Mayordomo-Colunga J, González Cortés R, Bravo MC, Martínez Mas R, Vázquez Martínez JL, Renter Valdovinos L, et al. Ecografía a pie de cama: ¿es el momento de incluirla en la formación del pediatra? An Pediatr (Barc). 2019;91:208.

\* Corresponding author.

E-mail address: [ignacio.oulego@gmail.com](mailto:ignacio.oulego@gmail.com) (I. Oulego Erroz).

<sup>1</sup> The authors J.M.-C., R.G.C. and I.O.E. have contributed equally in this work.

**KEYWORDS**

Ultrasound;  
Echocardiography;  
Skills;  
Procedures;  
Emergencies;  
Intensive care;  
Patient safety;  
Venous  
catheterisation

**PALABRAS CLAVE**

Ecografía;  
Ultrasonidos;  
Ecocardiografía;  
Competencias;  
Procedimientos;  
Urgencias;  
Cuidados intensivos;  
Seguridad del  
paciente;  
Canalización vascular

**Abstract** Point-of-care ultrasound (POCUS) has become an essential tool for clinical practice in recent years. It should be considered as an extension of the standard physical examination, which complements and enriches it without substituting it. POCUS enables the physician to answer specific clinical questions about the diagnosis, to understand better the pathophysiological context, to orientate the treatment, and to perform invasive procedures more safely. Despite its current use in many centres, and in most paediatric sub-specialties, there are currently no specific recommendations addressing educational aims in the different training areas, as well as methodology practice and the certification process in paediatrics. These ingredients are essential for POCUS implementation in daily practice, with a quality guarantee in terms of efficiency and safety.

Several POCUS experts in different paediatric medicine environments performed a non-systematic review addressing the main paediatric POCUS applications in paediatrics. The lack of educational programmes in POCUS in Spain is also discussed, and the experience in the United States of America in this topic is provided.

Considering the current situation of POCUS in paediatrics, we strongly believe that it is urgent to establish evidence-based recommendations for POCUS training that should be the base to develop educational programmes and to include POCUS in the paediatric residency training.

© 2019 Published by Elsevier España, S.L.U. on behalf of Asociación Española de Pediatría. This is an open access article under the CC BY-NC-ND license (<http://creativecommons.org/licenses/by-nc-nd/4.0/>).

**Ecografía a pie de cama: ¿es el momento de incluirla en la formación del pediatra?**

**Resumen** La ecografía a pie de cama (EPC) se ha convertido en los últimos años en una herramienta imprescindible para la práctica clínica. La EPC debe entenderse como una extensión de la exploración física habitual que, sin sustituirla, la complementa y la enriquece. La EPC permite al clínico responder preguntas concretas sobre el diagnóstico, entender mejor la fisiopatología, orientar el tratamiento o realizar procedimientos invasivos con mayor seguridad. A pesar de su integración en muchos centros y en las diferentes subespecialidades pediátricas, no disponemos de recomendaciones específicas que establezcan los objetivos formativos en las distintas áreas de capacitación, la metodología de entrenamiento o la certificación de competencias en pediatría. Estos elementos son imprescindibles para que la EPC pueda implementarse en la práctica diaria con garantías de eficiencia y seguridad.

Este artículo aborda las principales aplicaciones de la EPC en pediatría mediante una revisión no sistemática por parte de expertos en diferentes áreas de la práctica clínica en España. Además, se discute acerca de la falta de planes formativos a nivel estatal, contando con la aportación de la experiencia de Estados Unidos.

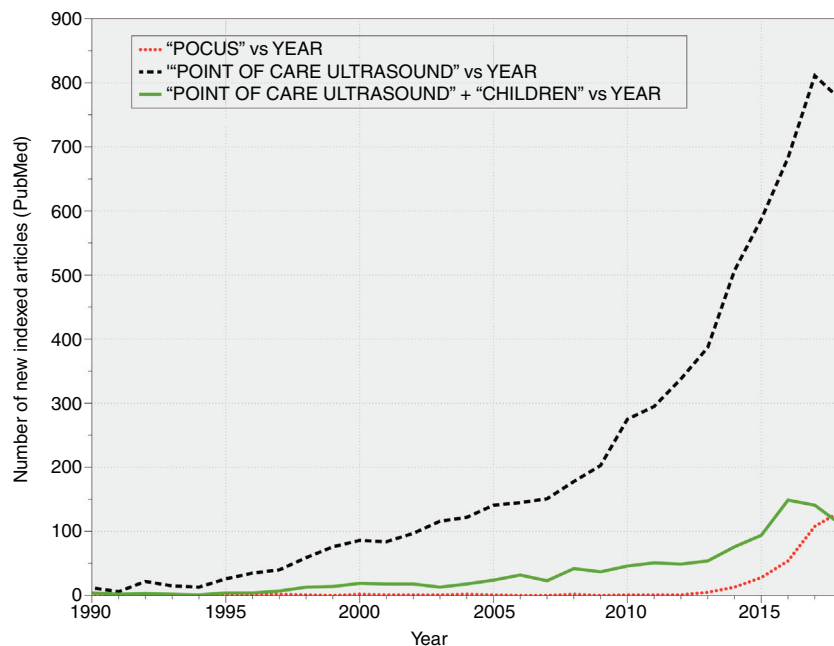
En vista de la situación actual de la EPC, en nuestra opinión es urgente que se establezcan recomendaciones basadas en la evidencia para el entrenamiento en EPC que sirvan como base para el desarrollo de planes formativos y la integración de la EPC en el programa formativo de la especialidad.

© 2019 Publicado por Elsevier España, S.L.U. en nombre de Asociación Española de Pediatría. Este es un artículo Open Access bajo la licencia CC BY-NC-ND (<http://creativecommons.org/licenses/by-nc-nd/4.0/>).

**Introduction**

Since its introduction in clinical practice in the mid-20th century, ultrasonography has been a valuable tool that allows non-invasive visualization of various anatomical structures. Its main advantage compared to other imaging tests is that it does not employ ionising radiation. Furthermore, it can be performed quickly and at the bedside (so that patients need not be moved), and it also allows serial imaging, which enables physicians to estimate the effectiveness of interventions prescribed

to patients without depending on other professionals. Although it is mainly practiced by radiologists, it has been decades since ultrasonography became an indispensable technique in other medical and surgical specialities, such as cardiology or gynaecology and obstetrics.<sup>1</sup> The use of ultrasonography by physicians not specialised in diagnostic imaging as an adjunct to the physical examination has been termed *bedside ultrasound* or *point-of-care ultrasound* (PoCUS).<sup>1</sup> While the use of PoCUS is not free of controversy and particularities,<sup>2,3</sup> it appears to be already established in clinical practice (Fig. 1), compelling



**Figure 1** Temporal trends in the publication of new articles on PoCUS indexed in PubMed (1990–2018).

several scientific societies to adopt clear positions on the matter.<sup>4,5</sup>

Due to the broad range of the existing paediatric subspecialties and the anatomical and pathophysiological characteristics of paediatric patients (clearly different from those of adults), the integration of PoCUS in paediatrics involves particular aspects that are not at play when it comes to its use in other fields of medicine.

At present, the educational curriculum for the speciality of paediatrics and its subspecialties in Spain falls under the authority of the Ministry of Health.<sup>6</sup> The current curriculum specifies that specialists in paediatrics must have the necessary skills to perform and interpret the diagnostic tests relevant to the practice of paediatrics, including echocardiography and other invasive techniques such as placement of central venous catheters, which requires ultrasound guidance.<sup>7</sup> In spite of this, training in PoCUS has not yet been defined specifically within this curriculum, nor in the White Book of Paediatric Specialities, except in the field of paediatric rheumatology.<sup>8</sup>

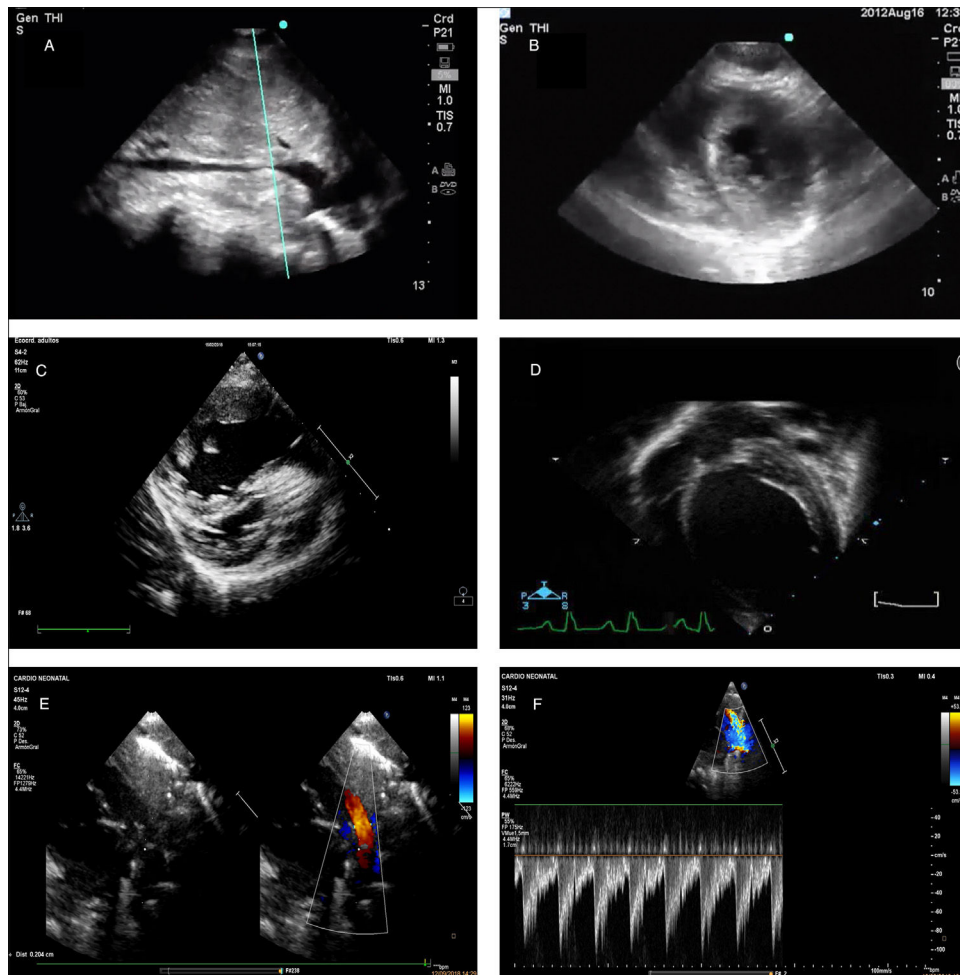
In the past decade, working groups have emerged within paediatric societies in Spain with the aim of promoting the use of PoCUS and providing education and conducting research on this technique.<sup>9,10</sup>

The aim of our article was to offer an overview of the use of PoCUS from the perspective of different fields in paediatrics, taking into account the various applications of this technique and the current training resources and needs in the field.

## Focused cardiac ultrasound

“Focused cardiac ultrasound” (FoCUS) is a widely accepted term to refer to the use of echocardiography performed by clinicians at the bedside for assessment of patients with signs or symptoms of haemodynamic compromise.<sup>11</sup>

Unlike standard echocardiography performed by a cardiologist, the goal of FoCUS is not a full anatomical or functional evaluation. In FoCUS, the clinician performs a simplified but systematic examination to try to obtain key information regarding the physiology of the haemodynamically unstable patient (why does the patient have low blood pressure? Would the patient benefit from administration of fluids? Would it be better to initiate inotropic therapy? [Fig. 2]) or to detect critical conditions such as cardiac tamponade. The routine FoCUS examination includes the subcostal window (long axis and inferior vena cava), the apical window and the parasternal window (long axis and short axis). The key elements of FoCUS are the assessment of the pericardium, the relative size of the chambers, systolic function and volume status. There is evidence that in patients with shock, FoCUS allows the detection of the predominant underlying mechanism (cardiogenic, obstructive or hypovolemic/distributive shock), leading to changes in management, reducing the delay in treatment initiation and improving outcomes<sup>12</sup> (Table 1). In addition, assessment of these patterns can lead to the identification of reversible causes of non-shockable cardiac arrest, and the presence or absence of organised cardiac activity is an important predictor of return of spontaneous circulation.<sup>13</sup> Clinical practice guidelines and scientific societies specify that training in FoCUS must be included in the core curriculum of medical specialties such as intensive care, anaesthesiology or emergency medicine, and that guidelines should be established as to how this training should be structured.<sup>11,14,15</sup> Although there is substantial variability in the educational methodology, most initiatives this far have promoted learning based on skill assessment and supervised individual practice with real-world patients with review of the obtained images, and highlighted the usefulness of e-learning tools.<sup>11</sup> International guidelines support the usefulness of PoCUS in paediatrics and provide



**Figure 2** Point-of-care ultrasound images corresponding to different clinical situations. (A) Inspiratory collapse of inferior vena cava, subcostal view. Sign indicative of hypovolemia in the context of compatible clinical manifestations. (B) Left ventricular systolic collapse, parasternal short axis view. Sign suggestive of hypovolemia in the context of compatible clinical manifestations. (C) Image compatible with dilatation of right ventricle and septal flattening suggestive of pulmonary hypertension. (D) Image showing dilatation of left ventricle in the context of haemodynamic instability, suggestive of severe ventricular dysfunction. (E) Large patent ductus arteriosus in preterm infant. (F) Doppler image at the level of the left pulmonary artery showing an increased end diastolic flow velocity, suggestive of increased pulmonary blood flow and haemodynamically significant patent ductus arteriosus.

recommendations for clinical practice.<sup>11,14</sup> Training in FoCUS is already a reality in the curriculum of certain paediatric specialties, such as paediatric intensive care and neonatology.<sup>16</sup> However, no consensus has been established to date on how paediatricians should be trained in FoCUS beyond the initiatives in individual institutions.<sup>17</sup> Therefore, we need to make a concerted effort to establish curriculum standards for training in FoCUS in the different paediatric subspecialties where it may be used.

### Point-of-care ultrasound in primary care

Despite the late introduction of PoCUS in primary care (PC), the technique has experiencing substantial grow in this setting in recent years.<sup>18</sup> The use of PoCUS has been introduced in everyday clinical practice in adult care in many primary care centres in Spain.<sup>19</sup> Point-of-care ultrasound could also be very useful to PC paediatricians. However,

its use in this field is still rare, probably due to a lack of training and continuing education resources, low staffing, heavy caseloads, the perception of encroachment on the scope of practice of other professionals and concerns regarding potential medico-legal issues. Nevertheless, there are initiatives such as the Working Group on Clinical Ultrasonography of the Asociación Española de Pediatría de Atención Primaria (Spanish Association of Primary Care Paediatrics, AEPAP) that seek to extend its use, promoting education and the diffusion of information among PC paediatricians.<sup>20</sup> An essential aspect to take into account in this particular setting is that the purpose of PoCUS is to explore specific clinical questions as opposed to performing a comprehensive anatomical assessment, with selective use for assessment of the most prevalent diseases in which it has demonstrated a superior effectiveness compared to the physical examination alone.<sup>19</sup> One obvious example is the diagnosis of community-acquired pneumonia.<sup>21</sup> Other situations in which PoCUS could lead to improved care are the diagnosis of

**Table 1** Summary of the main potential applications of point-of-care ultrasound in paediatric intensive care, highlighting the required level of training and the most frequent sonographic findings.

Clinical context	Application and level of training	Sonographic findings
CA <sup>12,13</sup>	Overall cardiac activity (A)	<ul style="list-style-type: none"> <li>• Pseudo-PEA: organised cardiac activity</li> <li>• Asystole-true PEA: absence of organised electrical activity ("cardiac standstill")</li> </ul>
Haemodynamic assessment <sup>11,14,15</sup>	Assessment of volume status (B) <ul style="list-style-type: none"> <li>• Size of heart chambers</li> <li>• Size and inspiratory collapse of inferior vena cava</li> </ul>	Hypovolemic/distributive shock <ul style="list-style-type: none"> <li>• Small "empty" chambers with tendency to collapse during systole (due to compensatory increased cardiac contractility)</li> <li>• Small IVC diameter with tendency to collapse with inspiration</li> </ul>
	Assessment of LV systolic function (B) <ul style="list-style-type: none"> <li>• LV size</li> <li>• Visual assessment of function</li> <li>• Inferior vena cava</li> </ul>	Cardiogenic shock <ul style="list-style-type: none"> <li>• Enlarged left ventricle (not always)</li> <li>• Subjective visual assessment of LV function ("eye-balling"): decreased overall systolic motion, reduced diastolic mitral valve leaflet excursion towards the septal wall, reduced to non-existent thickening of LV walls during systole.</li> </ul>
	Right ventricle size and pressure (B) <ul style="list-style-type: none"> <li>• Relative ventricle sizes</li> <li>• Septal curve</li> </ul>	Obstructive shock with RV failure/enlargement <ul style="list-style-type: none"> <li>• RV enlargement (RV:LV ratio &gt;0.6 in older children and &gt;1 in young children)</li> <li>• Interventricular septum bowing towards the left (increased RV pressure)</li> </ul>
Respiratory assessment <sup>1,8-16</sup>	Pericardium (B) <ul style="list-style-type: none"> <li>• Effusion</li> <li>• Compression of heart chambers</li> </ul>	Obstructive shock with cardiac tamponade <ul style="list-style-type: none"> <li>• Presence of pericardial effusion and diastolic collapse or right heart compression</li> <li>• LV underfilling and hypercontractility</li> </ul>
	Pleural effusion (B)	<ul style="list-style-type: none"> <li>• Identification and measurement of fluid collection in pleural cavity</li> <li>• Characteristics of effusion (complicated/uncomplicated)</li> </ul>
	Consolidation (B) Lung aeration and/or extravascular lung water (A) Detection of pneumothorax (B)	<ul style="list-style-type: none"> <li>• Hepatization of lung parenchyma, absence of signs of lung aeration</li> <li>• B-lines and consolidation/atelectasis (number, size and shape)</li> </ul>
Neurologic assessment	Diaphragm motion (A)	<ul style="list-style-type: none"> <li>• Absence of lung sliding.</li> <li>• Lung point sign</li> <li>• Absence of lung pulse and B-lines</li> </ul>
	Midline shift <sup>17</sup> (A)	Diaphragmatic excursion (B-mode and M-mode) Percent change in diaphragm thickness in inspiration Measurement of the distance from the transducer to the third ventricle from the left and right sides through the transtemporal window (under normal circumstances, they should be approximately the same)
	Transcranial Doppler <sup>1,18-28</sup> (A)	Assessment of cerebral blood flow: measurement of flow velocities in the vessels of the circle of Willis. Calculation of PI and RI Assessment of pupillary diameter and light reflex
Abdominal assessment (polytrauma)	Assessment of pupillary function (A) Optic nerve sheath <sup>29-32</sup> (A) eFAST <sup>33-35</sup> (B)	Increased diameter in context of increased ICP <ul style="list-style-type: none"> <li>• Detection de haemoperitoneum</li> <li>• Detection de haemopericardium</li> <li>• Detection de haemopneumothorax</li> </ul>
	Performance of ultrasound-guided procedures	
Performance of ultrasound-guided procedures	Vascular access <sup>1,36-40,41-43</sup> (B)	Ultrasound-guided insertion of arterial, central venous and peripheral venous catheters
	Endotracheal intubation (A)	Assessment of air column in trachea and oesophagus, lung sliding and endotracheal tube placement (TRUE protocol)
	Shunt placement <sup>1,44-52</sup> (A)	Ultrasound-guided procedures (thoracentesis, paracentesis and pericardiocentesis)
	Monitoring of urinary catheter <sup>35</sup> (B)	Bladder volume, catheter patency, assessment of placement and volume of catheter balloon

(A), advanced training; (B), basic training; CA, cardiac arrest; eFAST, extended focused assessment with sonography in trauma; ICP, intracranial pressure; IVC, inferior vena cava; LV, left ventricle; PEA, pulseless electrical activity; PI, pulsatility index; RI, resistance index; RV, right ventricle.

**Table 2** Summary of the main potential applications of point-of-care ultrasound in paediatric emergency care, primary care and inpatient care, highlighting the required level of training and the most frequent sonographic findings.

Clinical context	Application and level of training	Sonographic findings
Haemodynamic assessment Respiratory assessment Neurologic assessment Polytrauma assessment		See <a href="#">Table 1</a> on echocardiography in PICU setting
Abdominal assessment	Intussusception (B)	Target/doughnut sign Pseudokidney sign
	Appendicitis (A)	Diameter of appendix > 6 mm, noncompressible appendix, appendicolith Indirect signs: hyperechogenic surrounding fat, free fluid, collections of fluid around appendix (abscess)
	Hypertrophic pyloric stenosis (B)	Measurement of length of pyloric canal
	Cholecystitis (A)	Measurement of thickness of muscular layer Thickening and distension of gallbladder Detection of gallstones (calculous cholecystitis)
Musculoskeletal assessment	Hip dysplasia screening (A)	$\alpha$ angle (bony roof) $\beta$ angle (cartilaginous roof)
	Long bone and clavicle fractures (B)	Cortical disruption/step-off Posterior fat pad sign in supracondylar region
	Skull fractures (B)	Cortical disruption/step-off
	Joint effusion (B)	Detection of intra-articular fluid
Soft tissue assessment	Soft-tissue infection (B)	Cellulitis (subcutaneous oedema with cobblestone appearance, hyperaemia) Abscesses (anechoic fluid collection with no vessels inside, hypoechoic halo) Pyomyositis (muscular oedema with or without abscesses)
	Foreign body (B)	Detection of foreign body Identification of type of foreign body based on ultrasound artefacts
	Cervical mass (A)	Evaluation of lymphadenopathy Cystic vs solid cervical masses
	Assessment of bladder volume (B)	Assess for presence of urine Calculation of bladder volume (Volume = $0.52 \times$ maximum anteroposterior $\times$ transversal $\times$ longitudinal diameters)
Nephrourologic evaluation	Hydronephrosis (B)	Dilatation of renal pelvis and calyces, thinning of renal parenchyma Ureteral (dilatation (ureterohydronephrosis)
	Urolithiasis (A)	Detection of renal lithiasis Dilatation of urinary tract
	Testicular (A)	Assessment of testicular blood flow Testicular size and sonographic pattern (comparison with contralateral testis)
Ophthalmologic evaluation	Intraocular disease (A)	Detection of intraocular disease: detached retina, vitreous haemorrhage, etc.
	Vascular access (B) Thoracentesis (B)	Arterial, central venous and peripheral venous access Ultrasound-assisted puncture (identification of optimal puncture site) Ultrasound-guided puncture (small effusions near solid organs)
Ultrasound-guided/-assisted procedures <sup>1,9,26–28</sup>	Lumbar puncture (A)	Location of interspinous space for puncture (e.g. obesity) Visualization of epidural and subarachnoid spaces (newborns and infants)
	Reduction of fractures (B)	Post-reduction alignment of cortical bone
	Suprapubic puncture (B)	Verification of presence of urine. Selection of puncture site
	Arthrocentesis (B)	Ultrasound-assisted (identification of optimal puncture site)
	Abscess drainage/removal of foreign bodies (B)	Identification of optimal drainage site
	Confirmation of intraosseous vascular access (A)	Needle crossing cortex

(A), advanced training; (B), basic training.

soft-tissue infections (cellulitis vs abscesses), detection of joint effusion or screening of developmental dysplasia of the hip in infants (Table 2). We ought to underscore that the introduction of PoCUS in the practice of PC paediatrics requires adequate planning, not only in terms of material costs, but also by adapting the duration of visits to allow its correct use.

### Point-of-care ultrasound in speciality care, inpatient care and emergency care

Point-of-care ultrasound has been integrated progressively in inpatient paediatric care in the past few decades, with the strongest impact in paediatric emergency care.<sup>22</sup> The inclusion of PoCUS in the educational curriculum of emergency care paediatricians<sup>23</sup> and the position of the American Academy of Pediatrics in support of its use in this setting<sup>5</sup> have promoted the consolidation of PoCUS as an essential technique in paediatric emergency departments. Its use in this setting has been described relative to its use in inpatient care and other medical specialities.

Of the applications of PoCUS in the hospital setting (Table 2), the ones currently supported by an adequate amount of evidence include focused assessment with sonography for trauma (FAST), the detection of pneumonia, detection of fractures, assessment of soft tissues (cellulitis/abscesses) and guidance in the performance of interventions such as insertion of vascular catheters, reduction of fractures, lumbar puncture or suprapubic puncture.<sup>5,24</sup> Research has also been conducted on the use of PoCUS in other situations (abdominal complaints, bronchiolitis, presence of foreign bodies, joint effusion and cervical masses), although the evidence published to date is scarce. In any case, when it comes to the introduction of PoCUS, each facility needs to determine which applications would be most beneficial based not only on the current evidence, but also on its specific needs and available resources.

Training in PoCUS is widely available in the form of courses, books and online materials.<sup>25</sup> However, the lack of nationwide hospital-based training programmes hinders the acquisition of practical skills, which depends largely on the availability of sonographers and experienced staff. In this regard, future efforts should focus on the consolidation of hospital-based training programmes in PoCUS to promote a more comprehensive and standardized education on the technique.

### Point-of-care ultrasound in paediatric intensive care:

The use of PoCUS in paediatric intensive care units (PICUs) has grown considerably in the past few years.<sup>7,26</sup> Several authors claim that its use in the PICU improves clinical assessment, leads to changes in management in up to 40% of patients<sup>27</sup> and increases the safety of invasive procedures.<sup>28</sup> In the field of adult intensive care, there are already consensus guidelines for training in ultrasound published by medical societies in related fields,<sup>4,14</sup> including some recommendations for paediatric patients.<sup>14</sup>

The main applications of PoCUS in the PICU include (Table 1):

- FoCUS: already described in the section on echocardiography (Fig. 2).
- Lung ultrasound: Allow ruling out/diagnosis of pneumothorax and detection of lung consolidation and pleural effusion (Fig. 3). It is also useful for detection of diaphragmatic paresis/paralysis and to verify endotracheal tube placement.<sup>29</sup>
- Neurosonology: estimation of intracranial pressure and its effects by transcranial Doppler ultrasound, measurement of optic nerve sheath diameter.<sup>26</sup> It is also useful to assess midline shift in space-occupying lesions.
- Abdomen: Mainly detection of free fluid with the FAST protocol.<sup>30</sup> It is also useful to monitor urinary catheters and the condition of the bladder in cases of anuria.
- Ultrasound-guided procedures: vascular catheter placement<sup>9</sup> (Fig. 4), paracentesis, pericardiocentesis, thoracentesis/chest tube insertion.<sup>9</sup>

A key aspect in the use of sonography in the PICU is training, and to this date a standardized educational programme has not been established. Conlon et al. proposed a 16-hour theoretical and practical training programme followed by correct performance of a minimum of 25 studies in non-procedural applications (haemodynamic, thoracic and abdominal assessment) to assess competence in these skills,<sup>17</sup> which is similar to the recommendations of the American College of Emergency Physicians.<sup>15</sup> However, in our experience and that of other authors,<sup>4</sup> the number of supervised ultrasound studies varies significantly between individuals, making it difficult to estimate an appropriate minimum number.

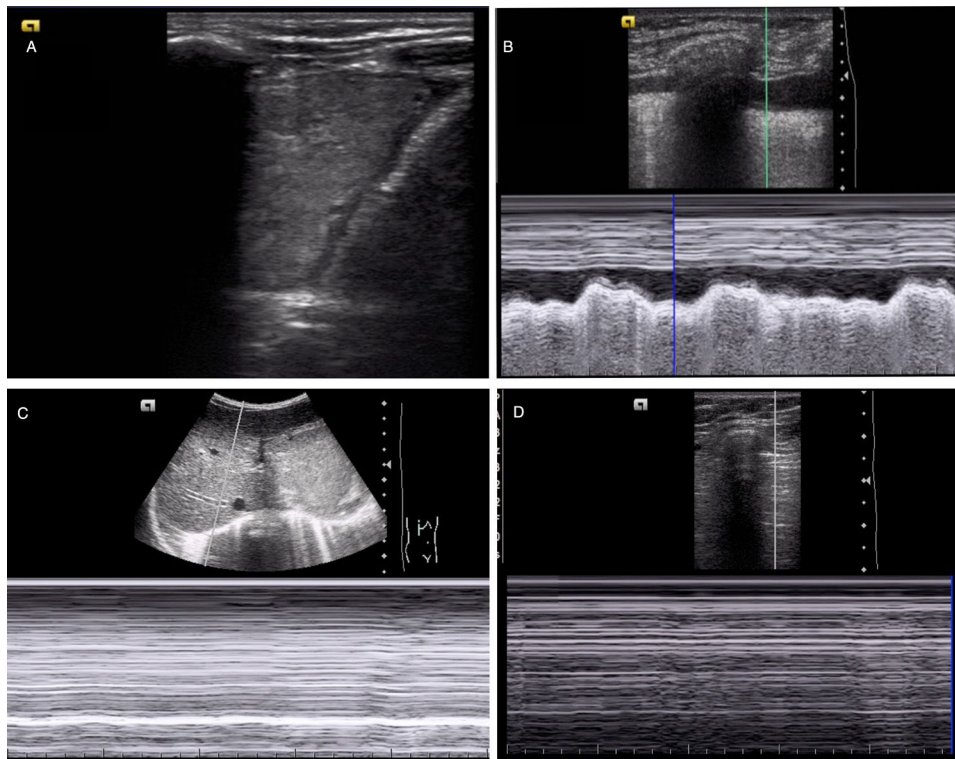
The consensus guidelines for training in adult intensive care sonography in Spain suggests different levels of training and specifies the different requirements for the main applications of PoCUS in this field. The basic level includes: lung ultrasound, ultrasound-guided vascular access, abdominal ultrasound, transcranial doppler ultrasound and basic echocardiography.<sup>4</sup>

The ultimate objective is to design a longitudinal curriculum with several training stages detailing the use of simulation, the number of ultrasound studies required for practice and the exams to be performed for certification and recertification in the overall use of sonography or specific applications, in addition to the development of a system for instructor accreditation.<sup>4,31</sup> This calls for the development of guidelines and recommendations by the Working Group of the Sociedad Española de Cuidados Intensivos Pediátricos (Spanish Society of Paediatric Intensive Care, SECIP).

### Point-of-care ultrasound in newborn infants

At present, PoCUS is an indispensable diagnostic tool in neonatal units, where the advantages that we have already mentioned allow its use in this vulnerable subset of patients.

It is mainly used for evaluation of the brain, heart, abdomen and lungs and performance of ultrasound-guided procedures (Table 3).



**Figure 3** Diagnosis of different respiratory diseases by means of PoCUS. (A) Lung consolidation associated with pleural effusion. (B) Identification of pleural effusion on M-mode (sinusoid sign). (C) Evaluation of diaphragm motion in M-mode, with absence of diaphragmatic excursion (compatible with diaphragm paresis). (D) Absence of lung sliding in M-mode, suggestive of pneumothorax (stratosphere/barcode sign).

Transcranial Doppler ultrasound (Fig. 5): allows detection of brain lesions using different acoustic windows (anterior, posterior, mastoid and temporal fontanelles), offering information useful for diagnosis and prognosis. Serial studies allow assessment of brain maturation in preterm infants to determine whether it is adequate, and it is an essential tool in the identification of the aetiology of structural lesions.<sup>32</sup>

1. Echocardiography: it assesses the structure and function of the heart. Functional echocardiography can be used to measure rapid haemodynamic changes in the newborn and assess response to treatment (Fig. 2). The concept of neonatologist-performed echocardiography (NPE) has been gaining ground in neonatal units in the past 20 years, advancing the notion that neonatologists are the professionals best suited to evaluate haemodynamic function in infants with a structurally normal heart (with no evidence of congenital heart defects, excluding patent foramen ovale and patent ductus arteriosus).<sup>33</sup>
2. Chest ultrasound: assessment for presence of pneumothorax, pleural effusion, lung consolidation or atelectasis.<sup>29,34</sup>
3. Abdominal ultrasound: assessment of malformations of abdominal organs, ascites, splanchnic haemodynamic changes and placement of urinary catheters.
4. Insertion and assessment of placement of intravascular catheters: useful to reduce the risk of complications associated with central venous catheter insertion,

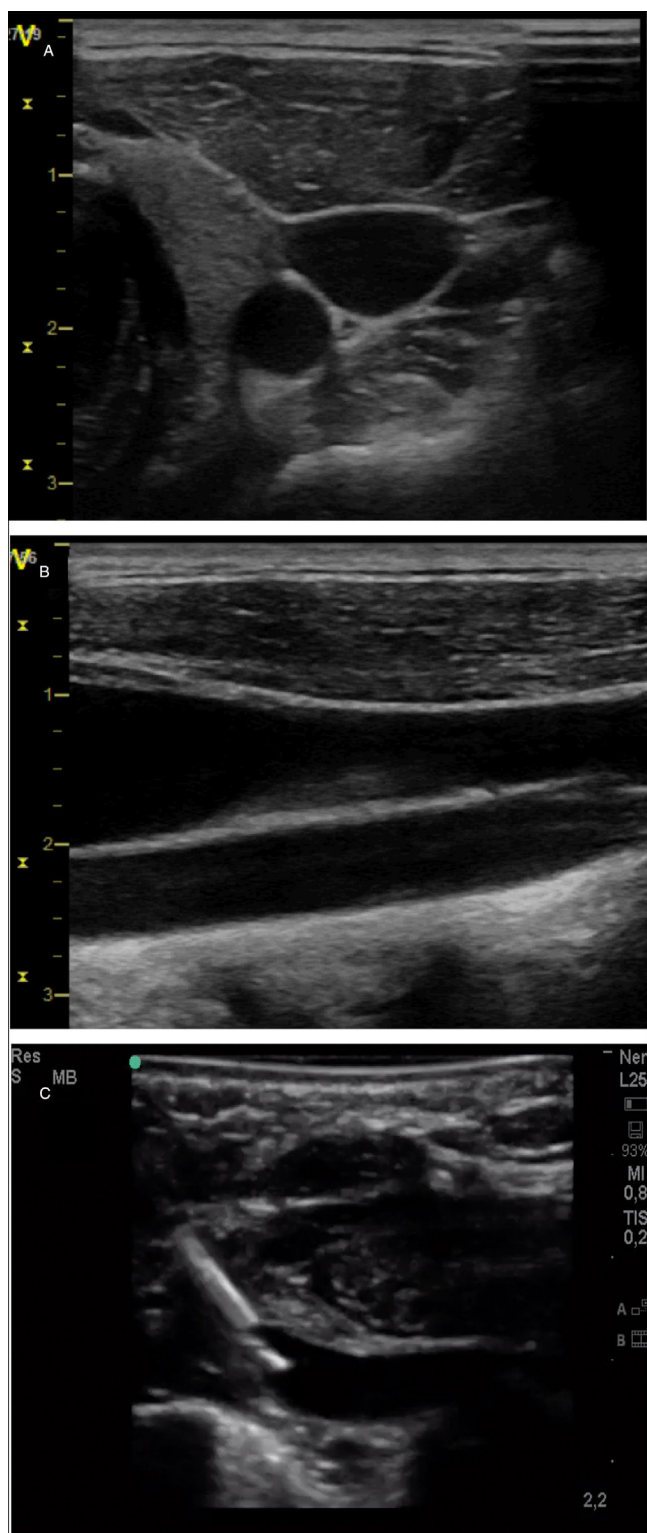
including in very-low-birthweight newborns, and to verify correct placement of the catheter.<sup>35</sup>

### Point-of-care ultrasound training in the United States

In the United States (US), paediatric ultrasound imaging has traditionally belonged to the scope of radiology and cardiology subspecialty practice. Adult emergency care physicians recognized the importance of integrating point-of-care ultrasound (POCUS) in their practice and representative societies supported its clinical use in the 1990s, followed by the publication of the first guidelines on the subject in 2001.<sup>15</sup> Diagnostic and procedural ultrasound training is now a required component of training in emergency medicine residency and adult critical care fellowship programmes.<sup>36</sup>

Paediatric specialists in the US have followed the lead of their peers in adult medicine. In 2015, the American Academy of Pediatrics endorsed broadening the scope of ultrasound practice to include paediatric emergency care providers.<sup>5</sup> The Society of Critical Care Medicine recently supported guidelines for use of POCUS in critical care that included a narrow range of paediatric diagnostic and procedural applications. The applications, training and credentialing processes relevant to paediatric critical care medicine (PCCM) have been described in the literature.<sup>17</sup> Furthermore, a 2017 survey of PCCM programmes accredited in the US by the Accreditation Council for Graduate Medical Education found that 64% included practice of diagnostic





**Figure 4** Exploration of cervical vessels by means of PoCUS. (A) Transversal view of vessels, with identification of carotid artery as a round hypoechoic structure and the jugular vein as an oval, more superficial hypoechoic structure. (B) Longitudinal view of the vessels, with identification of jugular vein in a more superficial level and the carotid artery in a deeper level. (C) Subclavian vein cannulation in a newborn infant with a long-axis/in-plane approach.

POCUS and 98% offered access to ultrasound machines.<sup>37</sup> In 2011, The American Society of Echocardiography (ASE), in collaboration other societies in Europe, published practice guidelines and recommendations for targeted neonatal echocardiography training.<sup>38</sup> These guidelines have been criticized as overly prescriptive and the training requirements unfeasible for neonatal specialists.<sup>39</sup> More recently, the ASE has recognized the clinical benefit of “focused cardiac ultrasound,” defined as “an adjunct to the physical examination to recognize specific ultrasonic signs,” though the scope of these recommendations is limited to adult care.

Bedside ultrasound providers across paediatric specialties continue to work on standardizing the training curriculum, offering training, developing competency, structuring quality assurance and creating paths for institutional credentialing. Such structural elements have been successful in advancing adult emergency medicine POCUS programmes,<sup>15</sup> but have yet to be established in paediatric specialties.<sup>17</sup> Medical liability concerns are often identified as barriers to the integration of POCUS in clinical practice in the US, even though both the adult and paediatric medical literature suggest that not performing ultrasound examinations when the technology is available puts providers at greater risk of medico-legal problems.<sup>3</sup> In 2012, a survey of US medical schools found that 62% of responding institutions included ultrasound training in their curricula.<sup>40</sup> Thus, a generation of medical students that have already been trained in the use of ultrasound will soon be pursuing careers in paediatrics. Integrating clinical knowledge and experience with POCUS technology in the next generation of paediatric providers will be an exciting challenge in paediatric clinical practice in the US.

## Discussion and conclusions

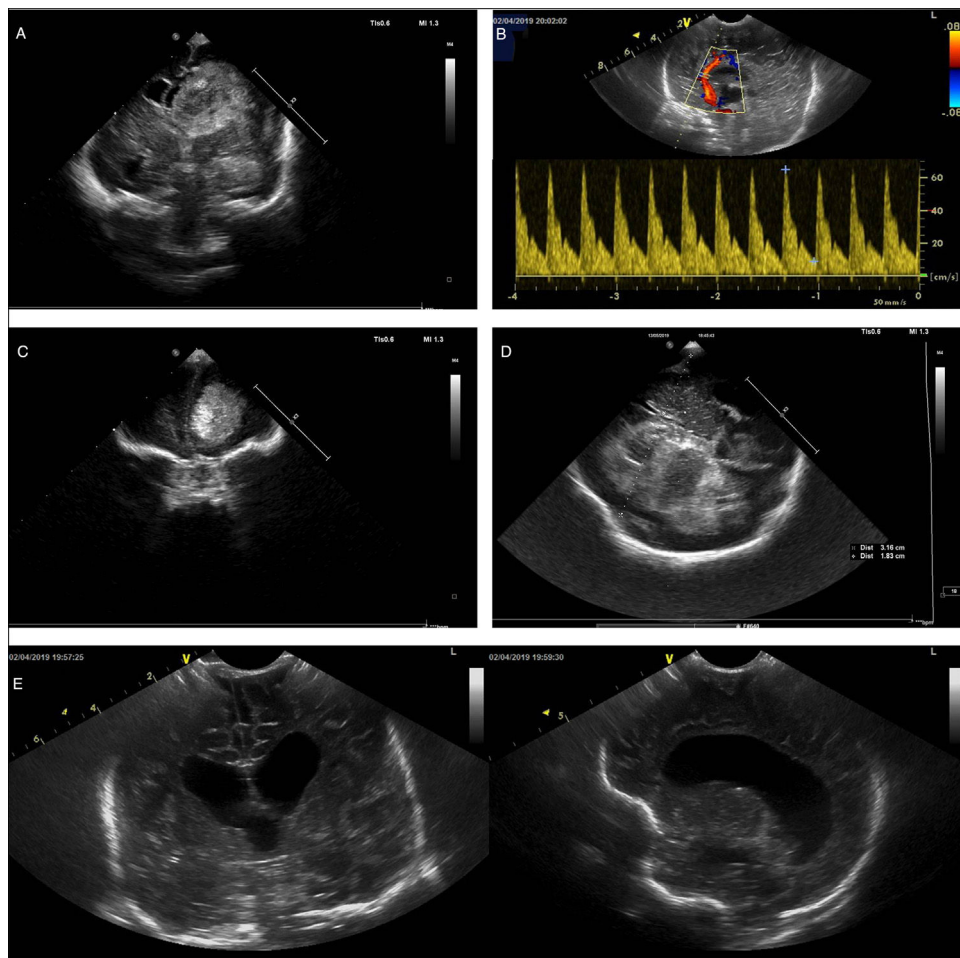
This article aimed at offering a multidisciplinary perspective on the use of PoCUS in different fields within paediatrics. To do so, we engaged the collaboration in developing the manuscript of paediatricians in different paediatric subspecialties that have played key roles in the introduction and diffusion of PoCUS in Spain (and in the United States).<sup>7,9,10,17</sup> We ought to highlight that while this article includes numerous references to the current scientific evidence in support of the use of PoCUS in paediatrics, we did not carry out a systematic review and meta-analysis of the scientific literature on the applications proposed in this article, especially as regards their classification as basic or advanced.

The use of PoCUS, a non-invasive, safe, repeatable technique that can be useful in everyday clinical practice if performed by a skilled individual, is already widespread in different fields in paediatrics in several countries, including Spain.<sup>5,7</sup> Some international guidelines include recommendations for use in paediatrics, for instance for lung ultrasound in critical paediatric patients or for FoCUS.<sup>11,29</sup> However, with the exception of its use in paediatric emergency care in the United States,<sup>5,23</sup> there are no clinical guidelines specifying the basic applications of PoCUS in the field of paediatrics or how training on this technique should be delivered and accredited. We believe that this is a key aspect for the adequate introduction of PoCUS, whose application, as is the case of other methods, requires adequate

**Table 3** Summary of the main potential applications of point-of-care ultrasound in neonatal care, highlighting the required level of training and the most frequent sonographic findings.

Clinical context	Application and level of training	Sonographic findings
Haemodynamic assessment <sup>10,33,38</sup>	CO and SVC flow (A)	<ul style="list-style-type: none"> <li>• Measurement of LVOT, RVOT and SVC diameters.</li> <li>• Measurement of velocity-time integral</li> </ul>
	Systolic and diastolic function in each ventricle (A)	<ul style="list-style-type: none"> <li>• Ejection fraction and fractional shortening, tissue Doppler, strain (left ventricle)</li> <li>• TAPSE, tissue Doppler, FAC (right ventricle)</li> <li>• E/A ratio and tissue Doppler (filling pressure)</li> </ul>
	Assessment of PDA (pulmonary overcirculation and/or systemic hypoperfusion) (A)	<ul style="list-style-type: none"> <li>• Ductus diameter &gt; 1.5 mm or 1.4 mm/kg, pulsatile pattern and/or low flow velocity (&lt;1.5 m/seg) are indicative of Hs-PDA</li> <li>• DV in LPB (&gt;0.2 m/seg in end diastole indicative of overcirculation), LA/Ao ratio (&gt;1.4, suggests LA enlargement), mitral flow E/A ratio (E &gt; A indicates an increase in filling pressure), left CO/SVC flow ratio (&gt;4 is indicative of a significant shunt), DV in postductal arteries ("diastolic steal" indicative of peripheral hypoperfusion).</li> </ul>
	Assessment of pulmonary flows (A)	<ul style="list-style-type: none"> <li>• Direction of shunt in ductus and foramen (bidirectional or right-left)</li> <li>• Peak TR velocity (estimation of pulmonary pressure)</li> <li>• Leftward shift of interventricular septum</li> <li>• Doppler pattern and pulmonary acceleration time</li> </ul>
	Presence of pericardial effusion (B)	<ul style="list-style-type: none"> <li>• Detection of fluid collection in pericardial cavity</li> <li>• Signs of compression of right side of heart</li> </ul>
Neurologic assessment <sup>32</sup>	Confirmation of normal anatomy (B)	<ul style="list-style-type: none"> <li>• Confirmation of symmetry</li> <li>• Assessment of midline</li> </ul>
	Structural lesion (ischaemic or haemorrhagic) (A)	<ul style="list-style-type: none"> <li>• Intraventricular haemorrhage, periventricular infarction, arterial infarction, parenchymatous haemorrhage, extra-axial bleeding.</li> </ul>
	Diagnosis of venous and arterial strokes. Assessment of dural venous sinuses (A)	<ul style="list-style-type: none"> <li>• Measurement of flow velocity in anterior cerebral, middle cerebral and carotid arteries.</li> <li>• Calculation of PI and RI.</li> <li>• Confirmation of patency of dural venous sinuses.</li> </ul>
	Pattern of brain maturation in preterm infants. Assessment of white matter lesions (A)	<ul style="list-style-type: none"> <li>• Monitoring of periventricular echogenicity, ventricular size and extra-axial spaces as markers of white matter injury</li> </ul>
Respiratory and abdominal assessment <sup>34</sup>	Assessment of hydrocephalus (A)	<ul style="list-style-type: none"> <li>• Levene index, diameters of frontal horn, third ventricle and fourth ventricle, thalamo-occipital distance</li> </ul>
	Assessment of pneumothorax (B)	<ul style="list-style-type: none"> <li>• Absence of lung sliding or equivalent signs</li> <li>• Lung point sign</li> </ul>
	Pleural effusion or excess abdominal fluid (B)	<ul style="list-style-type: none"> <li>• Detection of excess fluid in pleural space</li> <li>• Detection of free fluid in abdomen</li> </ul>
	Lung consolidation (B)	<ul style="list-style-type: none"> <li>• Hepatization of lung parenchyma</li> <li>• Absence of signs of lung aeration</li> </ul>
Ultrasound-guided procedures <sup>35</sup>	Assessment of lung aeration (A)	<ul style="list-style-type: none"> <li>• Presence of B-lines and consolidation/atelectasis (number, size and shape)</li> </ul>
	Thoracentesis/paracentesis (B)	<ul style="list-style-type: none"> <li>• Identification of site for needle access and fluid drainage</li> </ul>
	Vascular access (B)	<ul style="list-style-type: none"> <li>• Ultrasound-guided puncture and assessment of position of CVC tip</li> </ul>

(A), advanced training; (B), basic training; CO, cardiac output; CSF, cerebrospinal fluid; CVC, central venous catheter; DV, diastolic velocity; E/A, early filling (E) wave to atrial contraction (A) wave ratio; FAC, fractional area change; Hs, haemodynamically significant; LA/Ao, left atrial to aortic root ratio; LPB, left pulmonary branch; LVOT, left ventricular outflow tract; PDA, patent ductus arteriosus; PI, pulsatility index; RI, resistance index; RVOT, right ventricular outflow tract; SVC, superior vena cava; TAPSE, tricuspid annular plane systolic excursion; TR, tricuspid regurgitation.



**Figure 5** Brain examinations performed by means of PoCUS in newborn infants. (A) Coronal plane, hypoechoic image compatible with intraventricular haemorrhage with midline shift. (B) Doppler ultrasound image of pericallosal artery in a patient with decompensating hydrocephalus revealing increased resistance (pulsatility index, 1.94) compatible with increased intracranial pressure. (C) Coronal view showing a hyperechoic lesion in the frontal region. (D) Ultrasound image obtained through the transtemporal window showing a hyperechoic lesion compatible with haemorrhage with midline shift. (E) Coronal view (left) and sagittal view (right) of a newborn infant with meningitis, with detection of ventriculomegaly.

knowledge of the technique and its limitations, and must always fit the clinical situation of the patient. Disregarding these prerequisites could lead to mistakes in clinical decision-making and have a negative impact on patients.<sup>1</sup>

An essential aspect that must be underscored is that PoCUS is to be used as an adjunct to the customary clinical evaluation to address specific questions relevant to the management of the patient, and never in place of a comprehensive ultrasound evaluation by the cardiologist or radiologist when one is needed.

Some authors have reported that the learning curve for some ultrasound applications is relatively quick, so that only a few additional ultrasound studies need to be performed after theoretical and practical training for an adequate educational outcome.<sup>17,37</sup> Another advantage of PoCUS is that several of its applications are used across subspecialties, as is the case of lung ultrasound.

In light of all of the above, we advise the definition of a minimum set of PoCUS applications that ought to be included in the educational curriculum of medical

residencies in paediatrics at different levels of care and its different subspecialties. This should be accompanied by the establishment of criteria for the maintenance of these competencies, such as the minimum number of PoCUS studies that must be performed per year.

Another necessary step is for the different paediatric societies in Spain and Europe to establish their positions regarding the use of PoCUS, which would foster the development of specific training programmes and thus promote a more widespread and better integration of this technique in clinical practice.

Last of all, further evidence is required on the use of PoCUS in different fields within paediatrics for the purpose of establishing clear recommendations for its use as well as adequate educational programmes.

### Conflicts of interest

The authors have no conflicts of interest to declare.

## References

- Moore CL, Copel JA. Point-of-care ultrasonography. *N Engl J Med*. 2011;364:749–57.
- Blaivas M, Pawl R. Analysis of lawsuits filed against emergency physicians for point-of-care emergency ultrasound examination performance and interpretation over a 20-year period. *Am J Emerg Med*. 2012;30:338–41.
- Nguyen J, Cascione M, Noori S. Analysis of lawsuits related to point-of-care ultrasonography in neonatology and pediatric subspecialties. *J Perinatol*. 2016;36:784–6.
- Ayuela Azcárate JM, Clau-Terré F, Vicho Pereira R, Guerrero de Mier M, Carrillo López A, Ochagavía A, et al. Documento de consenso para la formación en ecografía en Medicina Intensiva. Proceso asistencial, uso de la técnica y adquisición de competencias profesionales. *Med Intensiva*. 2014;38:33–40.
- Marin JR, Lewiss RE, American Academy of Pediatrics, Committee on Pediatric Emergency Medicine; Society for Academic Emergency Medicine, Academy of Emergency Ultrasound; American College of Emergency Physicians, Pediatric Emergency Medicine Committee; World Interactive Network Focused on Critical Ultrasound. Point-of-care ultrasonography by pediatric emergency medicine physicians. *Pediatrics*. 2015;135:e1113–22.
- Ministerio de Sanidad y Consumo. Orden SCO/3148/2006, de 20 de septiembre, por la que se aprueba y publica el programa formativo de la especialidad de Pediatría y sus Áreas Específicas. BOE-A-2006-17999.
- González Cortés R, Renter Valdovinos L, Coca Pérez A, Vázquez Martínez JL. Ecografía en el punto de cuidado en las unidades de cuidados intensivos pediátricos españolas. *An Pediatr (Barc)*. 2017;86:344–9.
- Libro blanco de las Especialidades Pediátricas. *Rev Pediatr Aten Primaria*. 2012;14:279–80.
- Oulego-Erroz I, González-Cortés R, García-Soler P, Balaguer-Gargallo M, Frías-Pérez M, Mayordomo-Colunga J, et al. Ultrasound-guided or landmark techniques for central venous catheter placement in critically ill children. *Intensive Care Med*. 2018;44:61–72.
- Bravo MC, López-Ortego P, Sánchez L, Riera J, Madero R, Cabañas F, et al. Randomized placebo-controlled trial of dobutamine for low superior vena cava flow in infants. *J Pediatr*. 2015;167:572–80.
- Via G, Hussain A, Wells M, Reardon R, ElBarbary M, Noble VE, et al. International evidence-based recommendations for focused cardiac ultrasound. *J Am Soc Echocardiogr*. 2014;27:683.e1–33.
- Breitkreutz R, Price S, Steiger HV, Seeger FH, Ilper H, Ackermann H, et al. Focused echocardiographic evaluation in life support and peri-resuscitation of emergency patients: a prospective trial. *Resuscitation*. 2010;81:1527–33.
- Lalande E, Burwash-Brennan T, Burns K, Atkinson P, Lambert M, Jarman B, et al. Is point-of-care ultrasound a reliable predictor of outcome during atraumatic, non-shockable cardiac arrest? A systematic review and meta-analysis from the SHoC investigators. *Resuscitation*. 2019;139:159–66.
- Levitov A, Frankel HL, Blaivas M, Kirkpatrick AW, Su E, Evans D, et al. Guidelines for the appropriate use of bedside general and cardiac ultrasonography in the evaluation of critically ill patients. Part II: Cardiac ultrasonography. *Crit Care Med*. 2016;44:1206–27.
- American College of Emergency Physicians. ACEP emergency ultrasound guidelines-2001. *Ann Emerg Med*. 2001;38:470–81.
- Nguyen J, Amirnovin R, Ramanathan R, Noori S. The state of point-of-care ultrasonography use and training in neonatal-perinatal medicine and pediatric critical care medicine fellowship programs. *J Perinatol*. 2016;36:972–6.
- Conlon TW, Himebauch AS, Fitzgerald JC, Chen AE, Dean AJ, Panebianco N, et al. Implementation of a pediatric critical care focused bedside ultrasound training program in a large academic PICU. *Pediatr Crit Care Med*. 2015;16:219–26.
- Andersen CA, Holden S, Vela J, Rathleff MS, Jensen MB. Point-of-care ultrasound in general practice: a systematic review. *Ann Fam Med*. 2019;17:61–9.
- Calvo Cebrián A, López García-Franco A, Short Apellaniz J. Modelo Point-of-Care Ultrasound en Atención Primaria: ¿herramienta de alta resolución? *Aten Primaria*. 2018;50:500–8.
- Grupo de Ecografía Clínica Pediátrica. Available from: <https://www.aepap.org/grupos/grupo-de-ecografia-clinica-pediatica>.
- Pereda MA, Chavez MA, Hooper-Miele CC, Gilman RH, Steinhoff MC, Ellington LE, et al. Lung ultrasound for the diagnosis of pneumonia in children: a meta-analysis. *Pediatrics*. 2015;135:714–22.
- Marin JR, Zuckerbraun NS, Kahn JM. Use of emergency ultrasound in United States pediatric emergency medicine fellowship programs in 2011. *J Ultrasound Med*. 2012;31:1357–63.
- Vieira RL, Hsu D, Nagler J, Chen L, Gallagher R, Levy JA, et al. Pediatric emergency medicine fellow training in ultrasound: consensus educational guidelines. *Acad Emerg Med*. 2013;20:300–6.
- Marin JR, Abo AM, Arroyo AC, Doniger SJ, Fischer JW, Rempell R, et al. Pediatric emergency medicine point-of-care ultrasound: summary of the evidence. *Crit Ultrasound J*. 2016;8:16.
- Abo AM, Alade KH, Rempell RG, Kessler D, Fischer JW, Lewiss RE, et al. Credentialing pediatric emergency medicine faculty in point-of-care ultrasound: expert guidelines. *Pediatr Emerg Care*. 2019, <http://dx.doi.org/10.1097/PEC.0000000000001677>.
- Su E, Dalesio N, Pustavoitau A. Point-of-care ultrasound in pediatric anesthesiology and critical care medicine. *Can J Anaesth*. 2018;65:485–98.
- Manno E, Navarra M, Faccio L, Motevallian M, Bertolaccini L, Mfochivè A, et al. Deep impact of ultrasound in the intensive care unit: the “ICU-sound” protocol. *Anesthesiology*. 2012;117:801–9.
- Su E, Pustavoitau A, Hirshberg EL, Nishisaki A, Conlon T, Kantor DB, et al. Establishing intensivist-driven ultrasound at the PICU bedside – it’s about time. *Pediatr Crit Care Med*. 2014;15:649–52.
- Volpicelli G, Elbarbary M, Blaivas M, Lichtenstein DA, Mathis G, Kirkpatrick AW, et al. International evidence-based recommendations for point-of-care lung ultrasound. *Intensive Care Med*. 2012;38:577–91.
- Scaife ER, Rollins MD, Barnhart DC, Downey EC, Black RE, Meyers RL, et al. The role of focused abdominal sonography for trauma (FAST) in pediatric trauma evaluation. *J Pediatr Surg*. 2013;48:1377–83.
- Brown GM, Otremba M, Devine LA, Gray C, Millington SJ, Ma IW. Defining competencies for ultrasound-guided bedside procedures: consensus opinions from Canadian physicians. *J Ultrasound Med*. 2016;35:129–41.
- Ecury-Goossen GM, Camfferman FA, Leijser LM, Govaert P, Dudink J. State of the art cranial ultrasound imaging in neonates. *J Vis Exp*. 2015:e52238.
- De Boode WP, Singh Y, Gupta S, Austin T, Bohlin K, Dempsey E, et al. Recommendations for neonatologist performed echocardiography in Europe: consensus statement endorsed by European Society for Paediatric Research (ESPR) and European Society for Neonatology (ESN). *Pediatr Res*. 2016;80:465–71.
- Kurepa D, Zaghoul N, Watkins L, Liu J. Neonatal lung ultrasound exam guidelines. *J Perinatol*. 2018;38:11–22.
- Oh C, Lee S, Seo JM, Lee SK. Ultrasound guided percutaneous internal jugular vein access in neonatal intensive care unit patients. *J Pediatr Surg*. 2016;51:570–2.

36. Accreditation Council for Graduate Medical Education (ACGME). *ACGME Program Requirements for Graduate Medical Education in Critical Care Medicine (Internal Medicine)*. Available from: [https://www.acgme.org/Portals/0/PFAssets/ProgramRequirements/142\\_critical\\_care\\_medicine\\_2017-07-01.pdf](https://www.acgme.org/Portals/0/PFAssets/ProgramRequirements/142_critical_care_medicine_2017-07-01.pdf) [accessed 04.06.19].
37. Conlon TW, Kantor DB, Su ER, Basu S, Boyer DL, Haileselassie B, et al. Diagnostic bedside ultrasound program development in pediatric critical care medicine: results of a national survey. *Pediatr Crit Care Med*. 2018;19:e561–8.
38. Mertens L, Seri I, Marek J, Arlettaz R, Barker P, McNamara P, et al. Targeted neonatal echocardiography in the neonatal intensive care unit: practice guidelines and recommendations for training Writing Group of the American Society of Echocardiography (ASE) in collaboration with the European Association of Echocardiography (EAE) and the Association for European Pediatric Cardiologists (AEPC). *J Am Soc Echocardiogr*. 2011;24:1057–78.
39. Evans N, Kluckow M. Neonatology concerns about the TNE consensus statement. *J Am Soc Echocardiogr*. 2012;25:242.
40. Bahner DP, Goldman E, Way D, Royall NA, Liu YT. The state of ultrasound education in U.S. medical schools: results of a national survey. *Acad Med*. 2014;89:1681–6.