

resulting in a premature stop codon (p.Lys488*, nonsense mutation) and a truncated protein 14 amino acids shorter than the wild protein (Fig. 2A). This mutation was also found in the father and sister of the patient, but not in the healthy mother (Fig. 2B). Fig. 2C shows the family's pedigree. This is a novel variant that is probably pathogenic and with an autosomal dominant pattern of inheritance.

Growth differentiation factor 5 (GDF5) is closely associated with bone morphogenetic proteins and belongs to the transforming growth factor β superfamily, with is involved in embryonic skeletal and joint development.⁴ The *GDF5* gene is a mutational hotspot for disorders associated with skeletal malformations.⁵ Most homozygous or compound heterozygous mutations are associated with severe diseases: Grebe type chondrodysplasia (OMIM 200700), Hunter–Thomson type acromesomelic dysplasia (OMIM 201250) or Du Pan syndrome (OMIM 228900). On the other hand, heterozygous mutations associated to milder skeletal dysplasias: proximal symphalangism 1 B (OMIM 615298) and multiple synostosis syndrome type 2 (OMIM 610017), both associated with missense mutations with gain of function, and brachydactyly type A1 and A2, also associated to missense mutations, but with loss of function.⁵ Brachydactyly type C is associated with heterozygous mutations with loss of function, although 3 cases with recessive inheritance have also been reported.⁶ Most mutations associated with BDC are frameshift mutations in the prodomain part of the gene, while most mutations in the mature domain are missense mutations, with a highly variable phenotypic expression.⁴

The family that we present here has a nonsense mutation in the region that codes for the active domain of the protein, resulting in the elimination of its last 14 amino acids. This is the second nonsense mutation affecting the active mature domain described in the literature.³ The first one is a similar mutation in the amino acid immediately preceding the one mutated in the family that we describe here (p.Tyr487*/c.1461T>G), which suggests that both give rise to mutant monomers and functional haploinsufficiency of *GDF5*, thus causing BDC.

Funding

This study was partially funded by projects PI13/00467 and PI13/01295, integrated in the 2013–2016 R&D&I plan of the Spanish Government and co-funded by the Deputy General-Directorate of Research Evaluation and Promotion of the Instituto de Salud Carlos III (ISCIII), the European Regional Development Fund (ERDF) and the Centro de Investigación

Biomédica en Red sobre Fisiopatología de la Obesidad y la Nutrición (Biomedical Research Networking Centre on the Physiopathology of Obesity and Nutrition [CIBERObn]), ISCIII, Madrid.

References

- Gutiérrez-Amavizca BE, Brambila-Tapia AJ, Juárez-Vázquez CI, Holder-Espinasse M, Manouvrier-Hanu S, Escande F, et al. A novel mutation in *CDMP1* causes brachydactyly type C with angel-shaped phalanx. A genotype–phenotype correlation in the mutational spectrum. *Eur J Med Genet.* 2012;55:611–4.
- Uyguner ZO, Kocaoğlu M, Toksoy G, Basaran S, Kayserili H. Novel indel mutation in the *GDF5* gene is associated with brachydactyly type C in a four-generation Turkish family. *Mol Syndromol.* 2014;5:81–6.
- Yang W, Cao L, Liu W, Jiang L, Sun M, Zhang D, et al. Novel point mutations in *GDF5* associated with two distinct limb malformations in Chinese: Brachydactyly type C and proximal symphalangism. *J Hum Genet.* 2008;53:368–74.
- Hellmann TV, Nickel J, Muller TD. Missense mutations in *GDF-5* signaling: molecular mechanisms behind skeletal malformation. In: Cooper DN, Chen J-M, editors. *Mutations in human genetic disease-InTech.* 2012. p. 11–54.
- Seemann P, Schwappacher R, Kjaer KW, Krakow D, Lehmann K, Dawson K, et al. Activating and deactivating mutations in the receptor interaction site of *GDF5* cause symphalangism or brachydactyly type A2. *J Clin Invest.* 2005;115:2373–81.
- Al-Qattan MM, Al-Motairi MI, Al Balwi MA. Two novel homozygous missense mutations in the *GDF5* gene cause brachydactyly type C. *Am J Med Genet A.* 2015;167:1621–6.

Lourdes Travieso-Suárez^a, Arrate Pereda^b,
Jesús Pozo-Román^{a,c,d}, Guiomar Pérez de Nanclares^b,
Jesús Argente^{a,c,d,*}

^a *Servicios de Pediatría y Endocrinología, Hospital Infantil Universitario Niño Jesús, Instituto de Investigación La Princesa, Madrid, Spain*

^b *Laboratorio de (Epi)Genética Molecular, Instituto de Investigación Sanitaria BioAraba, OSI Araba-Hospital Universitario, Vitoria-Gasteiz, Álava, Spain*

^c *Universidad Autónoma de Madrid, Departamento de Pediatría, Madrid, Spain*

^d *CIBER Fisiopatología de la obesidad y nutrición, Instituto de Salud Carlos III, Madrid, Spain*

* Corresponding author.

E-mail address: jesus.argente@uam.es (J. Argente).
2341-2879/

© 2017 Asociación Española de Pediatría. Published by Elsevier España, S.L.U. All rights reserved.

The vomiting infant: When should intestinal volvulus be suspected?☆



Lactante con vómitos, ¿cuándo sospechar un vólvulo intestinal?

☆ Please cite this article as: Moreno Sanz-Gadea B, Udaondo Gascón C, Sellers Carrera M, Martín Sánchez J, de Ceano-Vivas La Calle M. Lactante con vómitos, ¿cuándo sospechar un vólvulo intestinal? *An Pediatr (Barc).* 2018;88:109–111.

Dear Editor:

Intestinal malrotation is present in 1 out of 500 births and produces symptoms in only 1 out of 5000 cases; the onset of symptoms occurs in the first month of life in 75% of affected patients, and in the first year in 90%.^{1–4} The most important complication of malrotation is intestinal volvulus, in which delays in diagnosis can have severe consequences.

Intestinal malrotation is a predisposing factor for volvulus and bowel obstruction in infancy and childhood. It is due to defects in intestinal rotation that occur during embryonic

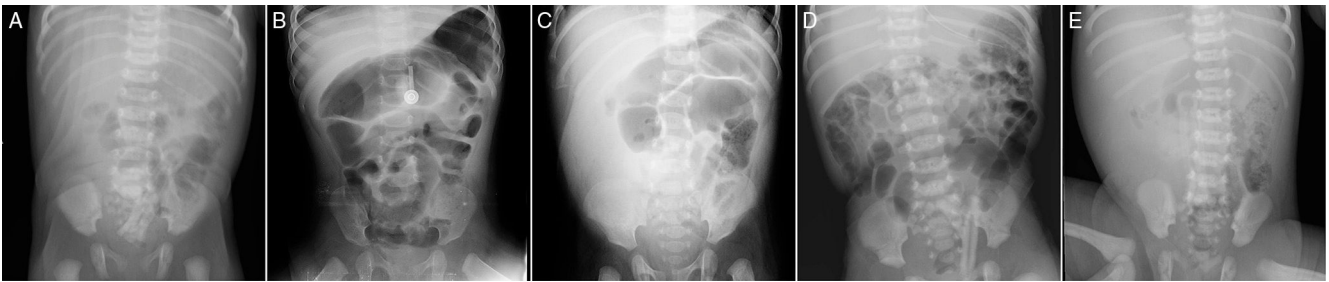


Figure 1 (A) Reduced intraluminal gas in right hemiabdomen. (B) Dilated bowel loops. (C) Reduced intraluminal gas in right hemiabdomen. (D) Dilated bowel loops. (E) Reduced intraluminal gas in right hemiabdomen.

and foetal development. The different types of intestinal malrotation are classified based on the stage of development at which the defect occurs.¹

A malrotated bowel can twist into a volvulus, leading to acute regional vascular compromise and bowel obstruction. Volvulus causes 14% of cases of short bowel syndrome, which can eventually require bowel transplantation, and early diagnosis and treatment could reduce the associated morbidity and mortality.⁵

We present a series of 5 cases of volvulus secondary to intestinal malrotation managed in the course of 1 year in the emergency department of our hospital. The female-to-male ratio was 3:2 and the median age was 5 days (range, 4 days to 5 months). The onset occurred in the first week of life in 3 patients, at age 1.5 months in another, and at age 5 months in the last one, although the latter had previously visited the emergency department on several occasions due to vomiting.

All patients visited the emergency department due to vomiting: bilious in 3, and of gastric contents in the other 2. Two patients presented with irritability and another with abdominal distension. One patient had an altered level of consciousness and decreased appetite.

In 4 patients, the first imaging test performed was a plain radiograph of the abdomen, which evinced reduced intraluminal gas in the right hemiabdomen in all and dilated bowel loops in two (Fig. 1). All patients underwent an abdominal ultrasound examination on account of the radiographic features, which, in combination with the findings of previous tests, suggested the diagnosis of malrotation and/or volvulus in all (Fig. 2).

Every patient was managed with *nil per os*, placement of a nasogastric tube and intravenous fluids. Urgent surgery was performed in all five, with confirmation of the diagnosis of intestinal malrotation and secondary volvulus; one

patient also had a midgut malformation with a single branch of the superior mesenteric artery supplying the volvulised segment, and no surrounding arterial arcades. None of the patients died or required bowel resection. The patient with a midgut malformation required an ileostomy and a total of 4 surgeries to restore intestinal continuity.

The diagnosis of intestinal volvulus requires a high degree of suspicion. It is initially based on the clinical manifestations, which in newborns and infants usually include vomiting (normally bilious, although it can be non-bilious), abdominal distension and irritability.¹⁻³

In cases with clinical manifestations compatible with intestinal volvulus, the first diagnostic test should be an X-ray of the abdomen. Its findings are usually nonspecific, with features such as reduced intraluminal gas or dilated bowel loops, and may be completely normal in some cases, so that radiography is of limited use in the diagnosis of intestinal volvulus. The following step is abdominal ultrasound, which is useful for establishing the position of the mesenteric vessels and for ruling out malrotation, volvulus and other anomalies.¹ Although imaging tests may reveal features suggestive of intestinal malrotation or volvulus, normal findings do not rule out these conditions. Therefore, a high degree of suspicion must be maintained, given that surgery is the only method that can confirm the diagnosis of intestinal volvulus.

Blood tests can guide the diagnosis of intestinal ischaemia in the context of volvulus. The results are nonspecific in the early stages, with presence of leukocytosis. As the disease progresses, and due to third-space fluid losses and bowel oedema, the white blood cell count increases, with an associated increase in haemoglobin and haematocrit values due to haemoconcentration. Cell destruction leads to increases in amylase, lactic dehydrogenase, creatine phosphokinase and transaminase levels. Patients may also

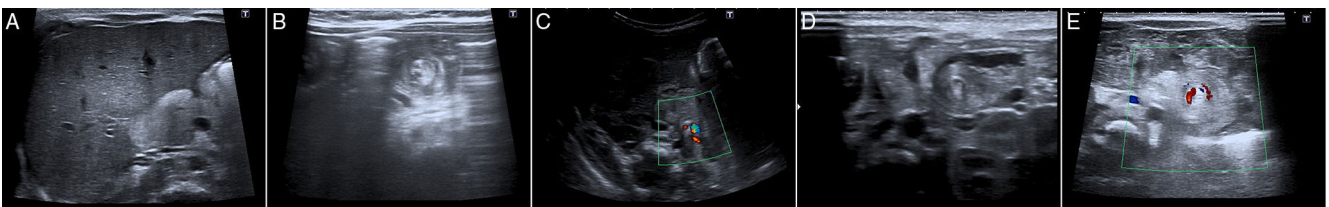


Figure 2 (A) Normal relationship between mesenteric artery and vein. (B) Bowel loops twisted around the axis of the mesenteric vessels. (C) Inversion of mesenteric artery and vein. (D and E) Bowel loops twisted around the axis of the mesenteric vessels.

develop metabolic acidosis with increased lactate levels and electrolyte imbalances such as hyponatraemia and hypokalaemia.

Surgical treatment consists of the Ladd procedure, in which the affected intestine is untwisted and fixed in its correct position. Appendectomy and resection of bowel segments followed by anastomosis or bowel diversion surgery are performed as needed.^{3,4}

Vomiting is a frequent reason for visits to the emergency department. When infants aged less than 1 year present with vomiting, the differential diagnosis should include intestinal volvulus despite its infrequent occurrence, as early diagnosis and treatment are crucial to achieve a favourable outcome.

References

1. Ballesteros Gómiz E, Torremadé Ayats A, Durán Feliubadaló C, Martín Martínez C, Caro Tarragó A. Intestinal malrotation-volvulus: imaging findings. *Radiología*. 2015;57:9–21.
2. Kanellos-Becker I, Bergholz R, Reinshagen K, Boettcher M. Early prediction of complex midgut volvulus in neonates and infants. *Pediatr Surg Int*. 2014;30:579–86.
3. Millar AJW, Rode H, Cywes S. Malrotation and volvulus in infancy and childhood. *Semin Pediatr Surg*. 2003;12:229–36.
4. Shalaby MS, Kuti K, Walker G. Intestinal malrotation and volvulus in infants and children. *BMJ*. 2013;347:f6949.
5. Valdovinos D, Cadena J, Montijo E, Zárata F, Cazares M, Toro E, et al. Short bowel syndrome in children: a diagnosis and management update. *Rev Gastroenterol Mex*. 2012;77:130–40.

Bárbara Moreno Sanz-Gadea^{a,*}, Clara Udaondo Gascón^a, Margarita Sellers Carrera^a, Julia Martín Sánchez^b, María de Ceano-Vivas La Calle^b

^a *Hospital Universitario Infantil La Paz, Madrid, Spain*

^b *Servicio de Urgencias Pediátricas, Hospital Universitario Infantil La Paz, Madrid, Spain*

*Corresponding author.

E-mail address: msgbarbara@gmail.com

(B. Moreno Sanz-Gadea).

2341-2879/

© 2017 Asociación Española de Pediatría. Published by Elsevier España, S.L.U. All rights reserved.