

favourable outcomes with antibiotherapy alone, in contrast with the classic therapeutic approach, which favours the combination of medical treatment and surgical drainage.¹

References

1. Méndez Echevarría A, Baquero Artigao F, Velázquez Fragua R, García Ascaso MT, Merino Muñoz R, del Castillo Martín F. Piomiositis paravertebral resuelta con tratamiento antibiótico exclusivo. *An Pediatr (Barc)*. 2004;60:591–603.
2. Llorente Otones L, Vázquez Román S, Íñigo Martín G, Rojo Conejo P, González Tomé MI. Piomiositis en los niños: no solo una enfermedad tropical. *An Pediatr (Barc)*. 2007;67:578–81.
3. Stevens DL, Bisno AL, Chambers HF, Patchen Dellinger E, Goldstein EJ, Gorbach SL, et al. Practice guidelines for the diagnosis and management of skin and soft tissue infections: 2014 Update by the Infectious Diseases Society of America. *Clin Infect Dis*. 2014;59:e10–52.
4. Crum NF. Bacterial pyomyositis in the United States. *Am J Med*. 2004;117:420.

5. Mitsionis GI, Manoudis GN, Lykissas MG, Sionti I, Motsis E, Georgoulis AD, et al. Pyomyositis in children: early diagnosis and treatment. *J Pediatr Surg*. 2009;44:2173–8.

Beatriz González Gómez^{a,*}, Manuel Vargas Pérez^b, Teresa del Rosal Rabes^a, Francisco Javier Aracil Santos^a, Fernando Baquero-Artigao^a

^a *Servicio de Pediatría Hospitalaria Enfermedades, Infecciosas y Tropicales Pediátricas, Hospital Infantil La Paz, Madrid, Spain*

^b *Servicio de Pediatría, Hospital de Poniente, El Ejido, Almería, Spain*

*Corresponding author.

E-mail address: beatrizglm@gmail.com

(B. González Gómez).

2341-2879/

© 2016 Asociación Española de Pediatría. Published by Elsevier España, S.L.U. All rights reserved.

Drug syrups: Errors in drug labels with possible consequences in patients with hereditary fructose intolerance[☆]



Jarabes de medicamentos: errores en ficha técnica con posibles consecuencias en pacientes con intolerancia hereditaria a la fructosa

Dear Editor:

Hereditary fructose intolerance (HFI, MIM #229600) is an autosomal recessive disease due to Aldolase B deficiency, enzyme responsible for fructose metabolism mainly in the liver. The consumption of fructose, sucrose, sorbitol or tagatose¹ for HFI patients causes severe symptoms which can lead to analytical, neurological, hepatic and renal alterations, hypoglycemia and even death.²

Oral liquid presentations of drugs are classically made with sucrose (simple syrup) but the use of other sweeteners is being increased, such as hydrogenated syrups (polyalcohols) or, in a lesser extent, glucose syrups. The polyalcohols (maltitol, sorbitol, lactitol, etc.) are obtained by sugars' catalytic hydrogenation leading to products with low caloric power. Otherwise, glucose syrups are more caloric, due to their lower sweetening power, although it can be

increased with the transformation of a part of the glucose in fructose (isomerization). The food industry should indicate the amount of fructose in glucose in the definition of the ingredients if it is greater than 5%.³ In the pharmaceutical industry, it is mandatory to put a warning for HFI patients in leaflet and the label if the product contains sweeteners contraindicated in HFI such as fructose, sucrose, inverted sugar, sorbitol, maltitol, isomalt and lactitol⁴ (Table 1). We have detected errors in the denomination of glucose syrups in drug labels potentially harmful for HFI patients.

To establish the scope, we have revised the drug label of medicines with glucose syrup between May 2013 and July 2016 using the "Prescription Nomenclator" tool of the Spanish Medicines Agency (www.aemps.gob.es) and the information has been confirmed with each manufacturer laboratory.

We detected 42 presentations commercialized with glucose syrup. We excluded 4 topical and 27 presentations which were also containing sucrose, sorbitol, maltitol, isomalt or high fructose corn syrup (3 presentations did not have the alert for HFI (11%)). We analyzed 11 presentations: 9 with liquid glucose and 2 with hydrogenated glucose syrup.

In 2 presentations with liquid glucose and in 2 with hydrogenated glucose syrup, the laboratory confirms that they contain fructose and maltitol/sorbitol respectively. The formulation of these 4 presentations is syrup or oral solution; the others are tablets, capsules or vials. In one of them the laboratory indicates that the glucose syrup contains 40% of fructose. In 2 presentations from a same laboratory, we could not obtain the information of the liquid glucose composition and in another 3 (27.7%) the first response was imprecise or contained errors that required a second consultation (Fig. 1). In some cases the delay in the reply has been four months.

In conclusions, we detected very serious errors in the information about excipients in drugs labels that carry a

[☆] Please cite this article as: Izquierdo-García E, Escobar Rodríguez I, Moreno-Villares JM, Iglesias Peinado I. Jarabes de medicamentos: errores en ficha técnica con posibles consecuencias en pacientes con intolerancia hereditaria a la fructosa. *An Pediatr (Barc)*. 2017;87:351–353.

Table 1 Characteristics of excipients/sweeteners and their tolerance in HFI.^{5,6}

Excipient	Composition	Synonyms	Obtaining	Suitable in HFI?
<i>Monosaccharides</i>				
Sorbitol	Sorbitol	D-glucitol, D-sorbitol	Glucose hydrogenation	No
<i>Disaccharides</i>				
Sucrose	Glucose-fructose	Saccharose, sugar, common sugar	From the sugar cane	No
Isomalt	Mix of maltitol and glucose-manitol	Hydrogenated isomaltulose, hydrogenated palatinose	Isomaltulose hydrogenation	No ^a
Lactitol	Galactose-sorbitol	Lactit, lactositol, lactoboost	Lactose hydrogenation	No ^a
Maltitol	Glucose-sorbitol	Hydrogenated maltose	Starch hydrolysate hydrogenation	No ^a
<i>Syrups</i>				
Invert sugar	Mix of glucose and fructose	Invert liquid sugar, invert syrup sugar	Sucrose hydrolysis	No
Glucose syrup	Mix of glucose, maltose and oligosaccharides	Corn sugar	Starch hydrolysis	Yes ^b
Maltitol syrup	Mix of sorbitol, maltitol and hydrogenated polysaccharides	Hydrogenated maltose syrup, hydrogenated glucose syrup with high maltose, hydrogenated starch hydrolysate	Glucose syrup or starch hydrolysate hydrogenation	No ^a
High fructose corn syrup	Glucose and fructose	Isoglucose	Corn starch hydrolysis and isomerization of some glucoses in fructoses (42–55%)	No

^a Absorption is not complete. There is controversy in their tolerance.

^b Check if there have fructose.

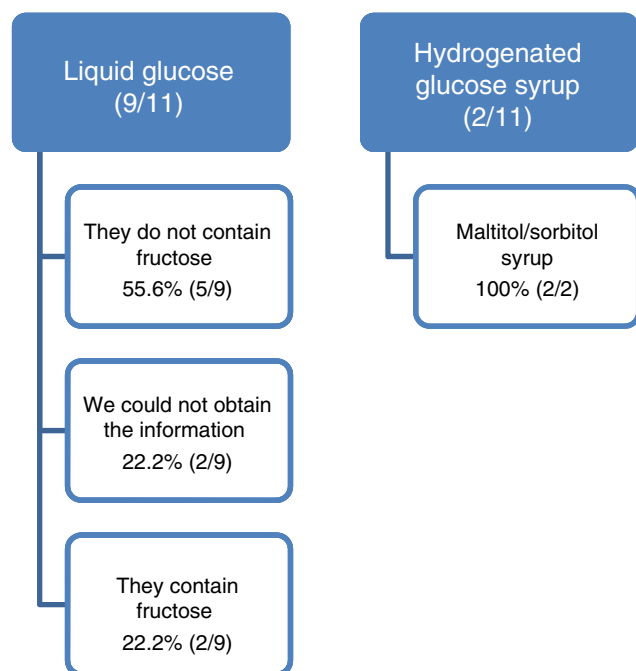


Figure 1 Results obtained with the information provided by the drug marketing laboratory.

serious safety problem for patients with HFI. The two most serious mistakes have been:

- Indicate in drug label "glucose syrup or liquid glucose" when in fact it is "glucose-fructose syrup".
- Indicate in drug label "hydrogenated glucose syrup" as synonymous with "glucose syrup", when in fact it is "maltitol syrup or sorbitol syrup".

In addition, it has been observed that not all medications with fructose, sucrose, sorbitol, maltitol, isomalt or lactitol contain the warning or contraindication mandatory for HFI patients in packaging material, label and leaflet (according to legislation).

The review has been done through an application that filters the drugs according to excipients. However, it cannot be guaranteed that all medications with glucose syrup have been checked. Therefore, these errors have been notified to the Patient Safety Program and Medication Errors of the Madrid Regional Health System and to the Spanish Medicines Agency (errors.etiquetado@aemps.es), so that they make the necessary notifications to the pharmaceutical industry and to the health professionals.

In spite of the size of the sample, both the errors in drug label and the difficulty in obtaining reliable and accurate information for the manufacturer are very striking, being necessary, in several cases, to request further

clarifications, which have led to corrections with respect to the information previously issued. In some cases, if the first manufacturer's information had been considered correct, the consequence of the administration of the drug in an HFI patient could have had serious consequences on his health. We believe there is a necessity of a review process on the contents of the label in a coordinated way between regulatory agencies and the companies that manufacture and/or market these medicines.

References

1. Izquierdo-García E, Moreno-Villares JM, León-Sanz M. Edulcorantes en pacientes con intolerancia hereditaria a la fructosa. *Acta Pediatr Esp.* 2014;72:15–23.
2. Ruiz Pons M. Errores congénitos del metabolismo de la fructosa. In: Sanjurjo P, Baldellou A, editors. *Diagnóstico y tratamiento de las enfermedades metabólicas hereditarias.* 3ª ed. Madrid: Ergon; 2010. p. 411–22.
3. Directiva 2001/111/CE del Consejo, de 20 de diciembre del 2001, relativa a determinados azúcares destinados a la alimentación humana. *Diario Oficial de las Comunidades Europeas*, 12 de enero del 2002.
4. Información sobre los excipientes en el etiquetado, prospecto y ficha técnica de los medicamentos de uso humano. Circular número 2/2008 de la Agencia Española del Medicamento y Productos sanitarios (AEMPS).
5. *Real Farmacopea Española.* 3ª ed. Madrid: Ministerio de Sanidad, Servicios Sociales e Igualdad; 2005.
6. Real Decreto 299/2009 de 6 de marzo. *Boletín Oficial del Estado*, n.º 68, de 20 de marzo del 2009. Normas de identidad y pureza de los edulcorantes utilizados en los productos alimenticios.

Elsa Izquierdo-García^{a,*}, Ismael Escobar Rodríguez^a, José Manuel Moreno-Villares^b, Irene Iglesias Peinado^c

^a *Servicio de Farmacia, Hospital Universitario Infanta Leonor, Madrid, Spain*

^b *Unidad de nutrición clínica, Hospital Universitario 12 de Octubre, Madrid, Spain*

^c *Facultad de Farmacia, Universidad Complutense de Madrid, Madrid, Spain*

* Corresponding author.

E-mail address: elsa.izquierdo@salud.madrid.org

(E. Izquierdo-García).

2341-2879/

© 2016 Asociación Española de Pediatría. Published by Elsevier España, S.L.U. All rights reserved.

Role of nuclear medicine in the differential diagnosis of bone infarction and osteomyelitis in drepanocytosis[☆]



Papel de la medicina nuclear en el diagnóstico diferencial entre infarto óseo y osteomielitis en el contexto de drepanocitosis

Dear Editor:

Sickle cell disease is an autosomal recessive disease in which red blood cells with abnormal haemoglobin S take on a sickle shape, causing obstruction of capillary blood flow and haemolysis.¹ Vaso-occlusive crises with bone involvement (bone infarction) are the most common clinical manifestation, mainly in the humerus, tibia and femur.^{1,2} Tissue devitalization after vaso-occlusive crises, the saturation of macrophages with products derived from chronic haemolysis and splenic dysfunction predispose to bone infection,^{1,2} and *Salmonella* is the most frequent causative agent.¹ Clinical manifestations are similar in both cases (tenderness, warmth, erythema and swelling)² and the

findings of conventional imaging techniques (radiography and ultrasonography) are frequently inconclusive. In the field of nuclear medicine, dual-tracer bone scintigraphy (with diphosphonate and colloid tracers) is available for the purpose of differential diagnosis.

We present the case of a boy aged 12 years with sickle cell disease that visited the emergency department with pain in the proximal region of the left tibia lasting 48 h in the absence of trauma. The patient initially improved with analgesic treatment (morphine hydrochloride) but worsened on the third day, with exacerbation of pain, local oedema and elevation of acute phase reactants and procalcitonin. The patient did not have leukocytosis or fever (although the absence of fever is infrequent, it has been described to reach proportions of up to 22% of cases in some series³).

A radiograph and an ultrasound examination were ordered due to the need to make a differential diagnosis between bone infarction and osteomyelitis. Both showed nonspecific inflammatory soft tissue changes in the anterior region of the left tibia and neither allowed differentiation of the disease. Empirical intravenous antibiotherapy was initiated, and a bone scintigraphy was ordered.

The patient underwent a bone scintigraphy scan, with capture of static images in the blood pool phase (at 5 min) and the metabolic phase (2 h) following intravenous injection of 335 MBq of ^{99m}Tc-HDP. The images revealed increased distribution in the vascular and interstitial compartment and increased osteogenic activity in the left tibial tuberosity, with very faint and diffuse tracer uptake in the two proximal thirds of the ipsilateral tibial diaphysis, and no other abnormalities in the rest of the examined structures. This

[☆] Please cite this article as: Sandoval-Moreno C, Castillejos-Rodríguez L, García-Alonso MP, Rubio-Gribble B, Penín-González FJ. Papel de la medicina nuclear en el diagnóstico diferencial entre infarto óseo y osteomielitis en el contexto de drepanocitosis. *Acta Pediatr (Barc)*. 2017;87:353–355.