



ORIGINAL ARTICLE

Bone marrow transplant in patients with sickle cell anaemia. Experience in one centre[☆]



Marina García Morin^{a,*}, Elena Cela^a, Carmen Garrido^a,
Eduardo Bardón Cancho^a, Alejandra Aguado del Hoyo^b,
Cristina Pascual^c, Ana Pérez-Corral^c, Cristina Beléndez^a

^a Hematología-Oncología Pediátricas, Hospital General Universitario Gregorio Marañón, Madrid, Spain

^b Radiología Infantil, Hospital General Universitario Gregorio Marañón, Madrid, Spain

^c Servicios de Hematología y Hemoterapia, Hospital General Universitario Gregorio Marañón, Madrid, Spain

Received 23 February 2016; accepted 20 March 2016

Available online 5 February 2017

KEYWORDS

Sickle cell disease;
Allogeneic
hematopoietic stem
cell transplantation
from an HLA-identical
sibling

Abstract

Introduction: Sickle cell disease (SCD), despite the improvement in the medical management, is still associated with severe morbidity and decreased survival. Allogeneic hematopoietic stem cell transplantation (Allo-HSCT) currently provides the only curative therapy. A report is presented on our experience in children with SCD, who underwent Allo-HSCT in a single centre.

Material and method: A single centre descriptive study was conducted on patients with SCD who underwent a bone marrow transplant from an HLA-identical sibling donor between January 2010 and December 2014. Epidemiological, clinical and analytical parameters were collected with a follow-up to December 2015. Data are presented as frequencies, percentages, and medians (range).

Results: Allo-HSCT was performed in 11 patients (8 males) with a median age of 7 years (2–13), all of them with comorbidity prior to the HSCT. A stable graft was achieved in 10 out of 11 patients, 9 of them with complete donor chimerism, and one patient with stable mixed chimerism after 1 year of allo-HSCT. One patient has secondary graft failure with re-appearance of symptoms associated with SCD on day 180. Complications of Allo-HSCT are: arterial hypertension 7/11, acute renal failure 3/11, CMV reactivation 9/11, neurological complications 4/11 (subarachnoid haemorrhage, seizure), and acute graft versus host disease (aGVHD) of the skin 6/11, one of whom developed grade IV intestinal aGVHD, causing his death (day 51). None of the patients developed chronic GVHD. The overall survival and event-free survival was 90.9% and 81.9%, respectively, with a median follow-up of 3.1 (1–5.7) years.

[☆] Please cite this article as: García Morin M, Cela E, Garrido C, Bardón Cancho E, Aguado del Hoyo A, Pascual C, et al. Trasplante de médula ósea en pacientes con anemia falciforme. Experiencia en un centro. An Pediatr (Barc). 2017;86:142–150.

* Corresponding author.

E-mail addresses: m.garciamorin@gmail.com, mgmorin@salud.madrid.org (M. García Morin).

PALABRAS CLAVE

Anemia de células falciformes;
Alo-trasplante de médula ósea de hermano HLA idéntico

Conclusions: Allo-HSCT, the only curative therapy, remains associated with morbidity. There was a transplant related mortality in our study, consistent with multicentre studies (1/11), and with aGVHD being the main cause. Other problems still include graft failure (1/11), and neurological complications (4/11), although the permanent sequelae are mild.

© 2016 Asociación Española de Pediatría. Published by Elsevier España, S.L.U. All rights reserved.

Trasplante de médula ósea en pacientes con anemia falciforme. Experiencia en un centro

Resumen

Introducción: La enfermedad de células falciformes (ECF), pese a la mejora en el manejo médico, persiste asociada a morbilidad y a menor supervivencia. El alotrasplante de progenitores hematopoyéticos (alo-TPH) es actualmente la única opción curativa. Describir la evolución clínico-analítica de los pacientes trasplantados en nuestro centro.

Material y método: Estudio unicéntrico descriptivo, incluye a pacientes con ECF en los que se realizó alo-TPH de médula ósea de hermano HLA-idéntico desde enero del 2010 hasta diciembre del 2014. Se recogen datos epidemiológicos, clínicos y analíticos con tiempo de seguimiento hasta diciembre del 2015. Los datos se presentan como frecuencias, porcentajes y medianas (rango).

Resultados: Se recluta a 11 pacientes (8 varones), mediana de edad: 7 años (2–13), todos ellos con comorbilidad previa al TPH. Se consigue injerto estable en 10/11 pacientes, quimerismo completo en 9/11 y quimerismo mixto estable tras un año del TPH en 1/11. Un paciente presenta fallo secundario de injerto con reaparición de clínica el día +180. Complicaciones post-TPH: complicaciones neurológicas 4/11 pacientes (hemorragia subaracnoidea, crisis), HTA 7/11, fallo renal agudo 3/11, reactivación CMV 9/11, EICHa cutáneo 6/11, uno de ellos desarrolla EICH intestinal grado IV causando su fallecimiento (día +51). Ningún paciente desarrolla EICH crónico. Supervivencia global y libre de eventos a los 3,1 años de seguimiento: 90,9 y 81,9%, respectivamente.

Conclusiones: El alo-TPH, única opción curativa, no está exento de morbimortalidad, encontramos un riesgo de muerte similar a otras series (1/11), siendo su primera causa el EICH agudo. Otros problemas son fallo de injerto (1/11) y complicaciones neurológicas (4/11), aunque las secuelas permanentes son leves.

© 2016 Asociación Española de Pediatría. Publicado por Elsevier España, S.L.U. Todos los derechos reservados.

Introduction

Sickle cell disease (SCD) is currently the abnormality detected most frequently in newborn screening tests in several countries, including Spain. In the Autonomous Community of Madrid, where screening has been performed since May 2003, this is corroborated with an incidence of 1 in every 5000 live births.¹ Sickle cell disease is a significant source of multisystemic morbidity and carries an increased risk of early death.² In the past three decades, the introduction of several measures, such as penicillin prophylaxis, vaccination against *Streptococcus pneumoniae*, the use of hydroxyurea, have been implemented leading to a decrease in morbidity and mortality in patients with SCD.^{3–5} There is evidence that hydroxyurea considerably reduces the incidence of vaso-occlusive events and acute chest syndrome^{6,7}; however, this treatment does not reverse organ damage or reduce the risk of stroke. The use of transcranial Doppler ultrasonography (TCD) in the followup of these patients allows the

identification of those that are at high risk of experiencing an acute stroke, while of brain magnetic resonance imaging (MRI) allows the diagnosis of silent strokes.⁸ Transfusion therapy has proven to be useful in the primary prevention of stroke, but it has the disadvantage of secondary iron overload and poor long-term adherence.⁹

At present, haematopoietic stem cell transplantation (HSCT) is the only available curative treatment. The first successful HSCT was performed in 1984 in the United States in a patient with SCD and acute myeloid leukaemia.⁷ Subsequent multicentre studies have reported good outcomes, with an overall survival of 93–94% and an event-free survival of 82–86%, while the most frequent complications are graft failure and graft-versus-host disease (GVHD).^{10–14}

The aim of our study was to describe the clinical and analytical outcomes of patients with SCD that underwent allogeneic HSCT from an HLA-identical sibling donor in our hospital.

Material and methods

We conducted a retrospective descriptive single-centre study. We collected data for paediatric patients with homozygous (HbSS) or double heterozygous (HbSβ⁰) SCD that underwent bone marrow transplantation from an HLA-identical sibling donor (Hb AA or Hb AS phenotype) between January 2010 and December 2014, with followup until December 2015. We studied demographic variables (age, sex) and variables concerning the patients' history of complications associated with the disease: acute chest syndrome (ACT), vaso-occlusive crises (VOCs), dactylitis, priapism, stroke, splenic sequestration and need for splenectomy. As regards treatment prior to HSCT, we documented whether patients received hydroxyurea (HU), transfusion therapy or iron chelation therapy. Other variables under study associated with HSCT were donor-recipient ABO compatibility, stem cell infusion, day of platelet and neutrophil engraftment and chimerism outcomes in bone marrow at day +30 post transplant and in peripheral blood later in time. We collected the following laboratory parameters measured at baseline and at 3, 6, 9 and 12 months post transplantation: haemoglobin, reticulocytes, lactate dehydrogenase (LDH), bilirubin, ferritin, glomerular filtration rate based on cystatin C, lymphocyte differential count (B and T lymphocytes, NK cells), and immunoglobulins (Igs). Last of all, we gathered data for post-transplant complications: acute GVHD, neurologic complications (seizures, subarachnoid haemorrhage [SAH], neurotoxicity), acute renal failure, hypertension (HTN), cytomegalovirus (CMV) reactivation and cause of death.

Conditioning regimen

The conditioning regimen was myeloablative, and consisted of intravenous busulfan (dose by weight of 3.2–4.8 mg/kg/day, administered as a single dose every 24 h on days –9 to –6), intravenous alemtuzumab (0.1 mg/kg/day on days –8 to –6) and intravenous cyclophosphamide (50 mg/kg/day, on days –5 to –2, combined with mesna). Prophylaxis treatment against GVHD was administered from day –1 and consisted of intravenous ciclosporin for three to six months and two doses of methotrexate (at days +4 and +7). Polymerase chain reaction was used to assess for the presence of CMV and EBV and antibody testing to assess for *Aspergillus*, and infection prophylaxis treatment given consisting of micafungin, levofloxacin and acyclovir, as well as cotrimoxazol after engraftment. Additional care measures included intravenous immunoglobulin therapy, ursodiol, phenytoin, antihypertensive drugs to maintain blood pressure at approximately the 95th percentile, supplementation with magnesium as needed and transfusion support with irradiated blood products. The procedure was carried out in individual rooms with positive pressure ventilation systems with HEPA filters.

All patients underwent monthly transfusions or exchange transfusions to achieve a level of Hb S of less than 30% before HSTC, and during transplantation, platelet counts were maintained at more than 50 000 units/ μ L and Hb concentrations at 11–13 g/dL. Infusion of haematopoietic stem

cells was always done from fresh bone marrow. In donor 1, due to the difference in weight with the recipient, bone marrow was extracted in the months preceding transplantation and cryopreserved until infusion (day +1), 24 h after the fresh bone marrow infusion.

Statistical analysis

We used the SPSS[®] software to analyse the data. We have expressed the data as frequencies, percentages, mean and medians (ranges). We compared paired quantitative data by means of Wilcoxon's test, and considered results with *p*-values of less than 0.05 statistically significant.

We studied overall survival and event-free survival by the Kaplan and Meier method. We defined event as death, graft loss (chimerism > 95% of recipient cells) or recurrence of SCD.

Definitions

We defined neutrophil and platelet engraftment as the first of three consecutive days with total counts of more than 500 neutrophils/ μ L or more than 50 000 platelets/ μ L. We defined full donor chimerism as more than 95% of hematopoietic cells of donor origin.

We defined primary graft failure as failure to achieve by day +28 post transplantation a neutrophil count greater than 500 μ L⁻¹, platelet count greater than 50 000 μ L⁻¹ and a haemoglobin concentration greater than 8 g/dL, and secondary graft failure as the lost of at least two cell lineages that had been functional after initial engraftment. We defined graft rejection or autologous reconstitution as recurrence of SCD symptoms.

Results

Patient characteristics (Table 1)

From January 2010 to December 2014, 11 patients (8 male and 3 female) underwent allogeneic HSCT from the bone marrow of an HLA-identical sibling. All of them had a homozygous haemoglobin S phenotype (Hb SS). The median age was 7 years (2–13). Pathological manifestations before HSCT included recurrent VOCs (*n* = 9), recurrent ACS (*n* = 6), stroke (*n* = 2), abnormal flow velocity in TCD (*n* = 4), splenectomy (*n* = 2) and testicular atrophy (*n* = 1). The baseline treatment prior to HSCT consisted of hydroxyurea in four patients, transfusion therapy in one, and hydroxyurea and periodic transfusions in three. Two patients developed iron overload and required iron chelation therapy (Table 1).

All bone marrow donors were HLA-identical siblings; 55% had an Hb AS phenotype. There was minor blood group incompatibility in four patients and major incompatibility in two.

Graft and post-haematopoietic stem cell transplantation complications (Table 2)

A stable graft was achieved in ten out of eleven patients, nine of who developed full donor chimerism (Table 2).

Table 1 Characteristics of patients and donors.

Patient	Sex	Age of BMT	Hydroxyurea TX	BMT indication	Comorbidities	Donor		
						Hb type	Recipient/donor ABO group	Recipient/donor CMV IgG
Pt 1	M	13 y, 10 m	Yes	Abnormal TCD, VOC, ACS		Hb AA	A Rh+/O Rh+	+/+
Pt 2	F	7 y, 10 m	No	Stroke, abnormal TCD	Moya-Moya syndrome	Hb AA	AB Rh+/AB Rh-	+/+
Pt 3	F	10 y, 5 m	Yes	Abnormal TCD, VOC		Hb AA	A Rh+/B Rh+	+/+
Pt 4	M	5 y, 6 m	Yes	VOC, ACS	Testes: atrophy (right), microcalcifications (left)	Hb AA	A Rh+/A Rh+	+/+
Pt 5	M	9 y, 8 m	Yes	Stroke, abnormal TCD, VOC		Hb AS	B Rh+/O Rh+	+/+
Pt 6	F	4 y, 9 m	No	ACS, VOC		Hb AS	B Rh+/B Rh+	+/+
Pt 7	M	9 y, 2 m	Yes	ACS, VOC		Hb AS	O Rh+/O Rh+	+/+
Pt 8	M	2 y, 7 m	No	ACS, VOC		Hb AA	A Rh+/A Rh+	-/+
Pt 9	M	9 y, 10 m	Yes	ACS	Splenectomy. Left ventricular noncompaction	Hb AS	O Rh+/B Rh-	+/-
Pt 10	M	2 y, 1 m	No	VOC		Hb AS	A Rh+/O Rh+	+/+
Pt 11	M	6 y, 1 m	Yes	VOC	Splenectomy	Hb AS	O Rh+/O Rh+	-/+

ACS, acute chest syndrome; BMT, bone marrow transplant; y, years; m, months; F, female; M, male; TCD, transcranial Doppler; TX, treatment; VOC, vaso-occlusive crisis.

The median neutrophil engraftment was 22 days (16–27) and the median platelet engraftment was 28 (19–94).

Patient 9 (Table 2) had full donor chimerism in the overall bone marrow at day +30 (1.3% cells of recipient origin), but chimerism analysis of cell subpopulations showed that 51% of T lymphocytes were of recipient origin. Immunosuppression was discontinued and the patient was given three infusions of donor T lymphocytes at days +71 ($1 \times 10^5 \text{ kg}^{-1}$), +105 ($1.95 \times 10^5 \text{ kg}^{-1}$) and +170 ($0.85 \times 10^6 \text{ kg}^{-1}$) with no improvement in chimerism, and the symptoms of SCD recurred on day +180 (admission for VOC). Patient 11 (Table 2) had full donor chimerism in the overall bone marrow at day +30 (2.5% cells of recipient origin) but partial chimerism in the T lymphocyte population (59% of recipient origin). Immunosuppression was intensified, adding mycophenolate to ciclosporin and maintaining the treatment for one year. The mixed chimerism values remained stable: 4.2% at three months, 6% at six months, 6% at one year, with a gradual decrease of recipient T lymphocytes (12% at one year).

The most frequent complication after HSCT was reactivation of CMV, which occurred in nine out of eleven patients and was treated with foscarnet when it developed prior to engraftment and valganciclovir if the graft was stable. Hypertension developed in seven out of eleven children in association with stem cell infusion (patients 1 and 7), secondary to administration of drugs such as corticosteroids for the treatment of acute GVHD (patient 3), foscarnet for reactivation of CMV (patient 5) or ciclosporin (patient 9),

or due to multiple factors in the context of impaired renal function (patient 10). All patients achieved adequate control of blood pressure, save for patient 10, who still needs oral hypertensive treatment one year later, although blood pressure has normalised and treatment is being tapered off. Fig. 1 shows the evolution of glomerular filtration assessed by measurement of cystatin C in patients that developed acute kidney failure.

When it came to neurologic complications, three patients developed SAH in the context of hypertension, two of who had associated epileptic seizures (Table 2 and Fig. 2). Patient 1 had a second episode of seizures on day +27, and computed tomography (CT) did not detect new sites of

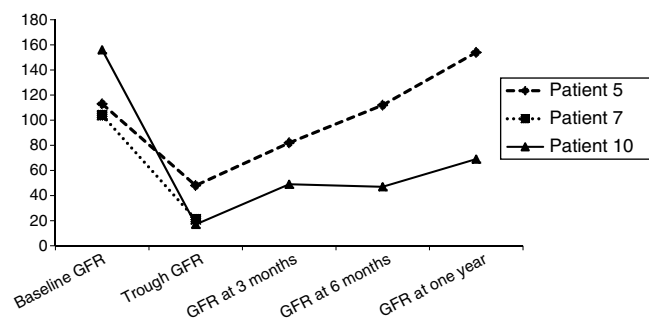


Figure 1 Evolution of glomerular filtration rate (GFR) in patients that developed acute kidney failure during HSCT.

Table 2 Haematopoietic stem cell transplantation (HSCT), outcomes and complications post transplantation.

Pt	Cell dose: CD34+ ($\times 10^6$ kg ⁻¹)	Day NEU engraftment	Day Plat engraftment	Chimerism (% recipient origin)		CMV (day and treatment)	
				Day +30 (BM)	Last chimerism (time post HSCT)		
Pt 1	Day 0 (fresh BM): 3.8 Day +1 (cryopreserved BM): 6.1	+16	+31	1.9%	4.4% (5 y 7 m)	Yes, +9, foscarnet	
Pt 2	6	+23	+27	0%	4.8% (4 y 8 m)	Yes, +13, foscarnet	
Pt 3	3.4	+23	+27	0%	3.6% (4 y 7 m)	Yes, +11, foscarnet	
Pt 4	8.5	+27	+27	0%	3.6% (4 y 1 m)	No	
Pt 5	5.48	+16	+38	0%	0% (3 y 1 m)	Yes, +13, foscarnet	
Pt 6	4.63	+18	+42	0%	0% (3 y 9 m)	Yes, +7, foscarnet	
Pt 7	3.72	+20	+19	0%		Yes, +39, ganciclovir	
Pt 8	6.52	+25	+39	0%	0% (1 y 9 m)	Yes, +47, ganciclovir	
Pt 9	2.85	+18	+28	1.3%	92%	Yes, +8, foscarnet	
Pt 10	5.3	+24	+94	51% T cells 2.4%	88% T cells (1 y 7 m) 0% (1 and 2 m)	Yes, +9, foscarnet	
Pt 11	3.5	+22	+24	2.5% 59% T cells	6% 12% T cells (1 y 0 m)	No	
Pt	Acute neurologic complications (day of onset)		HTN (day of onset)	AKF	aGVHD- localization and grade	Other complications post-HSCT	Event (death/graft loss/SCD clinical recurrence/alive)
	Seizures	SAH					
Pt 1	Yes, +1 +27	Yes, +1	Yes (+1)	No	Yes Cutaneous II	Day +27: brain MRI: cyclosporin toxicity Mild cognitive impairment Mucositis grade 3	Alive
Pt 2	No	No	Yes (day 0)	No	No		Alive
Pt 3	Yes, +29	No	Yes (+17)	No	Yes Cutaneous I		Alive
Pt 4	No	No	No	No	No	Mucositis grade 4	Alive
Pt 5	No	No	Yes (+13)	Yes	Yes Cutaneous II	Possible <i>Aspergillus</i> infection	Alive
Pt 6	No	No	No	No	No	Catheter-related infection and left gluteus myositis due to MRSA	Alive
Pt 7	Yes, +1	Yes, +1	Yes (+1)	Yes	Yes Cutaneous IV Gastrointestinal IV Hepatic III	BK virus-associated haemorrhagic cystitis Cholestasis and development of biliary sludge and cholelithiasis Fever without microbial isolation	Died on day +51 (aGVHD grade IV and multiple organ failure)
Pt 8	No	No	No	No	Yes Cutaneous I	Mucositis grade 4	Alive
Pt 9	No	Yes, +2	Yes (day -1)	No	No	Mucositis grade 1 BK virus-associated haemorrhagic cystitis	Clinical recurrence (VOC) on day +180
Pt 10	No	No	Yes (+23)	Yes	Yes Cutaneous III	Mucositis grade 3 Fever and neutropaenia	Alive
Pt 11	No	No	No	No	No	Mixed chimerism: intensified immunosuppression for 1 year	Alive

BM, bone marrow; CMV, cytomegalovirus; aGVHD, acute graft-versus-host disease; AKF, acute kidney failure; BM, bone marrow; HTN, hypertension; NEU, neutrophil; y, years; m, months; PB, peripheral blood; Plat, platelet; SCD, sickle cell disease; SAH, subarachnoid haemorrhage; VOC, vaso-occlusive crisis.

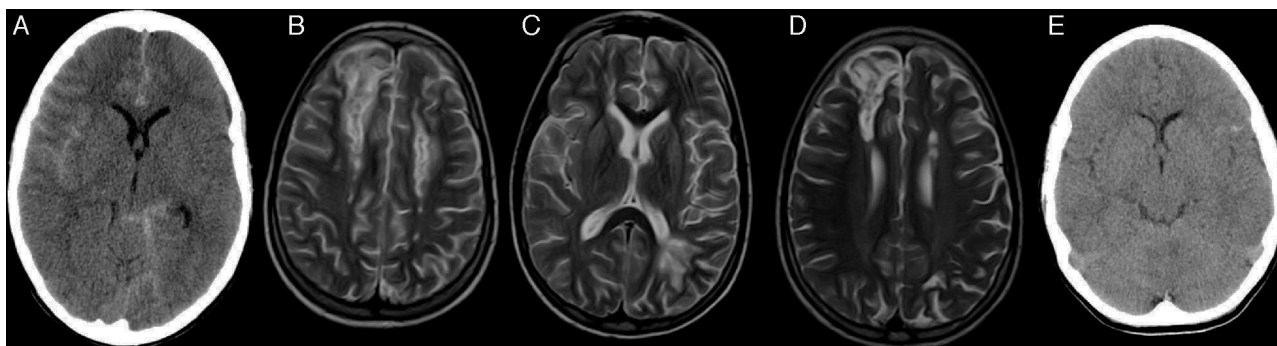


Figure 2 Patient 1 (A–D). Simple axial CT scan with sulcus hyperdensity suggestive of subarachnoid haemorrhage in the right lateral sulcus, superolateral sulci with right-side predominance, and the left peripeduncular cistern (A). T2 TSE axial MRI at day +27 with evidence of bilateral frontal cortical and subcortical lesions and bilateral frontal and left parietal deep white matter lesions compatible with ciclosporin toxicity (B and C). T2 TSE axial MRI at six months post HSCT with evidence of residual lesions (D). Patient 9 (E): axial head CT scan with hyperdensity in left frontotemporal sulci as evidence of subarachnoid haemorrhage on day +2.

bleeding, although it showed bilateral parieto-occipital and frontal hypodense lesions. The investigation was expanded with brain MRI, which ruled out vascular malformations and found lesions in both cerebral hemispheres compatible with ciclosporin toxicity and development of oedema post transplantation. The patient had a favourable neurologic outcome (cognitive and motor) after discontinuation of ciclosporin, although a mild cognitive impairment remained. A follow-up MRI scan at six months revealed the persistence of the previously observed lesions, with no new lesions (Fig. 2). The neurologic evaluation of patients that had SAH at one year post transplantation was normal, and while patient 1 experienced academic difficulties (mild cognitive impairment), he did not require grade retention and has college-level studies.

Six patients developed acute GVHD, five with isolated skin involvement that responded well to corticosteroid treatment. Patient 7 had acute GVHD refractory to corticosteroids with grade IV skin and intestinal involvement and grade III liver involvement that did not respond to intensification of immunosuppression (mycophenolate, infliximab) or photopheresis, leading to his death on day +51. None of the patients developed chronic GVHD or hepatic sinusoidal obstruction syndrome.

At the time of this writing, 10 out of the 11 patients are alive after a mean duration of followup of 3.1 years (range, 1–5.7). The Kaplan–Meier curve shows an overall survival of 90.9% and an event-free survival of 81.8% (Fig. 3).

Fig. 4 presents the evolution of haemolysis parameters (haemoglobin, reticulocytes, LDH and bilirubin), with significant differences ($P < .05$) between the median patient levels at baseline and at one year after HSCT. Fig. 5 presents graphs of the evolution of immune reconstitution (T and B lymphocytes, NK cells, T CD4/CD8 ratio) with the median counts at baseline and at three months, six months and one year post transplantation.

Discussion

Despite the small sample size ($n=11$), the results of our study were consistent with those of multicentre studies^{8,9,15} conducted in countries with more experience in the

treatment of children with SCD. Performance of HSCT in these patients requires not only knowledge of transplantation technique, but also a thorough understanding of the overall treatment of haemoglobinopathies. In Spain, access to cohorts of children with SCD is a relatively new phenomenon, so this is the largest series studied to date.

One patient died of acute GVHD, which is also one of the main causes of death in other series (Table 3). The incidence of acute GVHD (grade > II) was 36%, higher than the incidence reported in other series despite similar prophylaxis regimens with ciclosporin and methotrexate, although this result may have been different with a larger sample size. A possible cause is that the source of the stem cells was bone marrow in all cases, whereas in other studies the source is umbilical cord blood, which carries a lower risk of acute GVHD, in up to 14% of cases.^{14,16,17} At any rate, none of the patients in our series developed chronic GVHD.

Cerebrovascular problems are a significant cause of neurologic morbidity associated with transplantation in patients with SCD. Walter et al.¹⁸ reported an incidence of

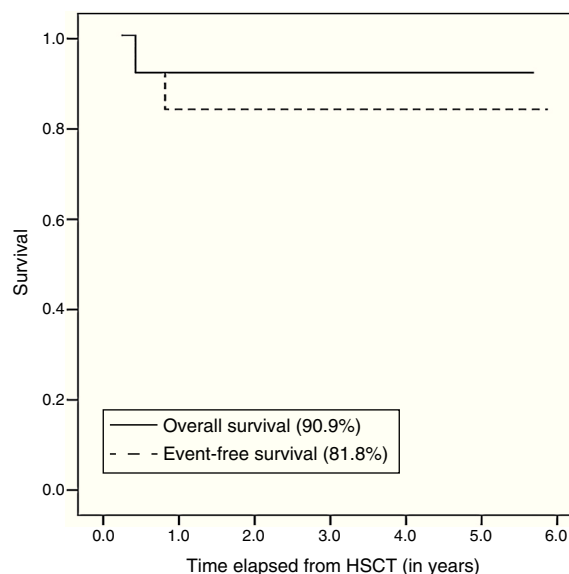


Figure 3 Kaplan–Meier curve.

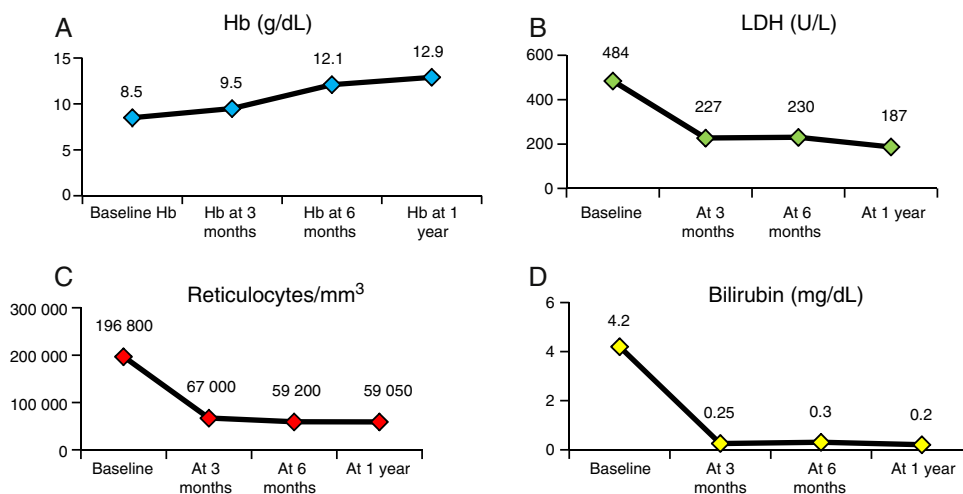


Figure 4 Evolution of haemolysis parameters: haemoglobin (Hb) (A), lactase dehydrogenase (LDH) (B), reticulocytes (C), bilirubin (D): median values at baseline and at 3 months, 6 months and 1 year post HSCT.

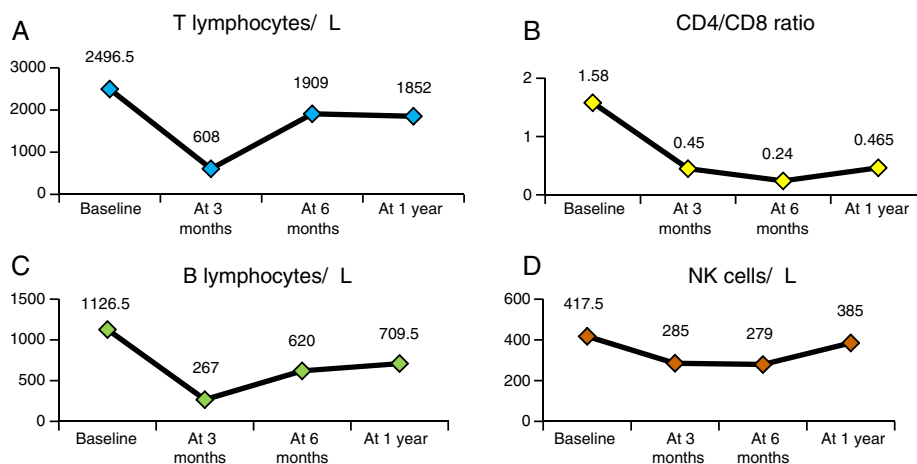


Figure 5 Immune reconstitution. Evolution of T lymphocyte count (A), CD4/CD8 ratio (B), B lymphocyte count (C) and NK cells (D): median values at baseline and at 3 months, 6 months and 1 year post HSCT.

Table 3 International experience. Comparison of the current study with previously published series.

	Current study	Vermlyen 1998	Walters 2000	Bernaudin 2007	Panepinto 2007
N	11	50	50	87	67
Overall survival	90.9%	93%	94%	93.1%	98%
Event-free survival	81.8%	82%	84%	86.1%	85%
Graft failure	9%	10%	10%	7%	13%
aGVHD (\geq grade II)	36%	20%	15%	20%	10%
cGVHD	0%	20%	12%	13.5	22%
No. deaths/cause	1/GVHD	2: GVHD + CMV + <i>Aspergillus</i> Sudden death	3/GVHD	6: 4: GVHD CNS haemorrhage Sepsis	3: GVHD + CNS haemorrhage Multiple organ failure Unknown cause

aGVHD, acute graft-versus-host disease; cGVHD, chronic graft-versus-host disease.

neurologic complications post HSCT of 50% in patients with a prior history of cerebral infarction and of 23% in the rest of the patients; however, a French series¹³ did not find a significant increase in risk in patients with a past history of cerebrovascular disease. In our series, the two patients with evidence of stroke in the MRI scan performed before HSCT did not develop acute neurologic complications. Hypertension developed in seven out of the eleven patients and caused significant morbidity, as despite the measures taken for its management, it was probably related to SAH in three patients. The incidence of seizures in the French and North American series was 24% and 28%, respectively, and seizures are the most frequent complication post HSCT¹; they usually develop in the first few days after transplantation in association with hypertension and with corticosteroid therapy.^{13,18} In our study, and despite prophylaxis with phenytoin, three of the eleven patients developed seizures, all of them in association with hypertension. Patient 1 had a new episode of seizures on day +27, this time due to ciclosporin toxicity, and leading to mild cognitive impairment. In our series, patients did not die from neurologic complications nor develop severe neurologic sequelae.

Graft failure and autologous reconstitution also continue to be among the major problems that follow HSCT in patients with SCD, with an incidence that ranges between 7% and 13% (Table 3) and of 9% in our study. Among its causes are previous alloimmunisation due to multiple transfusions, bone marrow hyper-regeneration, blood group incompatibility, cell dose (CD34+) and viral infection. The French series demonstrated that intensification of immunosuppression with addition of rabbit anti-thymocyte globulin to the conditioning regimen reduces the probability of graft rejection from 22.6% to 3%.¹³ All our patients received alemtuzumab to induce lymphocyte depletion. Patient 9 experienced autologous reconstitution with recurrence of SCD symptoms on day +180, with the main risk factors for it being a cell dose near the lower limit, major blood group incompatibility and reactivation of CMV (Tables 1 and 2). Discontinuation of immunosuppression and infusion of donor T lymphocytes did not succeed in improving chimerism in our patient, who had full donor chimerism in the overall bone marrow at day +30, but with 51% of T lymphocytes already of recipient origin. Similarly, patient 11 had mixed chimerism in the T lymphocyte population at day +30, which led to a change in management, intensifying immunosuppression with the addition of mycophenolate to ciclosporin; this had achieved a stable chimerism at one year of followup in the absence of clinical manifestations of SCD (Table 2). Mixed chimerism can be an acceptable option in nonmalignant blood disorders, and although the main risk it carries is autologous reconstitution in the first year, if it remains stable it can prevent the development of clinical manifestations of the disease¹⁹ and improve haemolysis parameters.²⁰

The findings of multicentre studies have led to the development of new management strategies with the purpose of reducing transplant-related mortality, graft failure and treatment toxicity. Thus, a study conducted in Belgium found a significant improvement in event-free survival (no cases of graft failure or autologous reconstitution) in the group treated with hydroxyurea in the months preceding HSCT, compared to the group treated with the standard conditioning regimen with busulfan, cyclophosphamide and

anti-thymocyte globulin and no hydroxyurea (97.4% vs. 66.7%; $P = .006$).²¹

Recently, based on the results of studies in adults treated with reduced-toxicity conditioning regimens and one study in children with thalassaemia major,²² a study in 15 children with SCD used a conditioning regimen consisting of treosulfan, thiotepa and fludarabine. Treosulfan has a structure analogous to that of busulfan and exhibits a potent myeloablative activity combined with minimal extramedullary toxicity and a more linear pharmacokinetic profile. This study obtained excellent results, with an overall survival of 100%, an event-free survival of 93% and a decreased treatment-related toxicity for HSCT, encouraging a change in the conditioning of these patients.²³

In our study, HSCT was indicated in all patients based on the clinical practice guidelines of SCD of the SEHOP¹; however, patients that receive the transplant in the early stages of the disease have the best outcomes, as was observed in the Belgian series, in which overall survival and event-free survival of asymptomatic patients were higher than those of patients with severe forms of disease (100% vs. 88% and 93% vs. 76%, respectively).¹² This is why there is an ongoing debate on whether HSCT from an HLA-identical sibling donor should be performed in asymptomatic patients or its indications should be expanded.²⁴

Conclusion

Haematopoietic stem cell transplantation is the only curative treatment available to patients with SCD, and our results are consistent with those of the international literature (overall survival, 90.9%, event-free survival, 81.82%). However, it still carries a risk of death (9%), with the most frequent reason being GVHD, and of significant comorbidities, such as graft failure (9%) and neurologic complications (36%). In light of these results and the reviewed literature, we decided to make changes to the conditioning regimen (treosulfan, fludarabine, thiotepa), the suppression of erythropoiesis in the two months prior to HSCT and pre-transplantation ambulatory blood pressure monitoring, and are contemplating a change in GVHD prophylaxis. T lymphocyte chimerism analysis helps the early detection of mixed chimerism and, in our experience, leads to better outcomes through the subsequent intensification of immunosuppression to prevent graft failure.

Conflict of interests

The authors have no conflict of interests to declare.

References

1. Cela E, Cervera A, Díaz de Heredia, Rives S, Salinas A, Sevilla J, et al. Guía de práctica clínica sobre enfermedad de células falciformes pediátrica. Sociedad Española de Hematología y Oncología Pediátrica (SEHOP); 2010. January. Available from: www.SEHOP.org, ISBN 978-84-694-4619-5.
2. Platt OS, Brambilla DJ, Rosse WF, Milner PF, Castro O, Steinberg MH, et al. Mortality in sickle cell disease. Life expectancy and risk factors for early death. *N Engl J Med.* 1994;330:1639–44.

3. Quinn CT, Rogers ZR, Buchanan GR. Survival of children with sickle cell disease. *Blood*. 2004;103:4023-7.
4. Quinn CT, Rogers ZR, McCavit TL, Buchanan GR. Improved survival of children and adolescents with sickle cell disease. *Blood*. 2010;115:3447-52, <http://dx.doi.org/10.1182/blood-2009-07-233700> [Epub 2010 March 1].
5. Gaston MH, Verter JI, Woods G, Pegelow C, Kelleher J, Presbury G, et al. Prophylaxis with oral penicillin in children with sickle cell anemia. A randomized trial. *N Engl J Med*. 1986;314:1593-9.
6. Scott JP, Hillery CA, Brown ER, Misiewicz V, Labotka RJ. Hydroxyurea therapy in children severely affected with sickle cell disease. *J Pediatr*. 1996;128:820-8.
7. De Montalembert M, Belloy M, Bernaudin F, Gauraud F, Capdeville R, Mardini R, et al. Three-year follow-up of hydroxyurea treatment in severely ill children with sickle cell disease. The French Study Group on Sickle Cell Disease. *J Pediatr Hematol Oncol*. 1997;19:313-8.
8. Adams RJ, McKie VC, Hsu L, Files B, Vichinsky E, Pegelow C, et al. Prevention of a first stroke by transfusions in children with sickle cell anemia and abnormal results on transcranial Doppler ultrasonography. *N Engl J Med*. 1998;339:5-11.
9. Brousse V, Kossorotoff M, de Montalembert M. How I manage cerebral vasculopathy in children with sickle cell disease. *Br J Haematol*. 2015;170:615-25, <http://dx.doi.org/10.1111/bjh.13477> [Epub 2015 May 5].
10. Walters MC, Patience M, Leisenring W, Eckman JR, Scott JP, Mentzer WC, et al. Bone marrow transplantation for sickle cell disease. *N Engl J Med*. 1996;335:369-76.
11. Walters MC, Storb R, Patience M, Leisenring W, Taylor T, Sanders JE, et al. Impact of bone marrow transplantation for symptomatic sickle cell disease: an interim report. Multicenter investigation of bone marrow transplantation for sickle cell disease. *Blood*. 2000;95:1918-24.
12. Vermynen C, Cornu G, Ferster A, Brichard B, Ninane J, Ferrant A, et al. Haematopoietic stem cell transplantation for sickle cell anaemia: the first 50 patients transplanted in Belgium. *Bone Marrow Transplant*. 1998;22:1-6.
13. Bernaudin F, Socie G, Kuentz M, Chevret S, Duval M, Bertrand Y, et al. Long-term results of related myeloablative stem-cell transplantation to cure sickle cell disease. *Blood*. 2007;110:2749-56 [Epub 2 July 2007].
14. Panepinto JA, Walters MC, Carreras J, Marsh J, Bredeson CN, Gale RP, et al. Matched-related donor transplantation for sickle cell disease: report from the Center for International Blood and Transplant Research. *Br J Haematol*. 2007;137:479-85.
15. Johnson FL, Look AT, Gockerman J, Ruggiero MR, Dalla-Pozza L, Billings FT 3rd. Bone-marrow transplantation in a patient with sickle-cell anemia. *N Engl J Med*. 1984;311:780-3.
16. Locatelli F, Kabbara N, Ruggeri A, Ghavamzadeh A, Roberts I, Li CK, et al., Eurocord and European Blood and Marrow Transplantation (EBMT) group. Outcome of patients with hemoglobinopathies given either cord blood or bone marrow transplantation from an HLA-identical sibling. *Blood*. 2013;122:1072-8.
17. Locatelli F, Pagliara D. Allogeneic hematopoietic stem cell transplantation in children with sickle cell disease. *Pediatr Blood Cancer*. 2012;59:372-6.
18. Walters MC, Sullivan KM, Bernaudin F, Souillet G, Vannier JP, Johnson FL, et al. Neurologic complications after allogeneic marrow transplantation for sickle cell anemia. *Blood*. 1995;85:879-84.
19. Walters MC, Patience M, Leisenring W, Rogers ZR, Aquino VM, Buchanan GR, et al. Multicenter investigation of bone marrow transplantation for sickle cell disease. Stable mixed hematopoietic chimerism after bone marrow transplantation for sickle cell anemia. *Biol Blood Marrow Transplant*. 2001;7:665-73.
20. Wu CJ, Gladwin M, Tisdale J, Hsieh M, Law T, Biernacki M, et al. Mixed haematopoietic chimerism for sickle cell disease prevents intravascular haemolysis. *Br J Haematol*. 2007;139:504-7.
21. Dedeken L, Lê PQ, Azzi N, Brachet C, Heijmans C, Huybrechts S, et al. Haematopoietic stem cell transplantation for severe sickle cell disease in childhood: a single centre experience of 50 patients. *Br J Haematol*. 2014;165:402-8.
22. Bernardo ME, Piras E, Vacca A, Giorgiani G, Zecca M, Bertaina A, et al. Allogeneic hematopoietic stem cell transplantation in thalassemia major: results of a reduced-toxicity conditioning regimen based on the use of treosulfan. *Blood*. 2012;120:473-6.
23. Strocchio L, Zecca M, Comoli P, Mina T, Giorgiani G, Giraldi E, et al. Treosulfan-based conditioning regimen for allogeneic haematopoietic stem cell transplantation in children with sickle cell disease. *Br J Haematol*. 2015;169:726-36.
24. Bolaños-Meade J, Brodsky RA. Blood and marrow transplantation for sickle cell disease: is less more? *Blood Rev*. 2014;28:243-8.