

in clinical remission with stable laboratory results (PCDAI 0; FC, 20 mg/kg) under low-dose corticosteroid treatment (0.1 mg/kg/day) with concurrent administration of mercaptopurine.

There are few descriptions of the association of CD and PIT in the literature (Table 2). The onset of PIT in association with IBD is variable, although based on the published cases it seems to occur more frequently after the diagnosis of IBD. Since the cases described in the literature involved UC more frequently than CD, we think it is worth noting that our patients with CD had exclusive colonic involvement, which supports the hypothesis that the inflammation of the colonic mucosa and/or the dysregulation of the local immune system may be associated with the development of PIT in these patients.<sup>3,5</sup>

Studies in adults have described cases of PIT refractory to conventional treatment that responded well to treatment with anti-TNF factor, and it has been hypothesised that the pathogenic mechanism involves the apoptosis of monocytes and macrophages (which produce TNF alpha, as do CD4 lymphocytes), with a decline in the anti-platelet antibodies produced by B lymphocytes.<sup>6</sup>

We believe that in the cases reviewed here, while conventional therapy was used when PIT first developed (gammaglobulin and corticosteroids), the adequate control of CD with anti-TNF factor agents in case 1 and thiopurines in case two allowed for the improved management and outcomes of PIT, without requiring further gammaglobulin doses. The additional option of discontinuing corticosteroid treatment in our patient treated with anti-TNF factor makes the possibility of escalating treatment in patient 2 attractive if his CD does not respond favourably.

To conclude, it could be said that the association between PIT and CD is rare. The treatment used for maintaining CD in remission can also achieve adequate control of PIT. Thus, aggressive treatments can be avoided, improving quality of life in these patients.

## References

- Dotson L, Hyams S, Markowitz J, LeLeiko S, Mack R, Evans S, et al. Extraintestinal manifestations of pediatric inflammatory bowel disease and their relation to disease type and severity. *J Pediatr Gastroenterol Nutr.* 2010;51:140–5.
- Jose F, Garnett E, Vittinghoff E, Ferry G, Winter S, Baldassano R, et al. Development of extraintestinal manifestations in pediatric patients with inflammatory bowel disease. *Inflamm Bowel Dis.* 2009;15:63–87.
- Higuchi L, Joffe S, Neufeld E, Weisdorf S, Rosh J, Murch S, et al. Inflammatory bowel disease associated with immune thrombocytopenic purpura in children. *J Pediatr Gastroenterol Nutr.* 2001;33:582–7.
- Monteagudo E, Fernández R, Sastrec A, Tolld T, Llorde A, Molina J, et al. Protocolo de estudio y tratamiento de la trombocitopenia inmune primaria. *An Pediatr (Barc).* 2011;74:414.e1–8.
- Manceñido M, Erdozain J, Pajares R, Paño J, González P, Navajas F, et al. Idiopathic thrombocytopenic purpura as an extraintestinal manifestation of Crohn's disease. *Gastroenterol Hepatol.* 2004;27:368–71.
- De Rossi T, Krauss N, Voll R, Nägel A, Weidenhiller M, Konturek P, et al. Long-term partial remission of autoimmune thrombocytopenia in a patient treated with the anti-tumor necrosis factor-alpha antibody infliximab for refractory fistulizing Crohn's disease. *Digestion.* 2008;78:195–200.

N. Crespo Madrid, C. Ruiz Hernández, L. Giraldo Escobar, G. Pujol Muncunill, J. Martín de Carpi\*

*Sección de Gastroenterología, Hepatología y Nutrición Pediátrica, Unidad para el Cuidado Integral de la Enfermedad Inflamatoria Intestinal Pediátrica, Hospital Sant Joan de Déu, Esplugues de Llobregat, Barcelona, Spain*

\* Corresponding author.

*E-mail address:* [Javiermartin@hsjdbcn.org](mailto:Javiermartin@hsjdbcn.org) (J. Martín de Carpi).

## Hepatic hemangiomas: Spectacular response to treatment with propranolol<sup>☆</sup>

### Hemangiomas hepáticos: respuesta espectacular al tratamiento con propranolol

*Dear Editor,*

Infantile haemangiomas (IH) are the most common benign soft tissue tumour of infancy. They affect 1–2.6% of newborns and up to 10% by 1 year of age.<sup>1</sup> They typically present as solitary skin lesions. In some cases, IH may be multiple and involve extracutaneous organs, most commonly the liver.<sup>1,2</sup>

Hepatic haemangioma (HH) is the most frequent benign liver tumour in infancy,<sup>3</sup> with a preponderance of female infants.<sup>4</sup> They have been classified into three categories: focal, multifocal and diffuse.<sup>5</sup> Focal HHs usually consist of solitary and asymptomatic lesions and generally do not require intervention.<sup>1</sup> They seem to be equivalent to the skin lesions of rapidly involuting congenital haemangioma (RICH), and as happens in the latter condition, patients do not express the GLUT-1 glucose transporter that is usually found in IHs.<sup>1,5</sup> Multifocal and diffuse HHs are true HHs. Multifocal HH presents as multiple spherical lesions that may remain asymptomatic until their spontaneous resolution, and less frequently they may lead to heart failure secondary to arteriovenous or portovenous shunting. In diffuse HHs, there is near-total replacement of liver parenchyma, which may trigger abdominal compartment syndrome due to mass effect. It may also be associated to hypothyroidism due to high production of type III thyronine deiodinase.<sup>5</sup>

Traditionally, corticosteroids have been used as the first-line treatment of symptomatic HHs, alone or in combination with vincristine (VCR), which started to be used as an

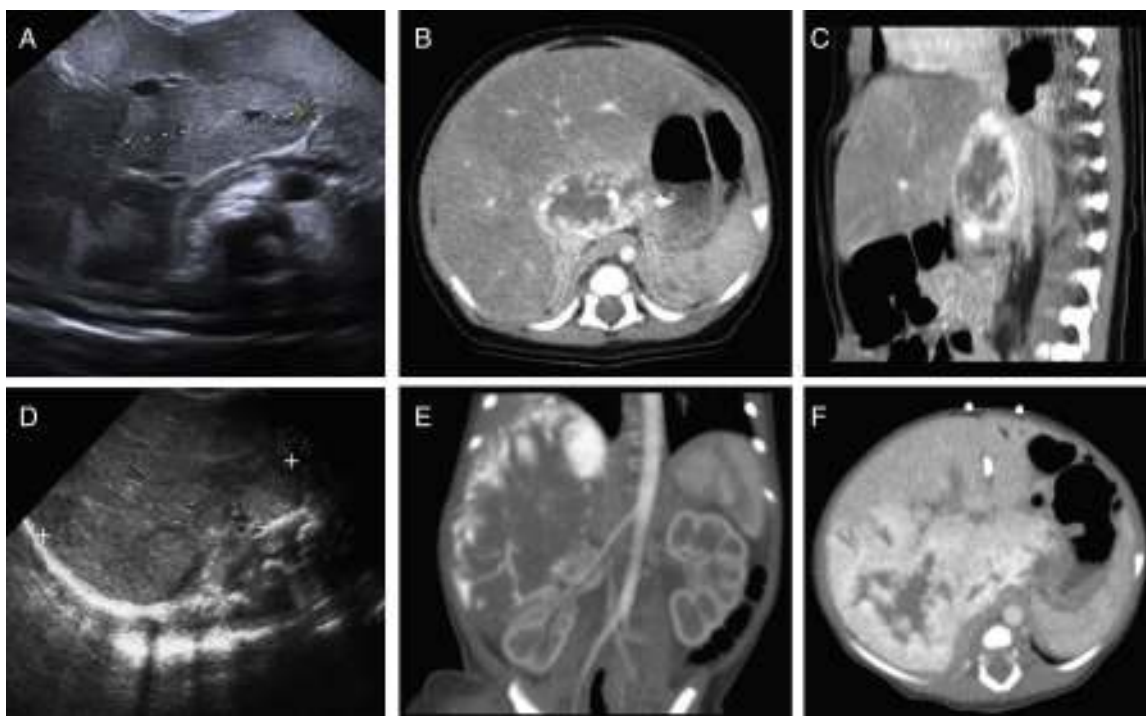
<sup>☆</sup> Please cite this article as: Baena-Gómez MA, Priego Ruiz MP, González EM, Rosa MJ, Muñoz Sánchez RM. Hemangiomas hepáticos: respuesta espectacular al tratamiento con propranolol. *An Pediatr (Barc).* 2015;83:435–437.

**Table 1** Response to treatment with propranolol of cases of hepatic haemangioma published in the literature.

Ref.	Case	Type of HH	Initial treatment	Response to treatment with propranolol
1	Girl, 6 weeks	Multifocal	-	Gradual and complete regression of one of the lesions at 5 and 13 weeks
	Girl, 8 weeks	Multifocal	-	Partial regression at 2 months and complete regression at 16 months <sup>a</sup>
	Boy, 3 months	Diffuse	-	Significant regression by 4 months
2	Boy, 3 weeks	Multifocal	-	Complete regression by 4 months
3	Girl, 15 weeks	Multifocal	-	Near-complete regression at 25 weeks <sup>a</sup>
4	Girl, 10 days	Multifocal	-	Complete regression at 1 month
5	Boy, 5 weeks	Diffuse	-	Partial regression at 20 days <sup>a</sup>
	Girl, 2 weeks	Diffuse	Corticosteroids	Near-complete regression at 3 years of age

HH, hepatic haemangioma; Ref., bibliographic reference.

<sup>a</sup> Treatment with propranolol combined with corticosteroids.



**Figure 1** Case 1: (A) abdominal ultrasound: area of altered echogenicity in liver 37 mm × 21 mm of axial diameter with increased vascularisation. CT angiogram: (B) axial plane, arterial phase. (C) Sagittal plane, portal venous phase. Lesion in hepatic parenchyma anterior to the vena cava in segment I and part of segments VII, IV and II, 43 mm × 22 mm × 34 mm, with peripheral nodular enhancement in the arterial phase and centripetal fill-in in the portal venous phase. Case 2: (D) abdominal ultrasound: right hepatic lobe replaced by a homogeneous 90 mm × 50 mm mass with multiple intralesional vessels, with additional focal alterations of echogenicity in the left hepatic lobe. CT angiogram: (E) coronal plane in the arterial phase. (F) Axial plane in the portal venous phase: large liver mass, 90 mm × 86 mm × 70 mm, practically occupying the entire right hepatic lobe, sparing segments II, III and part of segment IV, showing marked peripheral nodular enhancement with centripetal progression during the portal venous phase. Several nodular foci with the same behaviour were also observed in the left hepatic lobe.

alternative to interferon, due to the latter's side effects,<sup>2</sup> and cyclophosphamide.<sup>4</sup> Embolisation and surgery are other possible treatment options.<sup>1</sup>

Since 2008, propranolol has been used successfully for the treatment of cutaneous IHS. It acts by stopping the growth of the lesion during the proliferative phase and inducing a rapid involution, effects that have not been observed with other therapies.<sup>1</sup> Its efficacy and safety in the treatment of IHS has been demonstrated by an international

randomised controlled trial that established a treatment dose of 3 mg/kg/day.<sup>6</sup>

Table 1 shows the response to treatment with propranolol of different cases of multifocal and diffuse HHs published in the literature. Administration of propranolol was associated with bradycardia in one case,<sup>3</sup> and no other adverse effects have been reported. When the dose was lowered, an increase in the size of the mass was observed despite continued corticosteroid therapy.<sup>3</sup>

We present two cases of neonatal HH diagnosed and treated with propranolol in our hospital.

The first one corresponded to a full-term female newborn, large for gestational age and born to a diabetic mother (BDM). The abdominal ultrasound performed during the routine screening of newborns BDM revealed a liver lesion, with features compatible with HH in abdominal computed axial tomography (CAT) (Fig. 1A–C). Treatment with propranolol was initiated at 13 days post birth at a dose of 1 mg/kg/day, which was increased gradually to 3 mg/kg/day with no associated adverse effects. At 4 months of life, there were no signs of the liver lesion on ultrasound examination, and the beta blocker was tapered off. However, at 15 months a recurrence of HH with a 17 mm lesion was observed adjacent to the vena cava, which resolved spontaneously. Currently, at 24 months of age, the tumour is in full remission.

The second case corresponded to a full-term newborn girl with normal weight transferred to our hospital at 2 days of life for a mass in the right abdomen that extended to the right iliac fossa associated with significant abdominal distension and collateral circulation. Abdominal ultrasonography showed a mass in the right hepatic lobe, and the findings of abdominal CAT were compatible with diffuse HH (Fig. 1D–F). At 4 days of life, treatment with VCR, methylprednisolone and propranolol at 0.5 mg/kg/day was initiated along with a pre-transplant evaluation. The ultrasound followup at 10 weeks of treatment showed a 70 × 50 mm lesion, with barely discernible lesions in the left hepatic lobe, so VCR was discontinued and corticosteroid therapy was tapered off, continuing treatment with beta blockers alone from the second month of life at the maximum dose of 3 mg/kg for a total duration of 15 months, which the patient tolerated well, with gradual reduction of the HH. Currently, at age 5 years, the patient is in full remission.

In conclusion, propranolol could be used as the first-line treatment of multifocal and diffuse HHs given its efficacy and safety, minimising the risks associated with other treatment options. We assume that, as occurs in cases of

cutaneous IHS, it acts by stopping the proliferation of the mass and inducing its remission.

## References

- Mhanna A, Franklin WH, Mancini AJ. Hepatic infantile hemangiomas treated with oral propranolol – a case series. *Pediatr Dermatol.* 2011;28:39–45.
- Tan ST, Itinteang T, Leadbitter P. Low-dose propranolol for multiple hepatic and cutaneous hemangiomas with deranged liver function. *Pediatrics.* 2011;127:e772–6.
- Bosemani T, Puttgen KB, Huisman TA, Tekes A. Multifocal infantile hepatic hemangiomas – imaging strategy and response to treatment after propranolol and steroids including review of the literature. *Eur J Pediatr.* 2012;171:1023–8.
- Cavalli R, Novotna V, Buffon RB, Gelmetti C. Multiple cutaneous and hepatic infantile hemangiomas having a successful response to propranolol as monotherapy at neonatal period. *G Ital Dermatol Venereol.* 2013;148:525–30.
- Yeh I, Bruckner AL, Sanchez R, Jeng MR, Newell BD, Frieden IJ. Diffuse infantile hepatic hemangiomas: a report of four cases successfully managed with medical therapy. *Pediatr Dermatol.* 2011;28:267–75.
- Léauté-Labrèze C, Hoeger P, Mazereeuw-Hautier J, Guibaud L, Baselga E, Posiunas G, et al. A randomized, controlled trial of oral propranolol in infantile hemangioma. *N Engl J Med.* 2015;372:735–46.

M.A. Baena-Gómez<sup>a,\*</sup>, M.P. Priego Ruiz<sup>a</sup>, E.M. González<sup>a</sup>, M.J. Peña Rosa<sup>a</sup>, R. Muñoz Sánchez<sup>b</sup>

<sup>a</sup> *Unidad de Gestión Clínica de Pediatría y sus Áreas Específicas, Hospital Universitario Reina Sofía, Córdoba, Spain*

<sup>b</sup> *Unidad de Gestión Clínica de Radiología, Hospital Universitario Reina Sofía, Córdoba, Spain*

\*Corresponding author.

E-mail address: [mabaenagomez@gmail.com](mailto:mabaenagomez@gmail.com)

(M.A. Baena-Gómez).

## Clinical and epidemiological characteristics of neonatal influenza<sup>☆</sup>

### Características clínicas y epidemiológicas de la gripe neonatal

Dear Editor:

Influenza is a viral infection affecting the general population, but especially the very old and the very young. Paediatric influenza is found primarily in children under 5 years old. The symptoms are fairly non-specific below

2 years of age and it is only from the age of 4–5 years that its clinical manifestations can guide us towards this disease.<sup>1</sup>

There are few existing studies on neonatal influenza (at less than 28 days of age) that focus on the influenza A (H1N1) pandemic.<sup>2–4</sup> For this reason we present a prospective study on the cases detected in the last 3 influenza seasons (2012/13, 2013/14 and 2014/15).

A nasopharyngeal aspirate was taken from patients who attended the emergency department during the flu months. Influenza viruses were detected using a real-time RT-PCR (reverse transcription polymerase chain reaction) technique (Anyplex<sup>®</sup> RV16; Seegene, South Korea). The medical records of neonates diagnosed with influenza were reviewed.

Over the course of the 3 seasons 1215 cases of flu were diagnosed, 631 (51.9%) of which were in children under 15 years of age. Of these, 21 cases presented in neonates (3.3% of the total number of influenza cases studied). The mean

<sup>☆</sup> Please cite this article as: Reina J, Ferrés F. Características clínicas y epidemiológicas de la gripe neonatal. *An Pediatr (Barc).* 2015;83:437–438.