

## Propionic acidemia and long QT syndrome: A potentially serious combination<sup>☆</sup>



### Acidemia propiónica y síndrome QT largo: una asociación potencialmente grave

Dear Editor:

Propionic acidemia (OMIM 606054) is an autosomal recessive organic acid metabolism disorder that involves a defective form of propionyl-CoA carboxylase (PCC). The disease usually manifests with acute and potentially fatal episodes of metabolic decompensation and delays in cognitive development. Its association with cardiomyopathy, usually dilated, is well known, and usually manifests during the episodes of metabolic decompensation. More recently, propionic acidemia has been associated with long QT syndrome<sup>1,2</sup> (the normal range in children older than 1 year is defined by a heart-rate corrected QT interval [QTc] < 440 ms),<sup>3</sup> which can predispose the patient to the development of ventricular arrhythmias and sudden death. Its exact aetiology is not known and its treatment is similar to that of long QT without associated propionic acidemia.

We present the case of one girl with propionic acidemia in whom the electrocardiogram (ECG) revealed prolongation of the QTc.

The patient was a girl aged 10 years diagnosed in the neonatal period as having propionic acidemia and followed up by the congenital errors of metabolism unit. The patient was undergoing treatment with L-carnitine and a protein-restricted diet. She was referred to the paediatric cardiology unit for assessment. The patient had no cardiovascular symptoms. There was no family history of sudden death or heart disease. The findings of the physical examination and echocardiogram were normal. The ECG revealed a sinus rhythm with normal voltages, but with a QTc interval of 500 ms (calculated by Bazett's formula) and repolarization abnormalities with negative T waves in the inferior (II, III and aVF) and left precordial leads (V4–V6) (Fig. 1). Both parents were evaluated, and the ECG did not reveal any abnormal findings in either. The patient wore a Holter monitor for 24 h, which recorded a maximum QTc of 500 ms, with no evidence of arrhythmias. Laboratory tests were performed, including measurement of electrolyte, glucose, ammonia, plasma amino acids and acylcarnitine levels, the results of which were normal. Treatment of long QT syndrome was initiated with oral propranolol. Subsequent evaluations showed that the patient remained free of cardiovascular symptoms and tolerated therapy with propranolol, while prolongation of the QTc persisted in the ECG (QTc, 440–480 ms).

Propionic acidemia is caused by the deficient activity of PCC, a biotin-dependent mitochondrial enzyme needed for the conversion of propionyl-CoA to D-methylmalonyl-CoA. PCC is a heteropolymer composed of two types of subunits,

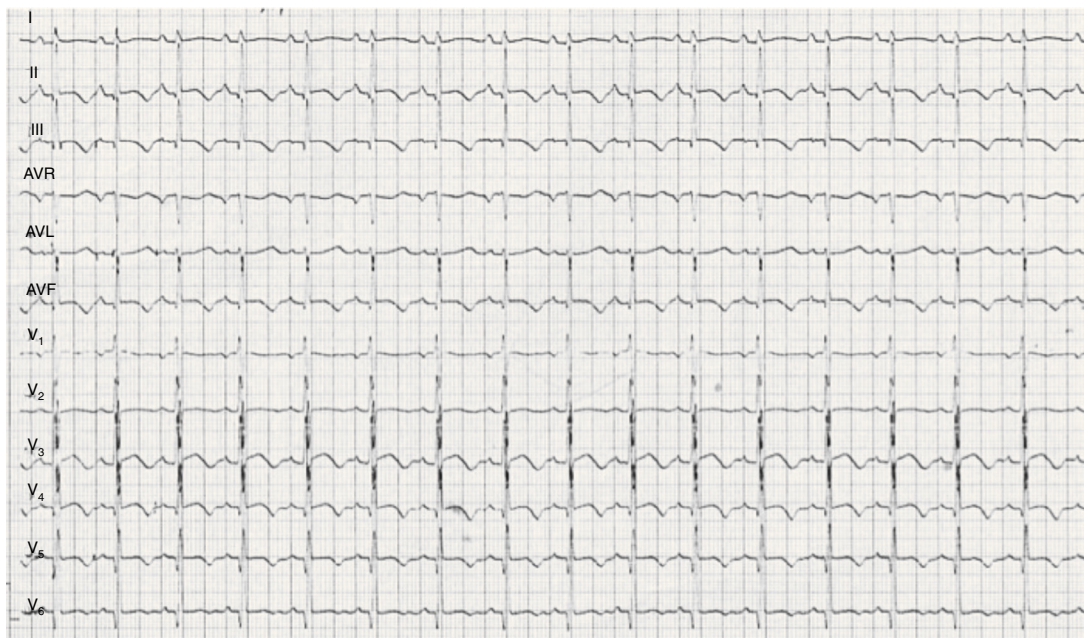


Figure 1 ECG: QTc interval 500 ms, negative T waves in leads II, III, aVF, V4, V5 and V6.

<sup>☆</sup> Please cite this article as: Moure AF, Jiménez MC, García-Rovés RÁ, Villanueva NG, López CM. Acidemia propiónica y síndrome QT largo: una asociación potencialmente grave. *An Pediatr (Barc)*. 2015;83:281–282.

$\alpha$  and  $\beta$ , that are encoded by the *PCCA* gene (13q32) and *PCCB* gene (3q21-q22), respectively. Mutations in these genes cause the disease. The genetic defect leads to the intramitochondrial accumulation of propionyl-CoA that is metabolised by secondary pathways to other metabolites. Its prevalence is of one case per 100,000 live births worldwide. It can present in the following forms: severe neonatal onset, intermittent late onset or a chronic progressive form.

Cardiac involvement is relatively frequent, and cardiomyopathy develops in one-fourth to one-third of patients with propionic acidaemia, which does not respond to supplementation with carnitine.<sup>4</sup> On the other hand, a recent prospective longitudinal study of 10 patients with propionic acidaemia<sup>5</sup> found that 70% of them had a prolonged QT interval (QTc > 440 ms), and that the interval was longer than 460 ms in 60%. The lengthening of the QT interval was unrelated to the metabolic status of the patients. It was observed both in school-aged children and adolescents, but not in infants. The same study reported that the most frequent ECG changes besides QT prolongation were repolarization abnormalities with T-wave inversion in leads V4–V6, abnormalities that we also found in the ECGs of our patient.

Although the exact underlying mechanism of the association between these two entities remains unknown, some authors have proposed that changes in heart conduction could be due to carnitine deficiency.<sup>6</sup>

From the perspective of clinical practice, this case suggests that patients with propionic acidaemia may be at greater risk of experiencing prolongation of the QT interval, so we recommend a yearly cardiovascular evaluation including a 12-lead ECG and a 24-h Holter recording in addition to the echocardiogram. If the presence of long QT syndrome were confirmed, initiation of beta-blocker therapy would be indicated to prevent ventricular arrhythmias, syncope or sudden death. It is also important that the parents and the patient are informed of the risk of using various

medicines that may lengthen the QT interval and thus promote the development of ventricular arrhythmias.

## References

1. Kakavand B, Schroeder VA, di Sessa TG. Coincidence of long QT syndrome and propionic acidemia. *Pediatr Cardiol.* 2006;27:160–1.
2. Jameson E, Walter J. Cardiac arrest secondary to long QTc in a child with propionic acidemia. *Pediatr Cardiol.* 2008;29:969–70.
3. Goldenberg I, Moss AJ, Zareba W. QT interval: how to measure it and what is normal. *J Cardiovasc Electrophysiol.* 2006;17:333–6.
4. Reid Sutton V, Chapman KA, Gropman AL, MacLeod E, Stagni K, Summar ML, et al. Chronic management and health supervision of individuals with propionic acidemia. *Mol Genet Metab.* 2012;105:26–33.
5. Baumgartner D, Scholl-Bürgi S, Sass JO, Sperl W, Schweigmann U, Stein JI, et al. Prolonged QTc intervals and decreased left ventricular contractility in patients with propionic acidemia. *J Paediatr.* 2007;150:192–7.
6. Rijlaarsdam RS, van Spronsen FJ, Bink-Boelkens MTE, Reijngoud DJ, Wanders RJA, Niezen-Koning KE, et al. Ventricular fibrillation without overt cardiomyopathy as first presentation of organic cation transporter 2-deficiency in adolescence. *Pace.* 2004;27:675–6.

A. Fuertes Moure<sup>a,b,\*</sup>, M. Centeno Jiménez<sup>b</sup>,  
R. Álvarez García-Rovés<sup>a,b</sup>, N. Gil Villanueva<sup>b</sup>,  
C. Medrano López<sup>b</sup>

<sup>a</sup> *Instituto de Investigación Sanitaria, Hospital Universitario Gregorio Marañón, Madrid, Spain*

<sup>b</sup> *Sección de Cardiología Pediátrica, Hospital Universitario Gregorio Marañón, Madrid, Spain*

\* Corresponding author.

E-mail address: [angelesfm@hotmail.es](mailto:angelesfm@hotmail.es) (A. Fuertes Moure).

## Contribution of serial neurophysiological studies in atypical Guillain-Barré syndrome<sup>☆</sup>



## Contribución de los estudios neurofisiológicos seriados en el síndrome de Guillain-Barré atípico

Dear Editor:

Guillain-Barré syndrome (GBS) is the most common cause of acute flaccid paralysis in children.<sup>1</sup> It is characterised

by symmetric ascending motor weakness and areflexia. GBS encompasses a group of acute immune-mediated acquired polyradiculoneuropathies that are usually preceded by gastrointestinal or respiratory infections. The most common forms are classified on the basis of neurophysiological criteria as acute inflammatory demyelinating polyradiculoneuropathy (AIDP) and acute motor axonal neuropathy (AMAN).<sup>2</sup> While both forms may be clinically indistinguishable, their prognosis can be very different. We present a case in which serial neurophysiological studies were key in the identification of a case of GBS with an atypical presentation, its classification as AMAN, and the assessment of the patient's outcome.

A male patient 7 years of age with no medical or surgical history of interest sought care in the emergency department for pain in the lumbar region and the right triceps surae accompanied by limited mobility in climbing and going down stairs lasting 11 days. We observed that the patient had difficulty walking on his toes, and the rest of the neurological examination was normal, including the deep tendon reflexes (DTRs). The findings of the lower limb X-rays were normal.

<sup>☆</sup> Please cite this article as: Álvarez Guerrero I, Mínguez P, Aznar Laín G, Rubio MA, Royo I. Contribución de los estudios neurofisiológicos seriados en el síndrome de Guillain-Barré atípico. *An Pediatr (Barc).* 2015;83:282–284.