An Pediatr (Barc). 2014;81(5):289–296

analesdepediatría

www.analesdepediatria.org

ORIGINAL ARTICLE

Tuberous sclerosis: Clinical characteristics and their relationship to genotype/phenotype☆

T. Monteiro, C. Garrido, S. Pina, R. Chorão, I. Carrilho, S. Figueiroa, M. Santos, T. Temudo*

Centro Materno-Infantil do Norte, Porto, Portugal

Received 17 September 2013; accepted 25 March 2014
Available online 28 October 2014

KEYWORDS
Changes in behaviour;
Tuberous sclerosis;
Cognitive deficit;
Phenotype;
Genotype;
Epilepsy;
Brain magnetic resonance imaging

Abstract
Introduction: Tuberous sclerosis (TS) is an inherited disorder with multisystemic involvement and a high phenotypic variability. There are two genes that cause this condition: TSC1 and TSC2.
Objectives: Our goal was to clinically characterise patients with TS followed up in the Pediatric Neurology Clinic of a tertiary hospital during the last 10 years, and correlate the genotype with the severity of neurological manifestations and imaging studies.
Patients and methods: Retrospective analysis of patients with TS, including review of medical records and available MRI imaging.
Results: We studied 35 cases with a median age at diagnosis of 10 months. Seizures were the first manifestation in 91.4% of cases, with a predominance of epileptic spasms. Over 50% had cognitive impairment and 49% behavioural disorders.

A genetic study was performed on 24 children, and TSC2 mutations identified in 58.3% of them. Of the 11 cases of refractory epilepsy, six had the TSC2 gene mutation. In the group of eight patients with moderate/severe cognitive deficits, five had TSC2 mutations.

We reviewed 26 MRI scans, in which it was observed that 76.9% had diffuse involvement of cerebral lobes, which reflects a greater burden of injury. Of the patients who had an MRI scan performed and had TSC2 mutations, all had a high tuber load, and 5 of them had refractory epilepsy.
Discussion: In our sample we observe a high percentage of mutations in the TSC2 gene. This mutation carries a worse neurological prognosis, with drug-resistant epilepsy and a more severe cognitive impairment.
© 2013 Asociación Española de Pediatría. Published by Elsevier España, S.L.U. All rights reserved.

☆ Please cite this article as: Monteiro T, Garrido C, Pina S, Chorão R, Carrilho I, Figueiroa S, et al. Esclerosis tuberosa: caracterización clínica e intento de correlación fenotipo/genotipo. An Pediatr (Barc). 2014;81:289–296.

* Corresponding author.
E-mail address: teresatemudo@hotmail.com (T. Temudo).

2341-2879/© 2013 Asociación Española de Pediatría. Published by Elsevier España, S.L.U. All rights reserved.

PALABRAS CLAVE
Alteraciones del comportamiento;
Esclerosis tuberosa;
Déficit cognitivo;
Fenotipo;
Genotipo;
Epilepsia;
Resonancia magnética cerebral

Esclerosis tuberosa: caracterización clínica e intento de correlación fenotipo/genotipo

Resumen
Introducción: La esclerosis tuberosa (ET) es una enfermedad de afectación multisistémica y gran variabilidad fenotípica. Están identificados 2 genes involved en la génesis de la enfermedad: TSC1 y TSC2.
Objetivos: Caracterizar clínicamente a los pacientes con ET seguidos en Neurología Pediátrica de un hospital de tercer nivel durante los últimos 10 años y correlacionar el genotipo con la gravedad de la clínica neurológica y los estudios de imagen.
Pacientes y métodos: Estudio retrospectivo descriptivo, mediante consulta de la historia clínica y evaluación de las resonancias magnéticas (RM) de pacientes con ET.
Resultados: Se estudiaron 35 casos, con una mediana de edad, al diagnóstico, de 10 meses. En el 91,4% se registraron crisis epilépticas, con un predominio de espasmos epilépticos a la presentación.
Más del 50% tenía deterioro cognitivo y el 49% trastornos de conducta.
Se sometieron a estudio genético 24 niños con predominio de mutaciones TSC2 (58,3%). De los 11 casos de epilepsia refractaria, 6 tenían mutación del gen TSC2. De los 8 pacientes con déficit cognitivo moderado a grave, se identificaron 5 mutaciones TSC2.
Se revisaron 26 RM y en el 76,9% se observó una afectación completa de los lóbulos cerebrales, lo que refleja una gran cantidad de lesiones. De los enfermos con mutaciones TSC2 y RM realizada, todos tenían alta carga de lesión y 5 epilepsia refractaria.
Discusión: En nuestra muestra, nos encontramos con un alto porcentaje de mutaciones en el gen TSC2. Esta mutación está asociada a un peor pronóstico neurológico, con crisis más farmacorresistentes y un atraso cognitivo más severo.
© 2013 Asociación Española de Pediatría. Publicado por Elsevier España, S.L.U. Todos los derechos reservados.

Introduction

Tuberous sclerosis (TS) is a multisystem neurocutaneous disorder. Its observed features are the result of disrupted cell differentiation, proliferation, and migration in the early stages of foetal development.[1]

Tuberous sclerosis is an autosomal dominant genetic disorder with an incidence of approximately 1 in 5000–10,000 births.[2] So far, 2 genes have been identified that are involved in its aetiology: TSC1 (chromosome 9q34) and TSC2 (chromosome 16p13.3). Only 7–37% of patients have a positive family history of TS, as most cases (65–75%) correspond to de novo mutations.[3] There was also a highly variable range of phenotypic expression, age at onset, signs and symptoms, and severity of disease.

A disease-causing mutation is found in 60–89% of patients that meet the criteria for TS, and it is estimated that approximately 50% correspond to mutations in the TSC2 gene and 17% to mutations in the TSC1 gene.[4–6]

TS is characterised by the development of benign tumours in multiple organs.[7] In addition, there is an increased risk of malignancy.[8]

The diagnosis of TS is based solely on clinical criteria (Table 1). It is categorised as *definite TS* if 2 major features or 1 major feature and 2 minor features are present; as *probable TS* if 1 major feature and 1 minor feature are present; and *possible TS* if 1 major feature or 2 or more minor features and no major features are present. Genetic testing is useful for family studies or to confirm TS.

Neurologic symptoms are present in 85% of cases and constitute the main cause of morbidity and mortality.[3] Epilepsy and cognitive deficits are commonly associated to brain lesions, including glioneuronal hamartomas (also called tubers), white matter lesions, and subependymal giant cell astrocytomas.[9]

Epilepsy usually appears in the first year of life, and infantile spasms are a common presentation (36–96%).[10] The number of glioneuronal hamartomas, and especially the proportion of the total brain volume they occupy, are associated with the presence of severe cerebral dysfunction (refractory epilepsy and/or moderate to severe cognitive impairment).[1,11] The association between the severity of seizures and the presence of cyst-like cortical tubers has also been established.[12]

It is estimated that 50% of TS patients have cognitive impairments, the severity of which is associated with having a history of infantile spasms or refractory epilepsy, and to the number and proportion of brain volume occupied by glioneural hamartomas.[13]

Behavioural problems are present in 40–90% of TS patients. Although behavioural changes may develop irrespective of the level of cognitive function, it has been demonstrated that cognitive disability and greater seizure frequency are risk factors for the presence of behavioural difficulties.[14]

Dermatologic features can appear in 81–95% of TS cases, the most common being hypomelanotic macules, angiofibromas, ungual fibromas, Shagreen patches, and fibrous

Table 1 Diagnostic criteria for tuberous sclerosis: Roach.

Major features	Minor features
Facial angiofibromas/forehead plaque	''Confetti'' skin lesions
Shagreen patch	Gingival fibromas
≥3 hypomelanotic macules	Pits in dental enamel
Ungual or periungual fibromas	Hamartomatous rectal polyps
Lymphangiomyomatosis	Multiple renal cysts
Renal angiomyolipoma	Nonrenal hamartoma
Cardiac rhabdomyoma	Bone cysts
Multiple retinal nodular hamartomas	Retinal hamartoma
Cortical tuber	Cerebral white-matter radial migration tracts
Subependymal nodules	
Subependymal giant cell astrocytoma	

plaques.[10,15] There is no significant risk of malignant transformation of skin lesions.

Between 50% and 60% of TS patients have cardiac manifestations, with rhabdomyoma being the most frequent. They are benign tumours, often multifocal, and usually asymptomatic. Most rhabdomyomas regress spontaneously.

Renal features are found in 60–80% of TS patients, and the most common form is angiomyolipoma. Renal lesions are usually benign and carry a haemorrhage risk in relation to their size. They also carry a high risk of developing renin-dependent hypertension and chronic renal disease due to the compression and replacement of renal parenchyma. Renal cell carcinoma develops in approximately 1–2% of adults, so regular monitoring with ultrasonography is recommended.

Ophthalmic manifestations are present in 87% of TS patients. Although they are useful in making the diagnosis, they rarely affect visual acuity, and do not require specific treatment.[16]

Genotype-phenotype correlations in TS have been investigated since the 2 genes associated with the disease were first identified. Several studies have concluded that mutations in the TSC1 gene are associated to a milder phenotype than TSC2 mutations, but there is disagreement on this point.[15–17] While mutations in the TSC2 gene are usually associated with more severe phenotypes (with increased frequency of refractory epilepsy, cognitive impairment, and behavioural changes), mild phenotypes have also been described for TSC2 mutations.[17]

Objectives

Our aim was to analyse the clinical characteristics of TS patients followed in the paediatric neurology department of the Centro Hospitalario del Porto (CHP) in the past 10 years, and to correlate patient genotypes with the severity of neurologic manifestations and radiographic findings.

Patients and methods

We conducted a descriptive retrospective analysis of patients with definitive TS (based on the clinical diagnostic criteria) followed in the paediatric neurology department of a tertiary hospital, the CHP, in Porto, Portugal. Data were collected from electronic medical histories and paper clinical notes.

We used Microsoft Office Excel 2007 to perform the descriptive statistical analysis. The variables analysed were: current age; sex; age at diagnosis; family history; presence and presentation of epilepsy; psychomotor development; behavioural, cutaneous, cardiac, renal, and ophthalmic abnormalities; and genetic study.

All the magnetic resonance (MR) images analysed were reviewed independently by a single neuroradiology specialist, and used to investigate the following variables: number of tubers, supratentorial or infratentorial location, number of cerebral lobes with lesions, number and lateralisation of cyst-like tubers, radial migration lines in the white matter, subependymal nodules, and giant cell astrocytomas. MR imaging was performed on a 1.5 T GE Signa system or on a 3.0 T TX Philips Achieva system (3 patients) in the neuroradiology department of the CHP. A preliminary localising scan in the sagittal plane was used to identify anterior and posterior commissures and to position the axial images in parallel to the intercommissural plane: FLAIR, T2 SE, T2 *, T1 SE and T1 SE post-contrast.

FLAIR images were used to identify tubers and radial migration lines,[18] and T2-weighted FLAIR images to identify subependymal nodules.

Tubers were defined as corticosubcortical lesions with high signal intensity on FLAIR images, and radial migration lines as lines of hyperintensity on FLAIR images extending from the ventricles to tubers in the cortex. Subependymal nodules were found in all ventricles, protruding into the ventricles from the ventricular wall.

Tubers with subcortical cysts were defined as lesions with cerebrospinal fluid signal characteristics on MRI bordered by a hyperintense rim in T2 scans. Tubers and Calcified tubers and subependymal nodules showed low signal in T2 and T2* scans. Since the density of tubers in brain parenchyma is suggested as the best marker of severity of epilepsy and cognitive function[1], we performed a qualitative assessment of brain tubers density by estimating the frequency of tubers in each cerebral lobe. The density of tubers reflects brain lesion load, obtained by evaluation of the total number of tubers and involvement of each brain lobe by tubers. High brain lesion load was considered if all cerebral lobes contained tubers in patients with total number of more than 15. Quantitative assessment with automatic segmentation

of tuber density or brain volume occupied by tubers was not performed due to inaccessibility to appropriate software.

Formal cognitive assessments were performed depending on the age group with the Ruth Griffiths mental development scale and/or the Wechsler scale (WISC-R or WISC-III) in the psychology clinic of the CHP. Cognitive deficit was defined as an intellectual quotient (IQ) below 70, with the following severity levels: mild, with IQ ranging from 50–55 to 70; moderate ranging from 35–40 to 50–55; severe 20–25 to 35-40; and profound, less than 20–25. Cognitive deficit was classified as ''unspecified'' when it had not been assessed but it was presumed (with IQ <70).[19]

The genetic studies were performed in 2 specialised laboratories: the Centro de Genética Médica (Centre of Medical Genetics), Porto, through the Erasmus MC University Medical Center in Rotterdam, using direct sequence analysis and multiplex ligation-dependent probe amplification analysis; and in the Centro de Genética Clínica (Centre of Clinical Genetics), Porto, by polymerase chain reaction (PCR) and direct sequencing of the full encoding region of the TSC1 and TSC2 genes and the adjacent intron regions; quantitative PCR was also performed to study deletions of the TSC2 gene.

Refractory epilepsy was defined as failure to control seizures despite treatment with 2 or more appropriately chosen and administered antiepileptic drugs.[20]

Results

We analysed 35 cases of definitive TS, characterised in Table 2.

A genetic study was done in 24 children, and a mutation identified in 79.2% (19) of the cases, with TSC2 mutations being most frequent (58.3%) compared to TSC1 mutations (20.8%).

There was a positive family history in 25.7% (9) of the cases: a single first-degree family member was affected in 3 cases; 2 family members were affected in 2 cases, and in 4 cases, first-degree family members (parents or siblings) were diagnosed after the patient's own diagnosis.

Table 2 Clinical characteristics of 35 patients with tuberous sclerosis.

	% (*N*)	Additional information
Male/Female sex	60.0 (21)/40.0 (14)	
Current age min/max/median	8 months/28 years/12 years	
Age at diagnosis min/max/median	Prenatal/7 years/15 months	
Diagnosis in the first year of life	65.7 (23)	82.9% (29) in the first 2 years
Positive genetic test	79.2 (19)/24	
TSC2/TSC1	58.3 (14)/20.8 (5)	
Positive family history	25.7 (9)	36.8% (7) in the mutation group
Main reason for referral-epilepsy	77.1 (27)	20.0% (7) neurological screening done for suspected TS
Epilepsy	91.4 (32)	Infantile spasms, 53.1% (17)
		Focal seizures, 34.4% (11)
		Generalised seizures, 6.3% (2)
		71.9% (23) seizures in the 1st year of life
		34.4% (11) refractory epilepsy
Cognitive deficit	57.1 (20)	Mild 50.0% (10)
		Moderate 25.0% (5)
		Severe 15.0% (3)
		Not specified, but seemingly with IQ < 70–10.0% (2)
Behavioural disorders	48.6 (17)	Oppositional conduct 5
		Hyperactivity and/or inattention 5
		Aggressiveness 4
		Stereotypes and/or mannerisms 3
		Autistic spectrum disorder 1
Cardiac	42.9 (15)	Rhabdomyoma 93.3% (14)
		Multifocal 8/14
		Arrhythmia 2 (one with multifocal rhabdomyoma)
Renal	42.9 (15)	Angiomyolipoma 80.0% (12)
		Benign cysts 53.3% (8), 5 associated to angiomyolipoma
		HTN 1
Ophthalmic	20.0 (7)	Retinal hamartoma 4
		Non-retinal lesions 2
		Chorioretinal depigmentation 1
Dermatologic	74.3 (26)	Hypomelanotic macules 80.8% (21), 11 associated to angiofibroma and 1 fibrous plaques
		Isolated angiofibroma 5

HTN: Hypertension.

Table 3 Genotype/phenotype correlation.

	TSC1 (*N* = 5)	TSC2 (*N* = 14)
Refractory epilepsy (*N* = 11)	1	6
Controlled epilepsy	3 (1 without epilepsy)	8
Moderate and severe cognitive deficit with genetic study (*N* = 6/8)	0	5
Behavioural abnormalities with genetic study (11/17)	0	9
High lesion load in MR scan	1	13

In the group with identified mutations, 36.8% of patients had a positive family history: in 40.0% of patients with a TSC1 mutation (2/5) and 35.7% (5/14) of patients with a TSC2 mutation.

The reasons for referral to Paediatric Neurology consultation were: epilepsy in 77.1% (27) of cases, delay in psychomotor development associated to MRI abnormalities in 1 case, and neurologic disease screening in children with suspected TS in 7 cases (6 cases of cardiac hamartoma, 2 of which were associated to skin abnormalities; and 1 with a positive family history and skin abnormalities).

Epileptic seizures occurred in 91.4% (32) of the patients. Infantile spasms were the most frequent presentation, found in 53.1% (17). In 71.9% (23) of cases, the seizures started in the first year of life, and 34.4% (11) of the patients had refractory epilepsy.

Of the patients with well-controlled seizures, 11 were currently taking an antiepileptic drug, 2 were taking other medication, and 7 were not taking any medication. Only 1 case was treated with surgery and had a favourable outcome. Vigabatrin was the drug of choice in the treatment of infantile spasm (88.2%) as monotherapy or polytherapy.

Cognitive impairment was documented in 57.1% (20) of children, and behavioural disorders in 48.6% (17).

Cardiac manifestations were present in 42.9% (15) of patients, renal manifestations in 42.9% (15), and ophthalmic manifestations in 20.0% (7).

Dermatologic features were identified in 74.3% (26) of patients, and malignant transformations were not observed in any of the cases.

When we correlated the genotype to the clinical phenotype (Table 3), 6 of the 11 cases of refractory epilepsy were associated with mutations in TSC2 and only 1 case to a mutation in TSC1.

Of the remaining patients with TSC1 mutations, 1 had no seizures and 3 had well-controlled epilepsy. Among the patients with TSC2 mutations, 8 had well-controlled epilepsy (6 with pharmacological treatment, and 2 without).

A genetic study was performed in 6 of the 8 patients with moderate and severe cognitive deficit. None of these patients had a TSC1 mutation, and TSC2 mutations were identified in 5. Genetic studies were also performed in 11 patients with behavioural difficulties, identifying TSC2 mutations in 9 of the patients, and no TSC1 mutations.

Of the 8 patients with moderate and severe cognitive impairment, 5 had onset of seizures before 12 months of life. The 3 cases of severe cognitive delay were associated with refractory epilepsy and behavioural difficulties. However, 3 of the 16 cases of early onset epilepsy and infantile spasms had a normal psychomotor development (formal cognitive assessment performed at 3, 7, and 11 years of age).

In the 74.3% (26) patients for whom MRIs were available, 76.9% (20) of them had tubers in every cerebral lobe and more than 15 tubers in total, thus presenting high lesion load. Radial migration lines were observed in 96.2% (25) of the patients (Fig. 1). Subependymal nodules were found in 84.6% (22), most of them calcified, and 3 of them enhancing (Fig. 2). Infratentorial tubers were found in 23.1% (6) of the patients. Cyst-like tubers were present in 7 (26.9%) patients, with juxtacortical location in 6, and infratentorial location in 1 (Fig. 3). There was one probable case of giant cell astrocytoma, around the foramen of Monro, measuring less than 1cm, without hydrocephalus (Fig. 4). Focal atrophy was not found in any of the patients.

We reviewed the MR studies of all patients with an identified TCS2 mutation except one, and found a high lesion load in all of them. One of the 5 patients with a TSC1 mutation had a high lesion load. Of the 5 cases associated with refractory epilepsy, 2 had cyst-like tubers.

We found high lesion loads in 87.5% of the patients with cognitive delays and in 78% of patients in whom seizures appeared before 12 months of age. We also found radial

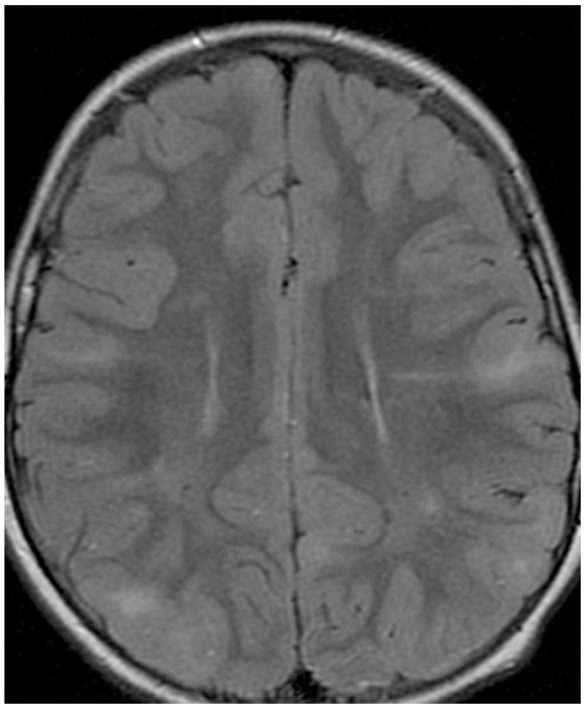

Figure 1 Axial FLAIR MRI showing multiple areas of cortico-subcortical high signal intensity (tubers) and radial migration lines.

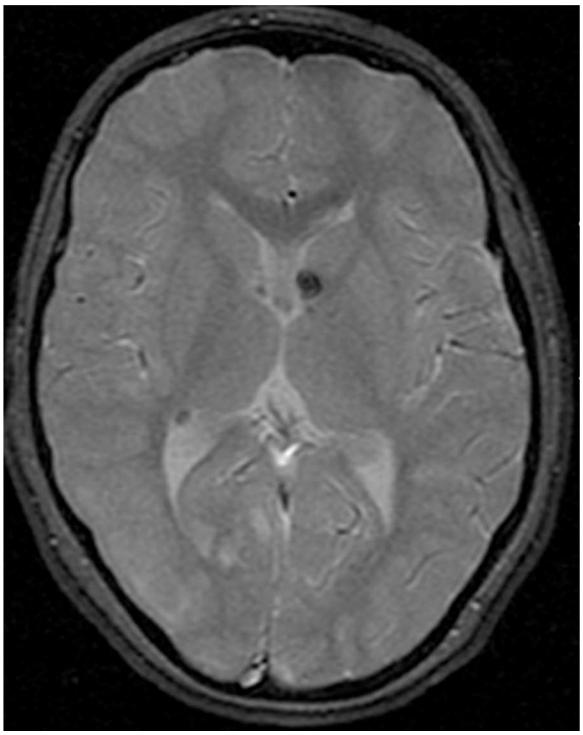

Figure 2 Axial T2-weighted MRI* showing supependymal foci of low signal intensity protruding into the ventricles, indicative of calcified subependymal nodules.

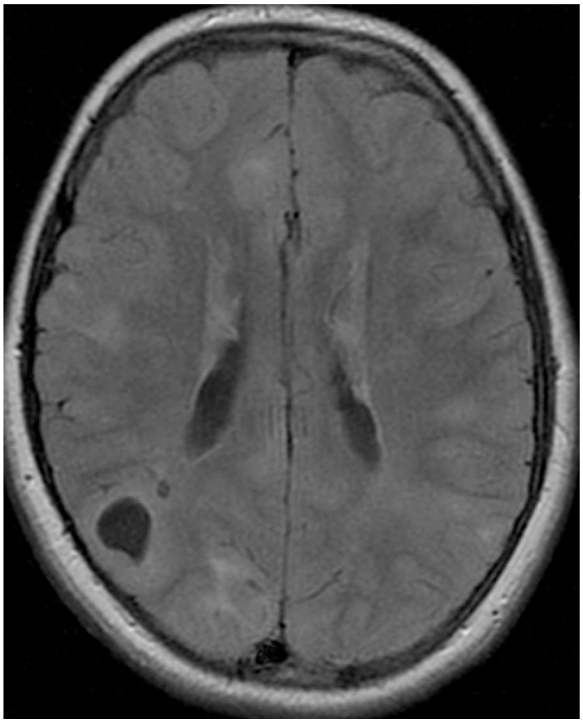

Figure 3 Axial FLAIR MRI, revealing right parietal cyst-like cortical tuber.

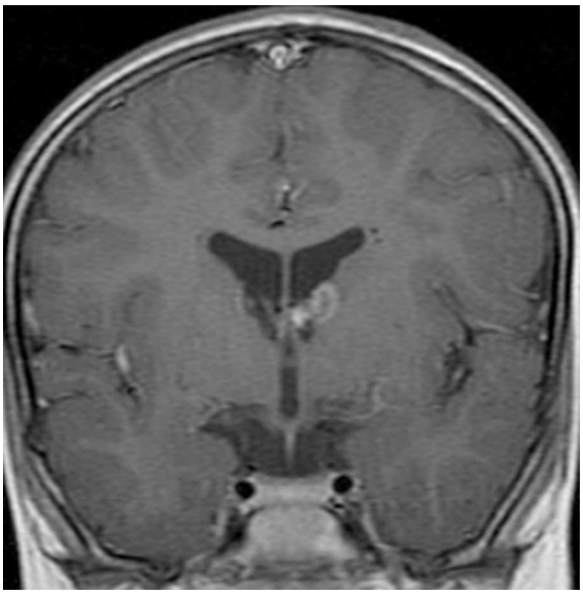

Figure 4 Coronal T1-weighted postgadolinium MRI showing giant cell astrocytoma adjacent to the Monro foramen on the left side.

migration lines in 89% of the children with early onset of epilepsy.

Discussion

Tuberous sclerosis is a multisystem disease with variable phenotypic expression, and its clinical manifestations may be subtle, nonspecific, and have onset at different ages, so diagnosis is often delayed.[21] Diagnosis occurred early in our series, perhaps because the main reason for referral to the department was infantile spasms, a condition whose association with TS is well known by health care professionals, may have facilitated the diagnosis.

Mutations were identified in 79.2% of the children who were subject to genetic studies, with predominance of TSC2 mutations, consistent with other publications.[4–6]

The number of cases with a positive family history was small,[3] and it was greater in the group of patients with identified mutations. In 4 cases, the family history was only identified in first-degree relatives (parents or siblings) after the patient was diagnosed, underscoring the importance of assessing the parents and siblings of children diagnosed with TS without a positive family history for the disease.[22]

As mentioned above, epilepsy was the main reason for referral,[1] manifested in most cases as infantile spasms with onset in the first year of life.

Disease severity and refractory epilepsy were positively correlated to early onset of seizures: seizures started before 12 months of age in all cases with refractory epilepsy.

Vigabratin was the drug used most often to treat infantile spasms in our TS patients (88.2%), consistent with the recommendations of researchers at the National Institute of Health Tuberous Sclerosis Complex Consensus Conference (2000), who considered it the most efficacious treatment option for infantile spasms due to TS.[23]

Cognitive deficits were documented in a high percentage of cases with great variability in severity, consistent with the literature (44–65%), and demonstrating the importance of making a formal cognitive evaluation in every patient newly diagnosed with TS. The purpose would be to implement early intervention programmes for affected children, and to improve their prognosis by means of cognitive interventions and stimulation.

Our results confirm the positive correlation between psychomotor development delay (PMDD) and epilepsy, as we observed onset of epilepsy in the first year of life and progression to refractory epilepsy in all cases with severe cognitive impairment.[9] On the other hand, there were patients in our sample who had infantile spasms and refractory epilepsy without PMDD. Behavioural disorders were very common and were associated with cognitive impairment and refractory epilepsy.

Consistent with previous studies, the most common cardiac manifestation of TS in our sample was rhabdomyoma (14/15), which was multifocal in a majority of cases (8/14). The percentage of renal and ophthalmic involvement was lower than that described in the literature, and no significant complications were documented (there was only one case of hypertension), probably because all our patients were in the paediatric age group. The percentage of cutaneous involvement was lower than what is typically described, which may be due to the poor documentation of these manifestations in the medical records.

Our data supported that neurologic outcomes are worse in patients with TSC2 mutations, showing a greater percentage of drug-resistant epilepsy, more severe cognitive deficits, a higher prevalence of behavioural disorders, and higher lesion loads in MRI.

We found a high lesion load in 87.5% of the patients with cognitive deficits and in 78% of the patients with early-onset seizures, consistent with the association between epilepsy, cognitive function, and lesion load found by other studies.[1]

In patients that underwent MR imaging, radial migration lines were the most common radiographic alteration (96.2%), approximating the 100% recently described by Van Eeghen et al.[24] This group of researchers also reported an association between radial migration lines and early onset of seizures, which was also consistent with our data.

We studied a paediatric sample to increase our knowledge of the main manifestations and comorbidities, the prognosis, and the severity of TS disease in this age group, and to help improve our clinical approach.

There are limitations to this study. It is a retrospective study based on medical records, and it has been conducted in a tertiary centre, with a selective bias for severe cases. We must also note the heterogeneity in the initial clinical evaluation and subsequent follow-up between different specialists, as well as in sample size and composition, which interferes with the statistical significance of our conclusions.

Performance of multicentre studies in the future will help develop a standard approach to the follow-up of these cases.

Conflicts of interest

The authors have no conflicts of interest to declare.

References

1. Jansen FE, Vincken KL, Algra A, Anbeek P, Braams O, Nellist M, et al. Cognitive impairment in tuberous sclerosis complex is a multifactorial condition. Neurology. 2008;70:916–23.
2. Plon SE, Owens J. Tuberous sclerosis complex: genetics, clinical features, and diagnosis. Available from: www.uptodate.com [accessed 3.04.13].
3. Curatolo P, Bombardieri R, Jozwiak S. Tuberous sclerosis. Lancet. 2008;372:657–68.
4. Jones AC, Shyamsundar MM, Thomas MW, Maynard J, Idziaszczvk S, Tomkins S, et al. Comprehensive mutation analysis of TSC1 and TSC2 and phenotypic correlations in 150 families with tuberous sclerosis. Am J Hum Genet. 1999;64:1305–15.
5. Au KS, Williams AT, Roach ES, Batchelor L, Sparagana SP, Delgado MR, et al. Genotype/phenotype correlation in 325 individuals referred for a diagnosis of tuberous sclerosis complex in the United States. Genet Med. 2007;9:88–100.
6. Niida Y, Lawrence-Smith N, Banwell A, Hammer E, Lewis J, Beauchamp RL, et al. Analysis of both TSC1 and TSC2 for germline mutations in 126 unrelated patients with tuberous sclerosis. Hum Mutat. 1999;14:412–22.
7. Ruiz-Falcó Rojas ML. Actualizacíon terapêutica en el complejo esclerosis tuberosa: el papel de los inhibidores de la via mTOR. Rev Neurol. 2012;54 Suppl. 3:S19–24.
8. Al-Saleem T, Wessner LL, Scheithauer BW, Patterson K, Roach ES, Dreyer SJ, et al. Malignant tumors of the kidney, brain, and soft tissues in children and young aduts with the tuberous sclerosis complex. Cancer. 1998;83:2208–16.
9. McClintock WM. Neurologic manifestations of tuberous sclerosis complex. Curr Neurol Neurosci Rep. 2002;2:158–63.
10. Yates JR, Maclean C, Higgins JN, Humphrey A, le Maréchal K, Clifford M, et al. The Tuberous Sclerosis 2000 Study: presentation, initial assessments and implications for diagnosis and management. Arch Dis Child. 2011;96:1020–5.
11. Goodman M, Lamm SH, Engel A, Shepherd CW, Houser OW, Gomez MR. Cortical tuber count: a biomarker indicating neurologic severity of tuberous sclerosis complex. J Child Neurol. 1997;12:85–90.
12. Chu-Shore CJ, Major P, Montenegro M, Thiele E. Cyst-like tubers are associated with TSC2 and epilepsy in tuberous sclerosis complex. Neurology. 2009;72:1165–9.
13. Winterkorn EB, Pulsifer MB, Thiele EA. Cognitive prognosis of patients with tuberous sclerosis complex. Neurology. 2007;68:62–4.
14. Kopp CM, Muzykewicz DA, Staley BA, Thiele EA, Pulsifer MB. Behavior problems in children with tuberous sclerosis complex and parental stress. Epilepsy Behav. 2008;13:505–10.
15. Webb DW, Clarke A, Fryer A, Osborne JP. The cutaneous features of tuberous sclerosis: a population study. Br J Dermatol. 1996;135:1–5.
16. Roach ES, DiMario FJ, Kandt RS, Northrup H, National Tuberous Sclerosis Association. Tuberous sclerosis consensus conference: recommendations for diagnostic evaluation. J Child Neurol. 1999;14:401–7.
17. Dabora SL, Jozwiak S, Franz DN, Roberts PS, Nieto A, Chung J, et al. Mutational analysis in a cohort of 224 tuberous sclerosis patients indicates increased severity of TSC2, compared with TSC1, disease in multiple organs. Am J Hum Genet. 2001;68:64–80.
18. Takanashi J, Sugita K, Fujii K, Niimi H. MR evaluation of tuberous sclerosis: increased sensitivity with fluid-attenuated inversion recovery and relation to severity of seizures and mental retardation. Am J Neuroradiol. 1995;16:1923–8.
19. First MB, Alan Pincus H. American Psychiatric Association: diagnostic and statistical manual of mental disorders. 4th ed. Washington, DC: American Psychiatric Association; 2000 (text revision).

20. Kwan P, Arzimanoglou A, Berg AT, Brodie MJ, Allen Hauser W, Mathern G, et al. Definition of drug resistant epilepsy: consensus proposal by the ad hoc Task Force of the ILAE Commission on Therapeutic Strategies. Epilepsia. 2010;51:1069–77.
21. Geraldini M, Liberalesso PBN, Zeigelboim BS, Spinosa MJ, Banzzatto AO, Farias AC, et al. Esclerose Tuberosa: análise de 24 casos pediátricos. RBM Espec Pediatr. 2012;69:15–20.
22. Verhoef S, Bakker L, Tempelaars AM, Hesseling-Janssen AL, Mazurczak T, Jozwiak S, et al. High rate of mosaicism in tuberous sclerosis complex. Am J Hum Genet. 1999;64:1632–7.
23. Chiron C, Dumas C, Jambaqué I, Mumford J, Dulac O. Randomized trial comparing vigabatrin and hydrocortisone in infantile spasms due to tuberous sclerosis. Epilepsy Res. 1997;26:389–95.
24. Van Eeghen AM, Terán LO, Johnson J, Pulsifer MB, Thiele EA, Caruso P. The neuroanatomical phenotype of tuberous sclerosis complex: focus on radial migration lines. Neuroradiology. 2013;55:1007–14.