

ical study. *Neurologia*. 2016. S0213-4853(16)30055-X [article in English, Spanish].

- Varni JW, Limbers CA, Burwinkle TM. Impaired health-related quality of life in children and adolescents with chronic conditions: a comparative analysis of 10 disease clusters and 33 disease categories/severities utilizing the PedsQL 4.0 Generic Core Scales. *Health Qual Life Outcomes*. 2007; 5:43.

María Vázquez López<sup>a,\*</sup>, Pedro Castro de Castro<sup>a</sup>,  
Nuria Gil Villanueva<sup>b</sup>, Andrés José Alcaraz Romero<sup>c</sup>,  
Samuel Ignacio Pascual Pascual<sup>d</sup>

<sup>a</sup> *Sección de Neuropediatría, Hospital Materno Infantil Gregorio Marañón, Madrid, Spain*

<sup>b</sup> *Sección de Cardiología Infantil, Hospital Materno Infantil Gregorio Marañón, Madrid, Spain*

<sup>c</sup> *Servicio de Pediatría, Hospital de Getafe, Getafe, Madrid, Spain*

<sup>d</sup> *Servicio de Neuropediatría, Hospital La Paz, Madrid, Spain*

\*Corresponding author.

E-mail address: [vazquezlopezmaria@gmail.com](mailto:vazquezlopezmaria@gmail.com)  
(M. Vázquez López).

31 January 2017 2 April 2017  
2341-2879/

© 2017 Asociación Española de Pediatría. Published by Elsevier España, S.L.U. All rights reserved.

## Jarcho-Levin and Rokitansky syndromes. An exceptional association<sup>☆</sup>



### Síndromes de Jarcho-Levin y Rokitansky. Una excepcional asociación

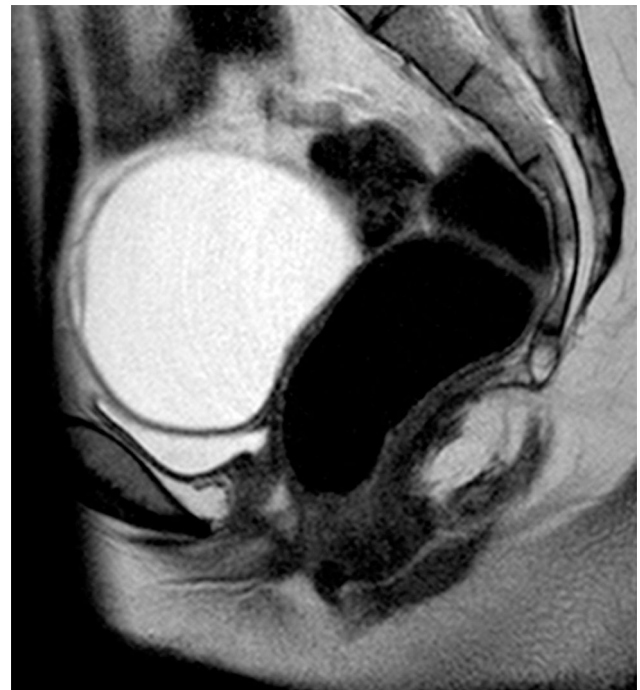Dear Editor:

Mayer-Rokitansky-Küster-Hauser (MRKH) syndrome is characterised by congenital aplasia of the uterus and the upper 2/3 of the vagina in women showing normal development of secondary sexual characteristics and a normal 46, XX karyotype.<sup>1</sup> Its estimated incidence is of 1 in 4000–5000 live female births.<sup>2</sup> Jarcho-Levin syndrome (JLS) or spondylocostal dysostosis is defined by the association of costal and vertebral malformations resulting in a shortened trunk and short stature.<sup>3</sup> It occurs in 1 out of 4000 live births.<sup>4</sup> Here, we present the case of a female patient with a neonatal diagnosis of JLS who sought care for primary amenorrhoea, the evaluation of which revealed Müllerian agenesis.

The patient was a girl aged 15 years with a diagnosis of primary amenorrhoea. The prenatal history was unremarkable. She received a diagnosis of JLS at birth based on the presence of a shortened trunk and thoracolumbar malformations. The patient also had a perimembranous ventricular septal defect, an ostium secundum atrial septal defect and a right inguinal hernia containing the right ovary.

At the time of assessment she had completed puberty (Tanner stage V) with normal female genitalia. We did not observe any signs of hyperandrogenism. A pelvic ultrasound scan, bone age study and measurement of hormone levels were requested for evaluation of the primary amenorrhoea. The ultrasound examination found no evidence of a uterus or ovaries. The bone age was consistent with

the chronological age. The levels of estradiol (92 ng/mL) and gonadotropins (luteinising hormone, 13.1 mIU/mL and follicle-stimulating hormone, 4.6 mIU/mL) were in the normal range. The patient underwent magnetic resonance imaging of the abdomen and pelvis (Fig. 1), which found that the uterus and the upper third of the vagina were absent. The ovaries were in the normal location, with detection of a cyst in the right one. The morphology and position of the kidneys were normal.



**Figure 1** Pelvic MRI. Sagittal T2-weighted image showing an ovarian cyst against the superior portion of the bladder, and the posterior wall of the bladder adjoining the anterior wall of the rectum due to the absence of the uterus and the upper third of the vagina.

<sup>☆</sup> Please cite this article as: Barriga Buján R, Muínelo Segade A, Prado-Carro A, González Herranz P, Soler Fernández R. Síndromes de Jarcho-Levin y Rokitansky. Una excepcional asociación. *An Pediatr (Barc)*. 2018;88:169–171.

These findings led to the diagnosis of MRKH syndrome, of which there are 2 types: type I (OMIM 277000), with isolated aplasia of the uterus and vagina, and type II (OMIM 601076), which, as occurred in the case presented here, is associated with other congenital anomalies, usually involving the kidneys, heart, skeleton, and hearing defects. At the skeletal level, the literature describes malformations of the spine (isolated, scoliosis, Klippel-Feil), ribs, palate or extremities.<sup>1</sup>

Since the involved organ systems have a common mesodermal origin and are closely related during embryogenesis, it has been proposed that the changes leading to MRKH syndrome occur in the very early stages of development. The presence of cases with different degrees of involvement in the same family has led to the investigation of candidate genes, such as those encoding anti-Müllerian hormone (AMH) and its receptor, *Wt1*, *PAX2*, *HOX* homeobox genes and *WNT*, but a causal relationship with the disorder has not been found. There are reports of cases of MRKH syndrome type II associated with hyperandrogenism in patients with mutations in the *WNT4* gene.<sup>1,5</sup> At the same time, JLS has been linked to mutations in gene *DLL3*, which is part of the Notch signalling pathway involved in embryogenesis.<sup>3</sup> The presence of different loci in these genes that could be related to both diseases suggests that in this case the aetiology was multifactorial, polygenic or involved defects in several common signalling pathways.

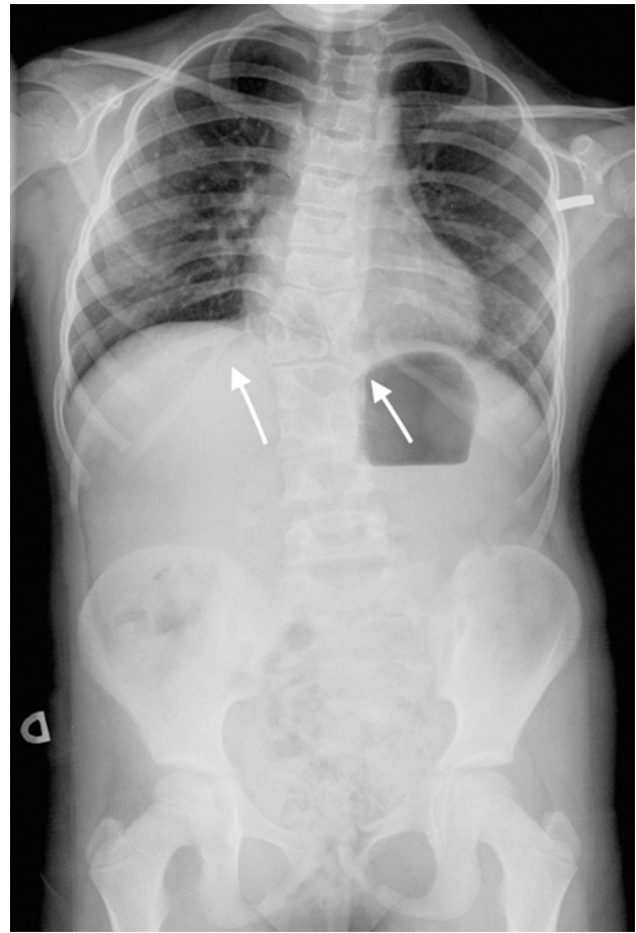
The initial diagnosis in our patient was JLS on account of the presence of shield chest, T12 butterfly vertebra, L1-L2-L3 fused vertebrae, and costal anomalies (fused right 11th and 12th ribs and absence of 1st right rib) (Fig. 2). Later on, she received the additional diagnosis of MRKH syndrome due to the absence of the uterus and upper portion of the vagina. At present, the patient has non-progressive scoliosis with 45° of curvature in the dorsal spine and a moderate restrictive ventilatory defect, and has no residual cardiac lesions. She remains in multidisciplinary followup.

Women with MRKH syndrome can only have children through adoption, surrogacy or uterus transplantation. A child was born alive for the first time after a uterus transplantation in 2014.<sup>6</sup> On the other hand, there is a growing interest in the use of bioengineering to treat female infertility through the potential development of replacement tissues and organs, which among other advantages would circumvent the need for immunosuppression.

Our aim in this article is to present the first case of an association between MRKH syndrome and JLS.

Although there are reports of vertebral and/or costal anomalies in association with MRKH syndrome, we did not find any cases associated with JLS or spondylocostal dysostosis in the reviewed literature. Similarly, the literature describes some cases of JLS associated with urogenital malformation, but none meeting the diagnostic criteria for MRKH syndrome.

In our patient, skeletal and cardiac malformations were detected early, but the diagnosis of MRKH syndrome was delayed, something that could be avoided by performing a complete screening for other anomalies.



**Figure 2** Plain radiograph of the anteroposterior spine, showing a shortened trunk, scoliosis, T12 butterfly vertebra, L1-L2-L3 fused vertebrae, and costal anomalies: fused right 11th and 12th ribs.

## References

- Morcel K, Camborieux L, Guerrier D. Mayer-Rokitansky-Küster-Hauser (MRKH) syndrome. *Orphanet J Rare Dis.* 2007;2:13.
- Varner RE, Younger JB, Blackwell RE. Müllerian dysgenesis. *J Reprod Med.* 1985;30:443-9.
- Berdon WE, Lampl BS, Cornier AS, Ramirez N, Turnpenny PD, Vitale MG, et al. Clinical and radiological distinction between spondylothoracic dysostosis (Lavy-Moseley syndrome) and spondylocostal dysostosis (Jarcho-Levin syndrome). *Pediatr Radiol.* 2011;41:384-8.
- Martinez-Frias ML, Bermejo E, Paisan L, Martin M, Egijbs J, Lopez JA, et al. Severe spondylocostal dysostosis associated with other congenital anomalies a clinical epidemiologic analysis and description of ten cases from the Spanish registry. *Am J Med Gen.* 1994;51:203-12.
- Sultan C, Biason-Lauber A, Philibert P. Mayer-Rokitansky-Kuster-Hauser syndrome: recent clinical and genetic findings. *Gynecol Endocrinol.* 2009;25:8-11.
- Brannstrom M, Johannesson L, Bokstrom H, Kvarnström N, Mölne J, Dahm-Kähler P, et al. Livebirth after uterus transplantation. *Lancet.* 2015;385:607-16.

Rebeca Barriga Buján<sup>a</sup>, Alba Muínelo Segade<sup>a</sup>, Ana Prado-Carro<sup>a,b,\*</sup>, Pedro González Herranz<sup>c</sup>, Rafaela Soler Fernández<sup>d</sup>

<sup>a</sup> Servicio de Pediatría, Complejo Hospitalario Universitario de A Coruña (CHUAC), SERGAS, A Coruña, Spain

<sup>b</sup> Unidad de Endocrinología Pediátrica, Complejo Hospitalario Universitario de A Coruña (CHUAC), SERGAS, A Coruña, Spain

<sup>c</sup> Servicio de Traumatología y Ortopedia Infantil, Complejo Hospitalario Universitario de A Coruña (CHUAC), SERGAS, A Coruña, Spain

<sup>d</sup> Servicio de Radiología, Complejo Hospitalario Universitario de A Coruña (CHUAC), SERGAS, A Coruña, Spain

\* Corresponding author.

E-mail address: [ana.maria.prado.carro@sergas.es](mailto:ana.maria.prado.carro@sergas.es) (A. Prado-Carro).

2341-2879/

© 2017 Asociación Española de Pediatría. Published by Elsevier España, S.L.U. All rights reserved.

## Implication of a national outbreak of *Serratia marcescens* associated with a contaminated solution of chlorhexidine in a paediatric hospital<sup>☆</sup>



## Implicación de un brote nacional de infección por *Serratia marcescens* asociado a clorhexidina contaminada en un hospital pediátrico

Dear Editor:

Due to its ubiquity and its ability to survive in humid environments and to colonise the gastrointestinal and/or respiratory tracts, *Serratia marcescens* is responsible for multiple nosocomial outbreaks,<sup>1</sup> especially in paediatric patients and specifically in newborns, who suffer the direst consequences.<sup>2,3</sup> In some instances, it is possible to identify the source of infection, which is of particular relevance in outbreaks involving antiseptic solutions on account of their impact.<sup>3</sup> In this letter, we describe our experience in a children's hospital in the context of a nationwide *S. marcescens* outbreak associated with the use of contaminated chlorhexidine (CHX) antiseptic solution<sup>4</sup> that occurred between August 2014 and January 2015 and comprised 148 cases (86 confirmed) in 10 Autonomous regions. Although most of the affected patients were aged more than 65 years, 8 children were affected in our hospital, between November 22 and December 16, 2014. All developed bacteraemia and had favourable outcomes, except 1 infant who died within 24 h from diagnosis (mortality of 12.5%).

Initially, when we were still unaware of the national scope of the outbreak, we hypothesised that there must be a common source/reservoir of *S. marcescens*, a fluid medium somewhere in the surgical suite of the hospital, where the

first 5 affected patients had been treated. Since culture of the CHX-based antiseptic solutions in the surgical suite was negative and *S. marcescens* was isolated from a bag of packed red blood cells in a patient that had received a transfusion in the paediatric ICU and not undergone surgery, we considered transfusion another potential route of infection, as all the affected patients had received transfusions prior to the diagnosis of bacteraemia.

With the investigation underway, when 7 of the 8 cases had been detected, the Spanish Agency of Medicines and Medical Devices issued a recall of skin antiseptic based on CHX in aqueous or alcohol solution that had been distributed in 2014 (lots 1-15, 1-11, 1-28, 1-29, 1-30, 1-33 and 1-35), while the Epidemiological Surveillance System of Andalusia (SVEA) of Andalusia warned us that the use of this antiseptic was probably the cause of the outbreak at our hospital. Having received this warning, we verified that the units affected by the outbreak had been using products from several of the lots included in the recall. Unlike other published studies regarding this outbreak,<sup>5</sup> we performed pulsed-field gel electrophoresis for the molecular analysis of isolates from patient samples, those obtained from new samples of CHX solutions removed from use in the hospital (lots 1-33 and 1-35) and the strain provided by the laboratories that distributed the contaminated antiseptic, and found that all isolates were from a single clone (Fig. 1).

The procedures that most likely contributed to the transmission of infection were those whose performance was preceded by the use of this antiseptic, such as disinfection of the skin prior to surgery or catheterisation, and disinfection of 3-way stopcocks before transfusion. This was consistent with the information received in the outbreak report, where the medical procedure associated with the use of the CHX solution was catheterisation in 70% of cases.<sup>4</sup>

The rapid identification and notification of the outbreak, the implementation of preventive measures and molecular testing allowed the control of an outbreak affecting the paediatric age group, a particularly vulnerable population. We ought to highlight that our study evinced the clonal relationship of all isolates from the outbreak with the original contaminant strain, and that cases were restricted to the paediatric population, including one death that could be attributed to infection by *S. marcescens* out of the 148 patients affected nationwide. It is essential that we improve the communication between Public Health Agencies and health care facilities, as the problem started in 2014 and the outbreak persisted through December of the same year.<sup>4</sup>

<sup>☆</sup> Please cite this article as: Morillo Á, Torres MJ, Alonso Salas MT, Conde M, Aznar J. Implicación de un brote nacional de infección por *Serratia marcescens* asociado a clorhexidina contaminada en un hospital pediátrico. An Pediatr (Barc). 2018;88:171–172.